

Full Length Research Paper

# Acute and chronic toxicity of pawpaw (*Carica papaya*) seed powder to adult Nile tilapia (*Oreochromis niloticus* Linne 1757)

Ezekiel O. Ayotunde\* and Benedict O. Ofem

Department of Fisheries, Faculty of Agriculture, Cross River University of Technology, P.M.B. 102, Obubra Campus, Calabar, Nigeria.

Accepted 25 February, 2008

This experiment determined the toxicity of pawpaw seed powder to adult tilapia, *Oreochromis niloticus*, the most cultivable fish species in Africa. The 96 h static bioassay experiment was conducted to determine the median lethal concentration (LC<sub>50</sub>) for adult Nile tilapia, to pawpaw seed, *Carica papaya*. Two hundred live, and apparently healthy *O. niloticus* measuring 11.5 - 14.6 cm total length and 65.6 - 112.4 g were used for the experiment. Eighteen (75 x 45 x 45 cm) glass tanks of 121.5 litres capacity each were filled with 50 litres aerated unchlorinated well water. The toxicant was introduced at different concentrations in triplicate per treatment. The 96-h LC<sub>50</sub> of pawpaw seed powder to adult tilapia is 4.2 mg/l with 95% confidence limit of 31.86 – 93.81 mg/l and the maximum admissible toxicant concentrations ranges between 0.042 - 0.42 mg/l, while the total mortality occurred in the concentration of 8 mg/l within 24 h exposure period. Toxic reaction exhibited by the fish includes erratic movement, air gulping, loss of reflex, discolouration, molting, loss of scale, and haemorrhage. The pathologic lesion of gill, skin, liver and kidney includes different level of degeneration of cells, lamellar hyperemia, hypertrophy of gill arch, shrinkages and dermal erosion and necrosis of skin, while hyperplasia, disarrangement of hepatic cell, necrosis and vacuolation occurred in liver and kidney of adult tilapia *O. niloticus*. Damages became severe with increasing concentration of *C. papaya* to fish and time of exposure. There was no significant changes in the water quality during the experiment; the result obtained before the test, during the test and after the test were found close to the water quality parameters of the control. Results of the tests provided baseline information and established safe limits of using *C. Papaya* seed powder as an antifertility agent in controlling excessive breeding of tilapia in fish farm.

**Key words:** Toxicity, pawpaw seed, tilapia (*Oreochromis niloticus*) adults, tolerance limit, histology, haematology.

## INTRODUCTION

The St. Peter's fish (Nile tilapia), *Oreochromis niloticus*, possesses characteristics such as, fast growth, and tolerance of poor water quality. It is common food fish in Nigeria and has been introduced to many countries around the World. Tilapia culture is however fraught with the problems of prolific breeding and overpopulating any water they found themselves that results into stunted gro-

wth of tilapia. Tilapia sexually matures at about 20 g weights (Mair and Little, 1991). Uncontrolled reproduction of *O. niloticus* in pond in Nigeria especially in Cross River State, as observed and complained by farmers, leads to harvest of stunted fish with low nutritional and commercial values. For profitable tilapia culture, the prolific breeding and stunting problem associated with it have to be solved. Mair and Little (1991) enumerated various methods and technique available for the control of prolific breeding in tilapia and observed that each of them has its own shortcoming. As the search for a better solution to this problem continues, medicinal plants like pawpaw

\*Corresponding author. E-mail: eoayotunde@yahoo.co.uk. Tel: 08059791815.

(*C. papaya*) have successfully been used to induce sterility in laboratory animal (Gary and Garg, 1971; Bodharkar 1974; Das 1980; Udo and Kehinde 1999; Ismail, 2004).

Papaya (*C. papaya*) is a common man's fruit; available throughout the year in the tropic. It is referred to as the "medicine tree" or "melon of health". Papaya is filled with nutrients (Jackwheeler, 2003). It contains medicinal properties and the major active ingredients recorded include, carpine, chymopapain and papain, a bactericidal aglycone of glucotropaeolin, benzyl isothiocyanate, a glycoside sinigrin, the enzyme myrosin, and carpasemine (Akah et al., 1997; Jackwheeler 2003; Eno et al., 2000, Wilson et al., 2002; Seigler et al., 2002).

Papaya contains antifertility properties, particularly the seeds, (Lohiya et al., 1999). A complete loss of fertility has been reported in male rabbits, rats and monkeys fed an extract of papaya seeds (Glazer and Smith 1971; Lohiya et al., 1999; Pathak et al., 2000). Lohiya et al. (2002) suggested that ingestion of papaya seeds may adversely affect the fertility of human males or other male mammals. Ekanem and Okoronkwo (2003) reported high success in using pawpaw seed powder in inducing sterility in male tilapia when administered through feed.

Despite their widespread use, their toxicity and effectiveness of *C. papaya* to aquatic organisms, particularly fishes, have not been examined. Acute and chronic toxicity test was conducted using aqueous extract of pawpaw seeds on adult tilapia. Results expected from the toxicity test will provide baseline information and establish limit of using aqueous extract of pawpaw seeds as an antifertility agent in controlling the prolific breeding of tilapia in freshwater fishpond.

The effect of pawpaw seed on the target organ of the fish would also be determined as persistent usage of the chemical could build up in the organs of the fish, and the surrounding environment of the fish and this may be deleterious. This work determined the normal dosage of pawpaw seed powder to adult tilapia and its effect on water quality, through the determination of toxicity and tolerance level.

## MATERIALS AND METHODS

Two hundred live and apparently healthy adult tilapia measuring 11.5 - 14.6 cm total length and 65.6 - 112.4 g weight were identified using taxonomic key of Reed et al. (1967). The specimen used for the experiment was collected from Cross River University of Technology fish farm at Calabar, Obubra Campus. The specimen was acclimated for 1 week in the laboratory inside transparent, rectangular glass tanks (75 x 45 x 45 cm) of 121.5 L capacity. The tanks were filled with 50 L unchlorinated well water. The fish was fed to apparent satiation twice daily (0900 and 1600 h) with a commercial pelleted fish diet containing 35% crude protein during the acclimation period. Feeding was discontinued 48 h before the commencement of the experiment to minimize the production of wastes in the test container. The maximum admissible toxicant concentration established for adult tilapia was derived by multiplying a constant 0.01 - 0.1 by 96 h LC<sub>50</sub> (Koesomadinata, 2000).

## Preparation of aqueous extract of pawpaw (*C. papaya*) seed powder and acclimation of test fish

Large quantities of ripe pawpaw fruits were purchased from the farmers around Obubra village, in Cross River State, Nigeria. The seed powder was prepared by opening the mature fruit of pawpaw and the fresh seeds extracted and were sun dried. The seeds were ground to a fine powder, using the coffee mill attachment of a Moulinex domestic food blender. The powder was kept in desiccator for later use in stock solutions. A preliminary range finding test was conducted to determine the toxicity level of pawpaw seed powder using standard method (American Public Health Association APHA, 1987).

## Acute toxicity test

The preliminary range finding test was conducted to determine the actual concentration for the test. One control and five tests in triplicates were set up for the experiment. Pawpaw seed powder was introduced randomly, and tested for 24 h, the behavior and mortality of the test fishes in each tank was monitored and recorded every 15 min for the first hour, once every hour for the next 3 h and every 4 h for the rest 24 h period. Eighteen (75 x 45 x 45 cm) glass tanks of 121.5 L capacity each were filled with 50 L aerated dechlorinated well water. Adult *O. niloticus* was batch-weighed with a top-loading mettlar balance (Mettler Toledo (K)), and distributed randomly in triplicate per treatment. The glass tanks were covered with mosquito net to prevent fish from jumping out; there was no aeration, no water change nor feeding throughout the test. This was done prior to the introduction of the toxicant. The toxicant was introduced at 2, 4, 6, 8 and 10 mg/l with a control of 0 mg/l in triplicate. The test lasted for 24 h.

The definitive test was conducted using concentration of 4.0, 4.2, 4.4, 4.6, 4.8 and 5.0 mg/l of pawpaw seed powder earlier determined for the range finding test. This test comprised one sublethal toxicity test according to the standard method/procedures (American Public Health Association, 1987). Fish mortality was monitored and recorded hourly for the first 4 h, 4 h for the next 24 h, and subsequently every 24 h, for the next 96 h. The inability of fish to respond to external stimuli was used as an index of death. Apart from monitoring and recording fish mortality the fish behaviour such as erratic swimming, air gulping, loss of reflex, discolouration, and molting was monitored. LC<sub>50</sub>, which is the concentration of pawpaw seed powder, estimated to be lethal to 50% of test organism after exposure time of 96 h, was determined graphically using probit transformation (Herwig, 1979; USEPA, 2000).

## Haematological and histological examination of fish

Haematological examination of fish followed the method described by Svobodova et al. (1991). One fish per tank was removed after 96 h of exposure for histological examination. The fish was dissected to remove the gill, liver, skin and kidney. The organ tissues were fixed in 10% formalin for three days after which the tissue was dehydrated in periodic acid Schiff's reagent following the method of Hughes and Perry (1976), in graded levels of alcohol for three days, to allow paraffin wax to penetrate the tissue during embedding. The organs were then embedded in malted wax. The tissue was sectioned into 5 - 7 µm sections using a rotatory microtome and were dehydrated and stained with HE stain (Bancroft and Cook, 1994), using a microtome and each section was cleared by placing in warm water (38°C) and oven-dried at 58°C for 30 min to melt the wax. The slide containing sectioned tissue was cleared using xylene and graded levels of alcohol for two minutes each. The section was stained in HE stain for 10 min. The stained slide was observed under a light microscope at varying magnifications; sections were

**Table 1.** Percentage cumulative mortality of *C. papaya* to tilapia adults (Rrange finding test).

S/N	Conc. (mg/l)	15 min	30 min	45 min	60 min	2 h	3 h	4 h	8 h	12 h	16 h	20 h	24 h
1	0	0	0	0	0	0	0	0	0	0	0	0	0
2	2	0	7	7	10	20	23	23	30	30	33	33	50
3	4	0	0	3	10	20	23	27	27	30	40	47	53
4	6	0	3	7	23	23	33	40	40	43	47	60	73
5	8	0	0	17	27	37	43	53	63	57	73	86	90
6	10	0	7	10	30	30	53	57	70	70	63	100	100

**Table 2.** Percentage cumulative mortality of *C. papaya* to Tilapia *O. niloticus* adults (Definitive test).

S/N	Conc. (mg/l)	1 h	2 h	3 h	4 h	8 h	12 h	16 h	20 h	24 h	48 h	72 h	96 h
1	4.0	0	0	0	0	10	17	17	20	20	23	23	27
2	4.2	0	0	0	7	10	17	23	37	37	37	37	43
3	4.4	0	0	3	10	10	13	23	23	37	37	53	53
4	4.6	0	0	0	7	17	17	23	37	47	57	57	57
5	4.8	0	0	3	7	10	20	33	37	46	57	63	97
6	5.0	0	0	13	23	40	46	60	67	73	80	93	100

**Table 3.** The LC<sub>50</sub> value for adult tilapia.

Time (h)	LC <sub>50</sub> (mg/l)
24	4.7
48	4.6
72	4.3
96	4.2

examined and photographed using an Olympus BH2 microscope fitted with a camera and automatic light exposure unit. Photography, development and printing of negative was done as described by (Veile, 1990)

#### Water quality analysis

Water quality monitoring was done prior to the experiment, during the experiment and after the experiment. pH was determined using a digital pH meter (Mettler Toledo 320). The electrode was inserted into the bottle containing the water sample after standardization in different buffer, after which the reading was taken. DO<sub>2</sub> was measured using a digital, dissolved oxygen meter (Jenway, 9071) once in a day at 8.00 a.m. While, temperature was measured using a mercury in-glass thermometer, which was placed in the medium inside the test container until reading was taken. The reading was taken at 10.00 a.m. on each day of the experiment.

#### Statistical analysis

All results were collated and analysed using computerized, probit and logit analysis (Lichfiel and Wilcoxon, 1949). The median lethal concentration LC<sub>50</sub> at selected period of exposure, and an associated 95% confidence interval for each replicate toxicity test was subjected to logit and probit analysis (Finney, 1971) using

Statistical Package for Social Sciences (SPSS) 11.0 for Windows XP.

## RESULTS AND DISCUSSION

Tables 1 and 2 show the percentage cumulative mortality of toxicity of pawpaw seed powder to adult tilapia. The 96 h LC<sub>50</sub> of an aqueous extracts of pawpaw seed powder to adult *O. niloticus* is presented in Table 3 and Figures 1 - 4. This value is the concentration of the treatments required to be lethal to 50% of adult *O. niloticus* within 96 h period. The acute toxicity of aqueous extract of pawpaw seed to adult tilapia increased with increased concentration of the toxicant and time of exposure. Total mortality resulted at concentration of 10 mg/l and the maximum admissible toxicant concentration of 0.042 - 0.42 mg/l with 95% confidence limit of 31.86 – 93.81 mg/l.

Table 4 shows the results of the water quality parameters of on adult tilapia. The pH, temperature, and dissolved oxygen concentration were determined at different time interval. The result obtained for the 96 h were found closed to the water quality parameter of the control. The fish were observed swimming erratically, they exhibited loss of reflex, molting, discoloration, air gulping, loss of scale (Tables 5 and 6.). Increase loss of scale and haemorrhage were observed to be directly proportional to increase in pawpaw concentration level and duration of exposure. This result is similar to our previous work (Ayotunde and Ofem, 2005) where the 96 h LC<sub>50</sub> of pawpaw seed powder to fingerlings of tilapia is 1.8 mg/l and the maximum admissible toxicant concentrations ranges between 0.018 - 0.81 mg/l, while the total mor-

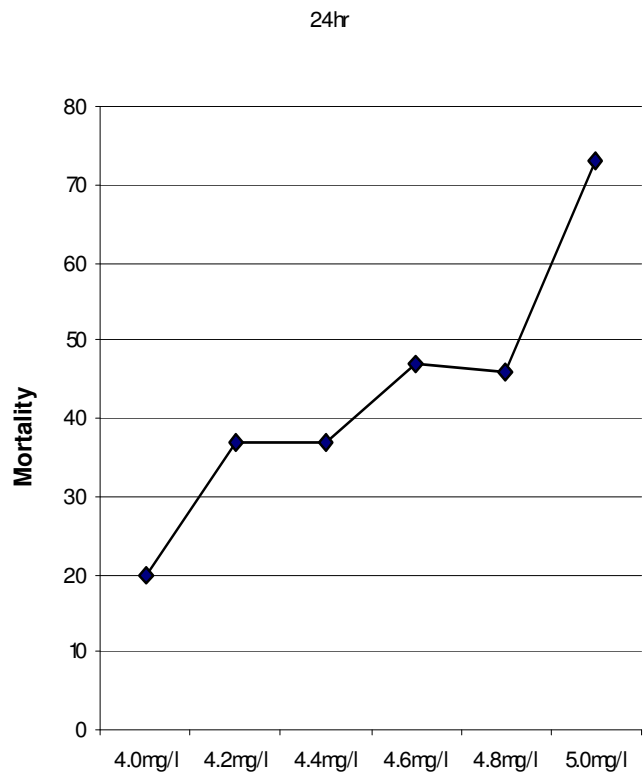


Figure 1. Determination of LC<sub>50</sub> for adult tilapia (*O. niloticus*).

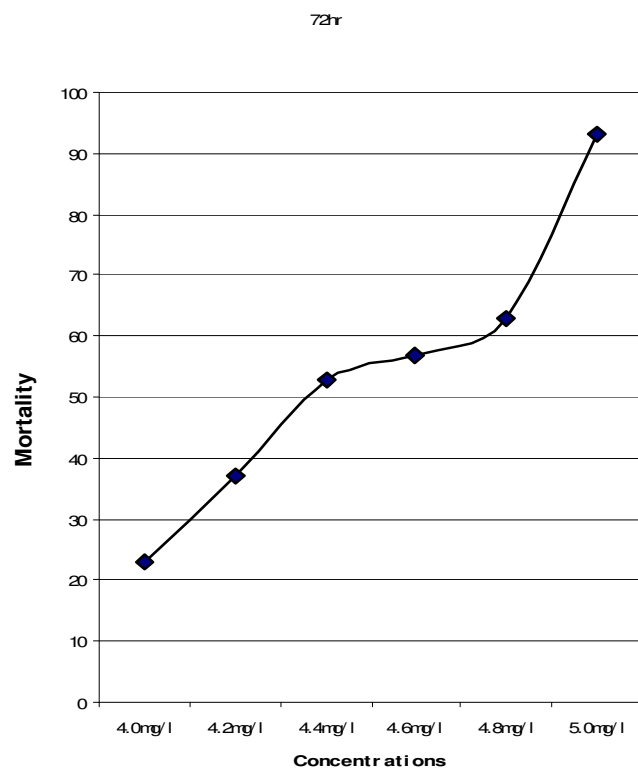


Figure 3. Determination of LC<sub>50</sub> for adult tilapia (*O. niloticus*).

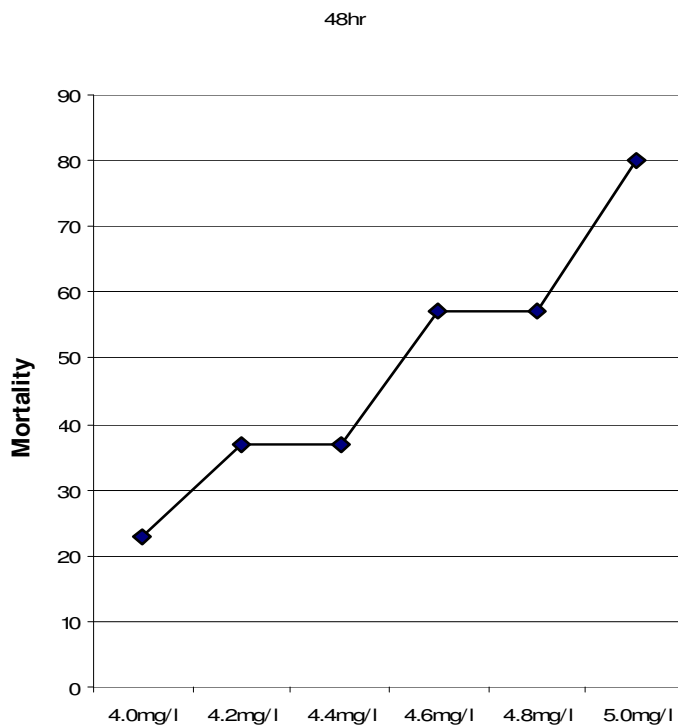


Figure 2. Determination of LC<sub>50</sub> for adult tilapia (*O. niloticus*).

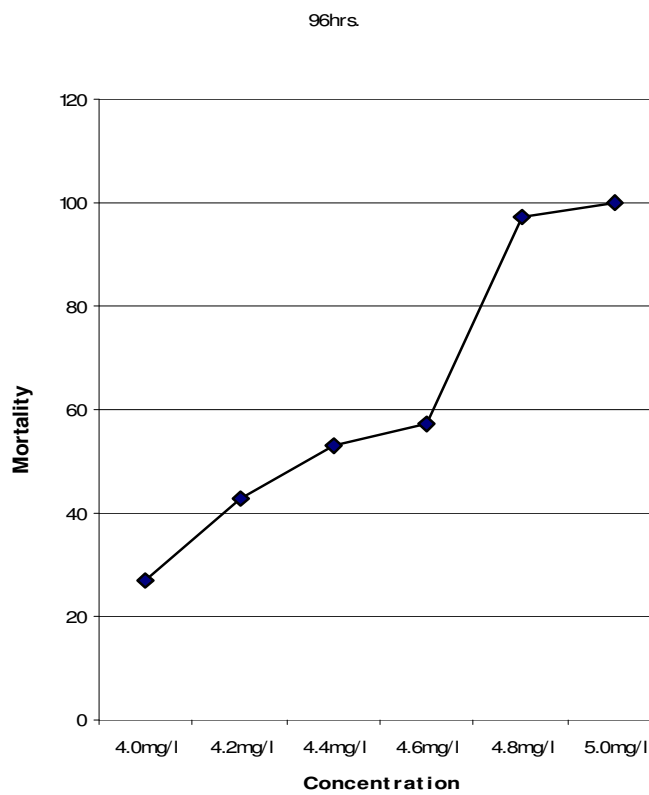


Figure 4. Determination of LC<sub>50</sub> for adult tilapia (*O. niloticus*).

**Table 4.** The summary results of physico-chemical parameter during the test.

Parameter	Range finding test			Definitive test		
	Before test	During test	After test	Before test	During test	After test
Temp. (°C)	26.5	27	27	26.2	26.5	27.2
DO <sup>2</sup> (mg/l)	5.6	5.8	5.5	6.2	5.8	6.2
pH	7.2	6.9	6.8	6.8	7.1	7.5

**Table 5.** Behavioral monitoring for adult tilapia (Range finding test).

Behavior	12 h Exposure						16 h Exposure						20 h Exposure						24 h Exposure					
	0	2	4	6	8	10	0	2	4	6	8	10	0	2	4	6	8	10	0	2	4	6	8	10
Loss of reflex	-	-	-	-	+	+	-	-	-	-	+	+	-	-	-	-	+	+	-	-	-	-	+	+
Molting	-	-	-	-	+	+	-	-	-	-	+	+	-	-	-	-	+	+	-	-	-	-	+	+
Discoloration	-	-	-	-	+	+	-	-	-	-	+	-	-	-	-	-	+	-	-	-	-	-	-	-
Air gulping	-	+	+	+	+	+	-	+	+	+	+	+	-	+	+	+	+	-	-	+	+	+	+	-
Erratic swimming	-	-	-	-	+	+	-	-	-	-	+	+	-	-	-	-	+	+	-	-	-	-	+	+
Loss of scale	-	-	-	-	-	-	-	-	-	-	-	-	-	-	-	-	-	-	-	-	-	-	-	+
Haemorrhage	-	-	-	-	-	-	-	-	-	-	-	-	-	-	-	-	-	-	-	-	-	-	-	+

- = not present; + = present.

tality occurred at concentration of 8 mg/l within 24 h exposure period.

Annune et al., (2002), reported lower concentration of Ringworm plant *Senna alata*, used in poisoning water bodies for fish capture in Benue State of Nigeria. The 96 h LC<sub>50</sub> value for juvenile tilapia *O. niloticus* was 13.93 mg/l, indicating that the extract causes subacute effect. The toxicity of *C. papaya* to *O. niloticus* was higher than the result of Wade et al. (2002) who reported 96 h LC<sub>50</sub> of 0.19 mg/l for the *O. niloticus* exposed to cassava (*Manihot esculenta*) toxic extracts. Santhakumar and Balaji (2000) determined the acute toxicity of an organo-phosphorus insecticide monocrotophos to the fresh water fish, *Anabas testudineus*. The 24, 48, 72, and 96 h LC<sub>50</sub> were found to be 22.65, 21.2, 9.75, and 19 ppm respectively. The safe concentration of monocrotophos was 0.19 ppm. Muniyan and Veeraraghavan (1999) reported the effect of insecticide, ethofenprox to *Oreochromis mossambicus*, using a static bioassay method; the median lethal concentration for 3, 6, 12, 24, 48, and 96 h were 2.03, 1.95, 1.90, 1.85, 1.79, 1.76, and 1.74 ppm, respectively. It was observed that adults of tilapia showed variations in their tolerance to aqueous extracts of *C. papaya* (Tables 5 and 6), upon addition of the toxicant. The fish showed various toxic reactions such as erratic movements, air gulping, molting, while increase in concentration and exposure time resulted in loss of scale and haemorrhage. This report agrees with the work of many authors (Muniyan and Veeraraghavan, 1999; Santhakumar and Balaji, 2000; Ayuba and Ofojekwu, 2002; Chung-Min Liao et al., 2003).

There is significant difference in the value of blood parameters of adult *O. niloticus* after exposure to 96 h

aqueous extract to *C. papaya* seed powder (Table 7). The result of haematological parameters of adult tilapia showed significant difference ( $P < 0.05$ ) in higher concentrations. The pack cell volume increased from  $13.6 \pm 1.2\%$  in the control to  $6.58.0 \pm 3.4\%$  in concentration of 5.0 mg *C. papaya* per litre of water. Erythrocyte sedimentation rate increases from  $9.33 \pm 0.5\%$  in control to  $14.5 \pm 1.6\%$  in higher concentration of 5 mg *C. papaya* per litre of water. White blood cell and mean cell heamoglobin increase from  $3.3 \pm 0.3 \times 10^4 \text{mm}^3$  and  $3.3 \pm 0.3$  to  $5.4 \pm 0.2$  and  $4.8 \pm 0.9$  in higher concentration of 5.0 mg *C. papaya* per litre of water, respectively.

While there is a decrease in heamoglobin concentration and mean cell volume from  $4.6 \pm 0.4 \text{g/dl}$  and  $98856.2 \pm 10098 \mu^3$  in control to  $2.02 \pm 0.4$  and  $14365 \pm 268.14$  in higher concentration of 5 mg *C. papaya* per litre of water, respectively. There is no significant difference in change in mean cell haemoglobin.

The results presented in Tables 8 - 11 and Figures 5 - 16 represent the histopathological changes observed in adult tilapia exposed to aqueous extract of *C. papaya* seeds treated with 4.8, 5.0 and 0 mg/l as control. Histopathological changes in the gill, skin, liver, and kidney were observed for all the treatments. Lesions were essentially similar for all treatments and exposure time, although the intensity of cell damage increased with increasing concentration and time of exposure.

#### Gill of adult tilapia exposed to aqueous extracts of *C. papaya*

The normal histology of the gill structure of adult tilapia

**Table 6.** Behavioral monitoring for adult tilapia (definitive test).

Behavior/Exposure Time	24 h					48 h					72 h					96 h				
	4.0	4.2	4.6	4.8	5.0	4.0	4.2	4.6	4.8	5.0	4.0	4.2	4.6	4.8	5.0	4.0	4.2	4.6	4.8	5.0
Loss of reflex	-	-	+	-	-	-	-	-	-	-	-	-	-	-	-	-	-	-	-	-
Molting	-	-	-	+	+	-	-	+	-	-	-	-	+	-	-	-	-	-	-	-
Discoloration	-	-	+	+	+	+	+	+	+	+	+	+	+	+	+	+	+	+	+	+
Air gulping	+	+	+	+	+	+	+	+	+	+	+	+	+	+	+	+	+	+	+	+
Erratic swimming	-	-	+	+	+	-	-	-	+	-	-	+	+	+	-	-	-	+	+	-
Loss of scale	-	-	-	-	-	-	-	-	-	-	-	-	-	-	+	-	-	-	+	+
Haemorrhage	-	-	-	-	-	-	-	-	-	-	-	-	-	-	-	-	-	-	+	+

- = not present; + = present.

**Table 7.** The Summary of effect of *C. papaya* on haematological parameters of adult tilapia.

Conc. (mg/l)	PCV (%)	Hb (g/dl)	ESR (%)	WBC $10^4\text{mm}^3$	RBC $10^6\text{mm}^3$	MCH (pg)	MCHC (T/L)	MCV ( $\mu^3$ )
T <sub>0</sub> (0)	13.6±1.2	4.6±0.44	9.33±0.6	3.3±1.3	1.4±0.3	3.3±0.3	336.4±5.0	98856.2±1009.8
T <sub>1</sub> (4.0)	7.67±3.8	2.63±1.3	12.7±2.3	4.2±1.4	0.6±0.4	4.3±0.6	343.9±5.4	12398.3±1723.2
T <sub>2</sub> (4.2)	15±4.36	5.17±1.3	10±2.65	2.8±1.0	9.3±0.3	4.2±0.5	348.1±2.1	34310.6±4674.3
T <sub>3</sub> (4.4)	12.7±0.6	4.23±0.2	10.7±0.6	2.7±0.5	1.2±0.2	2.6±0.3	334.2±4.0	10342.7±916.17
T <sub>4</sub> (4.6)	13.3±4.0	4.49±1.3	10.7±2.1	3.6±1.0	1.3±0.5	3.5±0.3	330.3±3.6	10065.8±1152.7
T <sub>5</sub> (4.8)	6.33±1.5	2.13±0.5	14±1.0	5.0±0.3	0.5±0.2	3.4±0.5	336.5±7.6	10536.5±846.18
T <sub>6</sub> (5.0)	6.58±3.4	2.02±0.4	14.5±1.6	5.4±0.2	0.3±0.2	4.8±0.9	336.9±3.4	14365.08±268.14

**Table 8.** Histological changes in gill of *O. niloticus* adult exposed to aqueous extract of *C. papaya* seeds papaya.

Concentration (mg/l)	Figures 5 - 7	Histological changes
0	5	No pathological lesion was observed.
4.8	6	Vacuolation of the gill arches and total removal of lamellae.
50	7	Complete degeneration of filaments of the gill arches.

exposed to 0 mg/l of *C. papaya* is shown in Figures 5 - 7. Following the exposure to aqueous extract of *C. papaya* half of the gill arch have its filament and lamellae degenerated in fish treated

with concentration of 4.8 mg/l (Figure 6). Complete degenerated filaments and gill arch were recorded in highest concentration of 5.0 mg/l within 96 h exposure period (Figure 7). In Figure

5, no pathological lesion was observed. Vacuolation of the gill arches and total removal of lamellae is observed in Figure 6. While complete degeneration of filaments of the gill arches is seen in Figure 7.

**Table 9.** Histological changes in skin of *O. niloticus* adults exposed to aqueous extract of *C. papaya* seeds papaya.

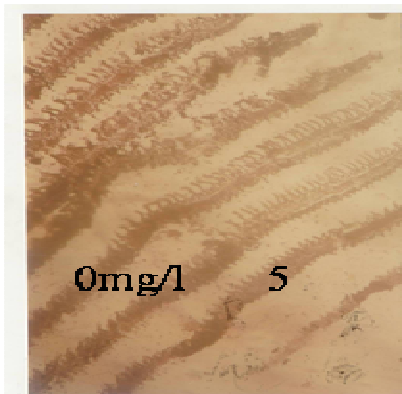
Concentration (mg/l)	Figures 8 - 10	Histological changes
0	8	No pathological lesion was observed.
4.8	9	Hyperplasia and disorientation of hepatic cells.
5.0	10	Vacuole formation, shrinkage of cells.

**Table 10.** Histological changes in liver of *O. niloticus* adults exposed to aqueous extract of *C. papaya* seeds papaya.

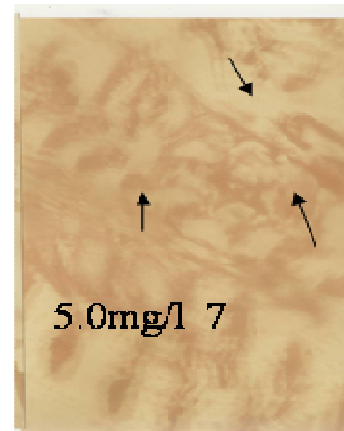
Concentration (mg/l)	Figures 11 - 13	Histological changes
0	11	No pathological lesion was observed.
4.8	12	Hyperplasia and disorientation of hepatic cells.
5.0	13	Vacuole formation, shrinkage of cells.

**Table 11.** Histological changes in kidney of *O. niloticus* adults exposed to aqueous extract of *C. papaya* seeds papaya.


Concentration (mg/l)	Figures 14-16	Histological changes
0	14	No pathological lesion was observed.
4.8	15	Karyolysis of the hepatocytes.
5.0	16	Complete degeneration of cells.



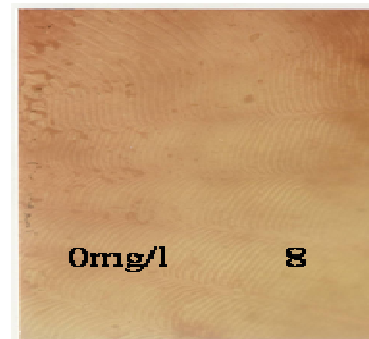
**Figure 5.** Histological change observed in the gill of adult *O. niloticus* treated with 0 mg/l *C. papaya* seed powder: No pathological lesion was observed.



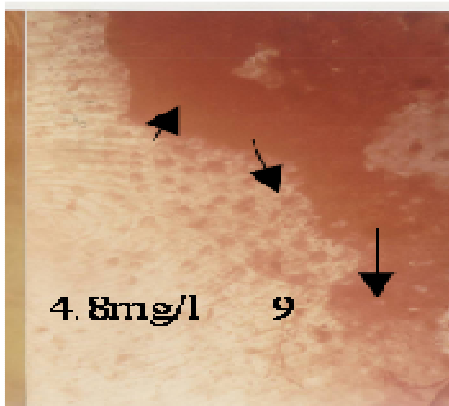
**Figure 7.** Histological change observed in the gill of adult *O. niloticus* treated with 5.0 mg/l of *C. papaya* seed powder: Complete degeneration of filaments of the gill arches.



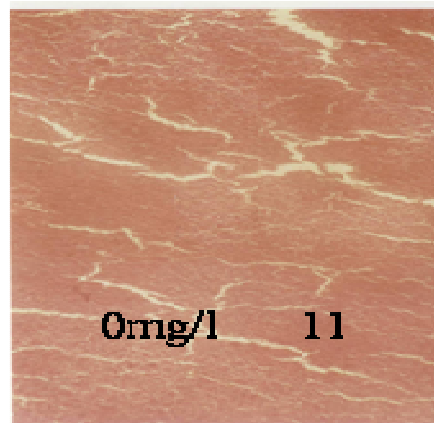
**Figure 6.** Histological change observed in the gill of adult *O. niloticus* treated with 4.8 mg/l of *C. papaya* seed powder: Vacuolation of the gill arches and total removal of lamellae.



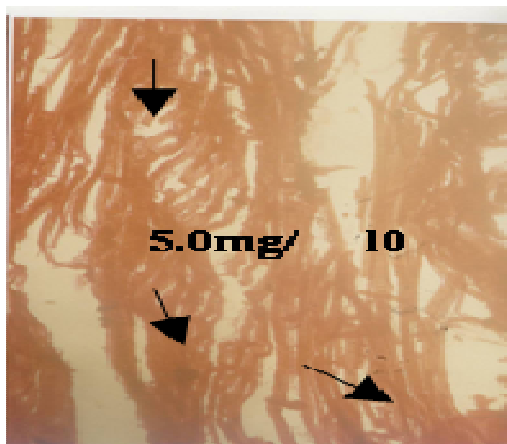
**Figure 8.** Histological change observed in the skin of adult *O. niloticus* treated with 0 mg/l of *C. papaya* seed powder: No pathological lesion was observed.



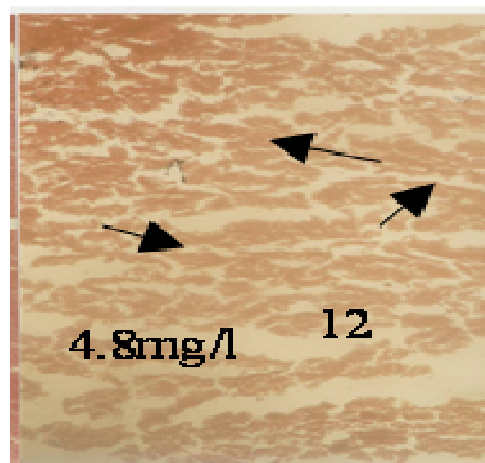
**Figure 9.** Histological change observed in the skin of adult *O. niloticus* treated with 4.8 mg/l of *C. papaya* seed powder: Hyperplasia and disorientation of hepatic cells.



**Figure 11.** Histological change observed in the liver of adult *O. niloticus* treated with 0 mg/l of *C. papaya* seed powder: No pathological lesion was observed.



**Figure 10.** Histological change observed in the skin of adult *O. niloticus* treated with 5.0 mg/l of *C. papaya* seed powder: Vacuole formation, shrinkage of cells.



**Figure 12.** Histological change observed in the liver of adult *O. niloticus* treated with 4.8 mg/l of *C. papaya* seed powder: Hyperplasia and disorientation of hepatic cells.

#### **Skin of adult tilapia exposed to aqueous extracts of *C. papaya***

Figure 8 - 10 show the pathological changes observed in skin of adult tilapia *O. niloticus*. Figure 8 shows normal skin no pathological lesion observed in concentrations of 0 mg/l of *C. papaya* treated fish. Necrosis and erosion of dermal cell of the skin (Figure 9) was observed in concentration of 4.8 mg/l of *C. papaya* treated fish. While Figure 10 shows complete degeneration of cell in highest concentration of 5.0 mg/l of *C. papaya* treated fish.

#### **Liver of adult tilapia exposed to aqueous extracts of *C. papaya***

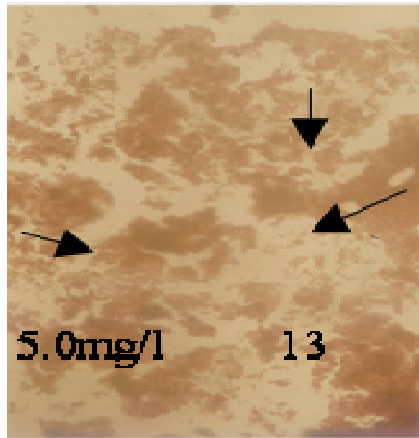
Figure 11 shows the normal liver cell no pathological lesion observed in the control fish. There was disarran-

gement of hepatic cell in Figure 12 exposed to concentration of 4.8 mg/l of *C. papaya* treated fish. Figure 13 shows the necrosis and faded hepatic cell in the liver of adult tilapia exposed to the highest concentration of 5.0 mg/l of *C. papaya*.


#### **Kidney of adult tilapia exposed to aqueous extracts of *C. papaya***

The normal histology of the kidney structure of adult tilapia *O. niloticus* exposed to 0 mg/l, of *C. papaya* is presented in Table 14. Figure 15 show the shrinkages of cell in concentration 4.8 mg/l of *C. papaya* treated fish. While complete degeneration of cell and tissue (Figure 16) was observed in highest concentration of 5.0 mg/l of *C. papaya* treated fish.







**Figure 13.** Histological change observed in the liver of adult *O. niloticus* treated with 5.0 mg/l of *C. papaya* seed powder: Vacuole formation, shrinkage of cells.



**Figure 16.** Histological change observed in the kidney of adult *O. niloticus* treated with 5.0 mg/l of *C. papaya* seed powder: Complete degeneration of cells.



**Figure 14.** Histological change observed in the kidney of adult *O. niloticus* treated with 0 mg/l of *C. papaya* seed powder: No pathological lesion was observed.



**Figure 15.** Histological change observed in the kidney of adult *O. niloticus* treated with 4.8 mg/l of *C. papaya* seed powder: Karyolysis of the hepatocytes.

## ACKNOWLEDGEMENTS

Fund and facilities used for this study was provided by 2004 Senate Research Grant Award, given by, Cross River University of Technology, Calabar. This support is acknowledged with gratitude. Sincere thank go to Ofpor, Omini Emmanuel, Ezeogo, John Uro, the research assistants and special thanks go to the Technologists Mr. Erinle and Mr. Adesida, for analyzes of samples.

## REFERENCES

- Akah PA, Oli AN, Enwerem NM, Gamaniel K (1997). Preliminary studies on purgative effect of *Carica papaya* root extract. *Fitoterapia*, 68(4): 327-331.
- Annune PA, Ekpendu TOE, Ogbonaya NC (2002). Acute toxicity of aqueous extract of *Senna alata* to juvenile Tilapia *Oreochromis niloticus* (TREWAVAS). Bk. Of Abstack FISON 18<sup>th</sup>- 22<sup>nd</sup> nov. Uyo Nigeria.
- APHA (1989). Standard method for examination of wastewater and water (17<sup>th</sup> ed. Washington D.C.) Check the text; it is APHA (1987).Reconcile, p. 8910.
- Ayotunde EO, Ofem BO (2005). Acute and Chronic Toxicity of Pawpaw (*Carica papaya*) Seed Powder to Nile Tilapia *Oreochromis niloticus* (linne 1757), Fingerlings. *J. Agric. Technol. Environ* Vol.1 No 1.
- Ayuba VO, Ofojekwu PC (2002). Acute toxicity of the Jimson's weed (*Datura innoxia*) to the African catfish (*Clarias gariepinus*) Fingerlings *AJOL. J. Aqua. Sci.* 17: 2.
- Bodharkar SL, Gray SK, Mathus VS (1974). Antifertility screening part 1X. Effect of five indigenous plants on early pregnancy in female albino rats. *Ind. J. Med. Res.* 62: 831-837.
- Bancroft JD, Cook HC (1994). *Manual of histological techniques and their diagnostic application*. Churchill Livingstone, London. pp. 289-305.
- Chung-Min L, Bo-Ching C, Sher S, Ming-Chaaln, Chen-Wuing L, Bor-Cheng H (2003). Acute toxicity and bioaccumulation of arsenic in tilapia (*Oreochromis mossambicus*) from a blackfoot disease area of Taiwan. *Eviron. Toxicol.* 18(4): 252-259.
- Das RP (1980). Effect of Papaya seeds on the genital organs and fertility of male rats. *Ind. J. Exp. Biol.* 18: 408-409.

- Eno AE, Owo OI, Itam EH, Konya RS (2000). Blood pressure depression by the fruit juice of *Carica papaya* (L.) in renal and DOCA-induced hypertension in the rat. *Phytother. Res.* 14: 235-239.
- Ekanem SB, Okoronkwo TE (2003). Pawpaw seed as a fertility control agent on male Nile tilapia. *NAGA, World Fish Center Quarterly* 26(2): 8-10.
- Finney DJ (1971). *Statistical method in biological assay*, 2<sup>nd</sup> Ed. Hafner Pub. Co. New York. N.Y. 68p. Probit analysis. Cambridge University Press London, England.
- Gary SK, Gary (1971). Antifertility screening VII. Effect of five indigenous plant parts on early pregnancy in albino rats. *Ind. J. Med. Res.* 56: 302-306.
- Glazer AN, Smith EL (1971). Papain and other plant sulfhydryl proteolytic enzymes. In: Boyer PD (Ed.) *The Enzymes*, 3rd edn. Vol. 3. pp. 501-546. London: Academic Press.
- Herwig N (1979). *Handbook of drug and chemical used in the treatment of fish disease: A manual of fish farm and material Media*. Charles Thomas Pub. Springfield Illinois U.S.A.
- Hughes GM, Perry SF (1976). Morphometric study of trout gills: A light microscopic method for the evaluation of pollutant action. *J. Exp. Biol.* 63: 447-460.
- Ismail MK (2004). Papaya – A wholesome fruit – Health & Nutrition. <http://www.kjojnet.com>.
- Jack Wheeler MN (2003). Healthmate Papaya. <http://www.Papaya.aspx.htm>.
- Koesomadinata S (2000). acute toxicity of the insecticide formulation of endosulphan, chlorpyrifos, and chlorfluazuron to three freshwater fish species and freshwater giant prawn. *Jurnal Penelitian Perikanan Indonesia*, 4(3-4): 36-43.
- Litchfield JT, Wilcoxon F (1949). A simplified method of evaluation of dose effect experiment. *J. Pharmacol. Exp. Ther.* 96: 99-113.
- Lohiya NK, Manivannan B, Mishra PK, Pathak N, Sriram S, Bhande SS, Panneerdoss S (2002). Chloroform extract of *Carica papaya* seeds induces long-term reversible azoospermia in langur monkey. *Asian J. Androl.* 4: 17-26.
- Lohiya NK, Mishra PK, Pathak N, Manivannan B, Jain SC (1999). Reversible zoospermia by oral administration of the benzene chromatographic fraction of the chloroform extract of the seeds of *Carica papaya* in rabbits. *Adv. Contracept.* 15: 141-161.
- Mair GC, Little DC (1991). Population control in farmed tilapia, NAGA, ICLARM Q. 17(4): 8-14.
- Pathak N, Mishra PK, Manivannan B, Lohiya NK (2000). Sterility due to inhibition of sperm motility by oral administration of benzene chromatographic fraction of the chloroform extract of the seeds of *Carica papaya* in rats. *Phytomedicine* 7: 325-333.
- Reed W, Burchard J, Jonathan, Ibrahim Y (1967). Fish and fisheries of Northern Nigeria. Min. of Agric. Northern Nigeria.
- Santhakumar M, Balaji M (2000). acute toxicity of an organophosphorus insecticide monochrotophos and its effects on behaviour of an air breathing fish, *Anabas testudineus* (BLOCH). *J. Environ. Biol.* 21(2): 21-123.
- Seigler DS, Pauli GF, Nahrstedt A, Leen R (2002). Cyanogenic allosides and glucosides from *Passiflora edulis* and *Carica papaya*. *Phytochemistry* 60: 873-882.
- Svobodova D, Ravds J, Palackova (1991). Unified method of Haematological examination of fish. Research Inst. of Fish Culture and Hydrobiology. Vonnony Czechoslovakia.
- Udor P, Kehinde A (1999). Studies on antifertility effect of Pawpaw seeds (*Carica papaya*) on the gonads of male albino rats. *Phytother. Res.* 13: 226-228.
- USEPA (2000). Methods for measuring the acute toxicity of effluents to freshwater and marine organisms. 4<sup>th</sup> ed. Environmental Monitoring and support Laboratory, U.S. Environmental Protection Agency, Cincinnati, Ohio. EPA 600/4-85/013.
- Veile H (1990). Method: Black and White Film Development and Printing for Karyotype Analysis. [http://hg.wustl.edu/hdk\\_lab\\_manual/camcontents.html](http://hg.wustl.edu/hdk_lab_manual/camcontents.html).
- Wade JW, Omoregie E, Ezenwaka (2002). Toxicity of cassava (*Manihot esculenta* CRANTS) effluent on the Nile Tilapia *Oreochromis niloticus* (L) Under laboratory condition. *AJOL. J. Aqua. Sci.* 17(2).
- Wilson RK, Kwan TK, Kwan CY, Sorger GJ (2002). Effects of papaya seed extract and benzyl isothiocyanate on vascular contraction. *Life Sci.* 71: 497-507.