

Full Length Research Paper

Acute and sub-chronic toxicity studies of methanolic extract of *Tulbaghia violacea* rhizomes in Wistar rats

O. S. Olorunnisola¹, G. Bradley¹ and A. J. Afolayan^{2*}

¹Department of Biochemistry and Microbiology, University of Fort Hare, Private Bag X1314, Alice 5700, South Africa.

²Phytomedicine Research Group, Department of Botany, University of Fort Hare, Alice, 5700, South Africa.

Accepted 26 June, 2012

The methanolic extract of the rhizome of *Tulbaghia violacea* (RTV) was tested for toxicity in albino Wistar rats. A single oral administration of a 5 g/kg dosage of RTV extract did not produce mortality or significant behavioral changes during 14 days of observation. In the sub-chronic study, the extract administered daily for a period of 28 days showed no mortality or morbidity and the relative weights of organs were not affected by the treatment. However, significant weight gain in both treated and control group was observed. Indicators of liver damage such as alanine amino transferase (ALT) and aspartate amino transferase (AST), as well as total serum protein and albumin showed no significant alteration in the extract treated animals when compared with the controls at all doses used. The extracts caused a significant ($p < 0.05$) decrease in the activity of gamma glutamy transferase (γ GT) and alkaline phosphatase (ALP) when compared with the control. However, the extract did not have any significant effect on markers of kidney function or hematological parameters in the rats, except in the female rats where a significant increase ($p < 0.05$) in lymphocytes counts at 500 mg/kg was observed. Histopathological examination of the liver revealed no detectable inflammation. These results suggest that the rhizomes of *T. violacea* may be potentially safe for consumption.

Key words: *Tulbaghia violacea*, rhizomes, acute toxicity, subchronic toxicity.

INTRODUCTION

The majority of the world population relies on medicinal plants for the treatment and management of diseases (Albert et al., 2011). Over 5000 plants are known to be used for medicinal purposes in Africa, but only a few have been described or studied (Adebayo et al., 2010). The use of herbal remedies can be attributed to their perceived efficacy and the fact that they are a cheap source of medicals (Ogbonnia et al., 2010). There is also a strong belief that because herbal remedies are derived from nature, they are devoid of adverse or toxic side effects often associated with drugs used in conventional orthodox medicine (PushpaLatha et al., 2010). However, herbal preparations assumed to be safe may contain

contaminants such as pathogenic microbes (Kneifel et al., 2002), heavy metals (Abou-Arab and Abou-Donia, 2000) and aflatoxins (Dusane et al., 2007) due to the manner in which they are prepared. In addition, they are often administered over an extended period during disease management without consideration of long term toxic effects (Ogbonnia et al., 2009). Although, many medicinal preparations have been reported to be non-toxic (Albert et al., 2011), many others have been shown to be toxic (Albert et al., 2011).

Tulbaghia violacea is a very important plant used in the Eastern Cape of South Africa for the treatment of various ailments (Bungu et al., 2009). Ethnobotanical survey reported that *T. violacea* has been the most frequently used plant in the management of cardiovascular diseases in Nkonkobe Municipality, South Africa (Olorunnisola et al., 2011a). The remedy prepared with *T. violacea* leaves and roots is used locally to treat fever and colds, asthma,

*Corresponding author. E-mail: aafolayan@ufh.ac.za. Tel/Fax: +27866282295.

tuberculosis, stomach problems and esophageal cancer. It is also eaten as a vegetable (Bungu et al., 2009) and used as a snake repellent (Van Wyk et al., 1997; Van Wyk and Gericke, 2000).

Scientific evidence shows that various parts of the *T. violacea* plant possess biological activity. It was reported that the aqueous and ethanolic extracts of the plant tubers exhibit *in vitro* anthelmintic activity (McGaw et al., 2000). Other reported biological activity includes *in vitro* antibacterial (Gaidamashvili and Van Staden, 2001), antihypertensive effects (Motsei et al., 2003; Duncan et al., 1999) and *in vitro* anticoagulant and antithrombotic effects (Bungu et al., 2009).

In spite of a long record of the usage of various parts of *T. violacea* plant for various purposes, to the best of our knowledge, information available regarding its safety following repeated exposure of *T. violacea* rhizome extracts in experimental animals is scarce. Although, *in vitro* toxicity evaluation of dried and fresh methanolic extracts suggests the plant to be highly toxic (Olorunnisola et al., 2011b); it is important to investigate its *in vivo* toxicity.

The present study was designed to investigate the possible toxic effects of methanolic extracts of rhizomes of *T. violacea* at different doses in order to determine safe levels of the plant extract in rats. Histopathological and haematological examinations as well as biochemical parameters were used to assess toxicity.

MATERIALS AND METHODS

Plant collection and extract preparation

Plant collection and extract preparation was as earlier described by Mohammad and Woodward (1986) and modified by Olorunnisola et al. (2011b). Briefly, whole fresh rhizomes of *T. violacea* Harv. were collected from Alice, Eastern Cape, South Africa and authenticated by Professor D. S. Grierson of Botany Department, University of Fort Hare and deposited (Sin 2010/2) at the Giffen Herbarium, UFH. *T. violacea* rhizome was homogenized in a blender with 100% methanol at 4°C. The crude extracts were incubated at 37°C for 15 min, followed by centrifugation at 1500 xg for 10 min at 4°C. The supernatant was filtered using Whatman No. 1 filter paper and was concentrated under *vacuo* at 65°C using rotary evaporator. The partially dried sample was freeze dried and stored at 4°C in the dark.

Animals

Adult Wistar rats (135 to 185 g) of both sexes (males and females and no pregnant one) were used for the assessment of acute toxicity, while the female (nulliparous and no pregnant one) adult Wistar rats (128 to 192 g) were employed for the subchronic study. Animals were randomly assigned to control and treated groups (10 females per group). They were maintained under standard environmental conditions (22 ± 2°C, 12:12 h dark/light cycle, frequent air change) and had free access to tap water and standard animal feed. All animals were obtained from the animal house of the laboratory of the School of Biological Sciences, University of Fort Hare Alice, 5700, South Africa. All procedures used in the present study followed the "Principles of Laboratory Animal Care"

from NIH Publication No.85-23 and were approved by the Animal Ethics Committee of our university.

Acute oral toxicity

The acute toxicity study was conducted as per the OECD guidelines 420 (OECD, 2001) where the limit test dose of 5000 mg/kg was used (OECD, 2002). Rats (six weeks old) were divided into two groups of 3 animals each (males and females). The control group received distilled water that did not contain *T. violacea* extract. The extract when applied was suspended in a vehicle (distilled water). Following an overnight fasting period, body weight of the rats was determined and the administered dose was calculated with reference to the body weight. The volume of the extract solution given (orally gavage) to the rats was 10 ml/kg. Body weight, signs of toxicity and mortality were observed after the administration of the first, second, fourth and sixth hour and once daily for the next 14 days. On the 15th day, all rats were subjected to fasting for 16 to 18 h, and then sacrificed prior to examination. The internal organs were excised and weighed. The gross pathological features of the tissues were observed and recorded.

Subchronic toxicity

Subchronic toxicity testing was conducted according to WHO and OECD guidelines (OECD, 2008). Rats were divided into 4 groups of 10 animals each (5 females and 5 males). In the present study, the doses of methanolic *T. violacea* rhizome extracts were 125, 250 and 500 mg/kg/day. The extracts were dissolved in distilled water and orally given to each group of rats daily for 28 days, while the control group received the water vehicle. Rats were fasted overnight, anesthetized using halothane and sacrificed after the 29th day. Paired blood samples, heparinised and non-heparinised, were collected for hematological and serum biochemical assays.

Hematological and biochemical analysis

The hematological and serum biochemical parameters were determined using Beckman Coulter (Beckman Coulter Inc. Brea CA, USA) for hematology and a Piccolo automated chemistry analyser (Abaxis, Inc. Union City, CA, USA) for serum chemistry analysis respectively. Hematological parameters assayed included white blood cell (WBC) count, red blood cell (RBC) count, differential leukocyte counts, red cell distribution width (RCDW), platelets, haematocrit, hemoglobin estimation, mean cell volume (MCV), mean corpuscular hemoglobin (MCH) and mean corpuscular hemoglobin concentration (MCHC). Sera were assayed for glucose, creatinine, blood urea nitrogen, aspartate transaminase (AST), alanine transaminase (ALT), alkaline phosphatase (ALP), gamma-glutamyl transferase (γGT), calcium, magnesium, inorganic phosphorus, protein and albumin.

Histopathological studies

Histopathological examination of the liver, aorta and hearts of the animals from each group was conducted by first fixing the tissues in 10% formaldehyde. They were then dehydrated and paraffin blocks were made. Then, sectioning was done at about 5 to 7 μm. Routine histopathology was performed by using the haematoxylin stain.

Statistical analysis

Data were expressed as the mean ± SD of six replicates and were

Table 1. Body weights of male and female rats after 28 days of oral administration of methanolic extracts of *T. violacea* rhizomes.

Parameter	Body weight (g ± SD) per week				
	0	1	2	3	4
Female					
Control	138 ± 1.32	143 ± 1.21 ^a	146 ± 1.42 ^b	149 ± 1.03 ^c	152 ± 1.25 ^d
125 (mg/kg)	138 ± 1.21	141 ± 1.25 ^a	145 ± 1.11 ^b	148 ± 1.20 ^c	151 ± 1.30 ^d
250 (mg/kg)	138 ± 1.23	142 ± 1.19 ^a	146 ± 1.18 ^b	148 ± 1.16 ^c	152 ± 1.08 ^d
500 (mg/kg)	135 ± 1.20	140 ± 1.15 ^a	141.0 ± 1.16 ^b	144 ± 1.21 ^c	149 ± 1.25 ^d
Male					
Control	127 ± 1.44	132 ± 1.11 ^a	137 ± 1.23 ^b	141 ± 1.14 ^c	144 ± 1.05 ^d
125 (mg/kg)	128 ± 1.30	133 ± 1.23 ^a	138 ± 1.20 ^b	142 ± 1.32 ^c	143 ± 1.25 ^d
250 (mg/kg)	130 ± 1.01	135 ± 1.31 ^a	140 ± 1.31 ^b	144 ± 1.20 ^c	145 ± 1.03 ^d
500 (mg/kg)	129 ± 1.34	134 ± 1.17 ^a	139 ± 1.05 ^b	143 ± 1.38 ^c	144 ± 1.14 ^d

Mean ± SD (n = 5) and GP = values in same column with different alphabets are significantly different (p < 0.05).

subjected to one way analysis of variance (ANOVA) followed by Duncan multiple range tests to determine significant differences in all the parameters. Values were considered statistically significant at p < 0.05.

RESULTS AND DISCUSSION

Acute toxicity

The oral administration of fresh methanolic extract of *T. violacea* rhizomes (5g/kg.bwt) did not cause rat mortality during the 72 h and 14 day observation, and there was no indication of toxicity, behavioral or physiological changes. Also, the extract did not cause any appreciable alterations in water and food intake (data not shown) in either the male or female rats during 2 weeks course of the experiment. Further, body weight gain during the observation period among the treated animals was comparable to their respective controls, and no sex-related differences were evident. The results of the *in vivo* acute toxicity study indicated that the LD₅₀ of the extract of rhizomes of *T. violacea* is more than 5000 mg/kg. Therefore, methanolic extracts of rhizomes of *T. violacea* appears to be devoid of acute toxicity.

Sub-chronic toxicity

Administration of extracts of *T. violacea* rhizomes for 28 days produced no signs of toxicity or mortality in either sex. The treated animals did not show any significant alteration in water or food consumption (data not shown). Similarly, no significant differences in percentage body weight gain were observed between control and treated groups during this period (Table 1). Assessment of the effect of the plant extracts on body weight and organs of

experimental animals is an important test in toxicity evaluation. The alteration in overall body weight or organ-body weight ratio is an indication of impairment in the normal functioning of the organs (Amresh et al., 2008). As shown in Table 1, male and female rats in both the control and treated groups showed progressive increase in body weight and organs over the course of the four weeks of treatment.

The observed increase in body weight could be attributed to the nutritive components in the plant (Ezeonwumelu et al., 2011; Duke, 1997). However, there was a general reduction in mean percentage body weight gain of rats administered with the rhizomes of *T. violacea* extract as compared to the control (Table 2). The observed reduction in body weight gain among the rats was relatively dose dependent (Figures 1 and 2) and this suggests that the extract could be used in weight control management. Since there was no reduction in relative body and organ weight of the treated animals at any of the doses tested, we concluded that the extract is non-toxic to the analysed organs.

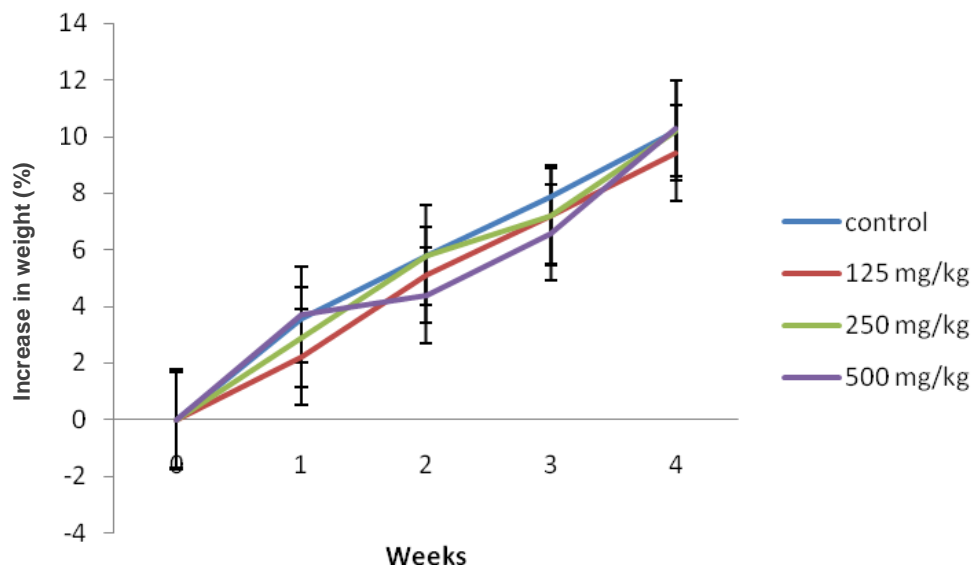
Biochemical and hematological parameters

Biochemical parameters: Assessment of liver and kidney function is very important in toxicity evaluation of drugs and plant extracts as they are both necessary for the survival of an organism. AST and ALT activities are commonly measured to monitor liver damage. A mild or higher activity of AST indicates liver injury or myocardial infarction (Feldman and Zinkl, 2000; Crook, 2006) and the ratio of AST/ALT may be employed in disease diagnosis. An AST/ALT ratio greater than 1 suggests myocardial infarction, while a ratio less than 1 may be due to the release of ALT from the affected liver (Sacher

Table 2. Relative organ weight of rats (males and females) after a 28 day treatment with methanolic rhizome extracts of *T. violacea*.

GP	Extract(mg/kg)	Relative weight of organ (g ± SD)			
		Heart	Liver	Kidney	Pancreas
Female					
1	Control	0.64 ± 0.03 ^a	6.79 ± 0.02 ^b	0.64 ± 0.02 ^c	0.44±0.01 ^d
2	125	0.66 ± 0.02 ^a	6.98 ± 0.01 ^b	0.66 ± 0.02 ^c	0.48±0.01 ^d
3	250	0.65 ± 0.03 ^a	6.12 ± 0.01 ^b	0.62 ± 0.02 ^c	0.48±0.02 ^d
4	500	0.67 ± 0.10 ^a	6.17 ± 0.03 ^b	0.65 ± 0.02 ^c	0.45±0.01 ^d
Male					
1	Control	0.61 ± 0.01 ^a	6.50 ± 0.02 ^b	0.58 ± 0.12 ^c	0.39±0.08 ^d
2	125	0.59 ± 0.05 ^a	6.21 ± 0.11 ^b	0.61 ± 0.10 ^c	0.42±0.12 ^d
3	250	0.60 ± 0.02 ^a	5.99 ± 0.21 ^b	0.59 ± 0.08 ^c	0.40±0.10 ^d
4	500	0.58 ± 0.03 ^a	6.07 ± 0.13 ^b	0.60 ± 0.10 ^c	0.38±0.11 ^d

Mean ±SD (n = 5) and GP = represents group. Values in same column with different alphabet are significantly different (p < 0.05).

**Figure 1.** Mean percentage weight increase of the control and treated female rats in the sub-chronic toxicity study.

and Mepherson, 1991). An AST/ALT ratio of more than 2 is indicative of alcoholic hepatitis or cirrhosis (Varadarasou et al., 2010). In the present study, the extract did not induce any damage to the liver or kidney as revealed by the results of clinical blood chemistry analysis (Table 3).

The lack of significant alterations in the indicators of liver damage (ALT, AST, alkaline phosphatase, total protein, albumin and γ GT) (Table 3), suggests that sub-chronic administration of methanolic *T. violacea* rhizome extracts does not affect hepatocyte function in the animals. Although, a slight insignificant dose dependant

increase in the activity of AST was observed in the extract treated groups, the increase may not be associated with liver damage as the extract produced a significant reduction (p<0.05) in the activity of ALP and ALT, which are the main markers of liver injury.

Our results also show a none statistically significant decrease in levels of gamma GT at all doses tested, when compared with the control after 28 days of administration. However, the values obtained are within the normal range (Barry, 1995). The secretory ability of the liver was considered by assessing changes in albumin, total bilirubin and globulin concentrations

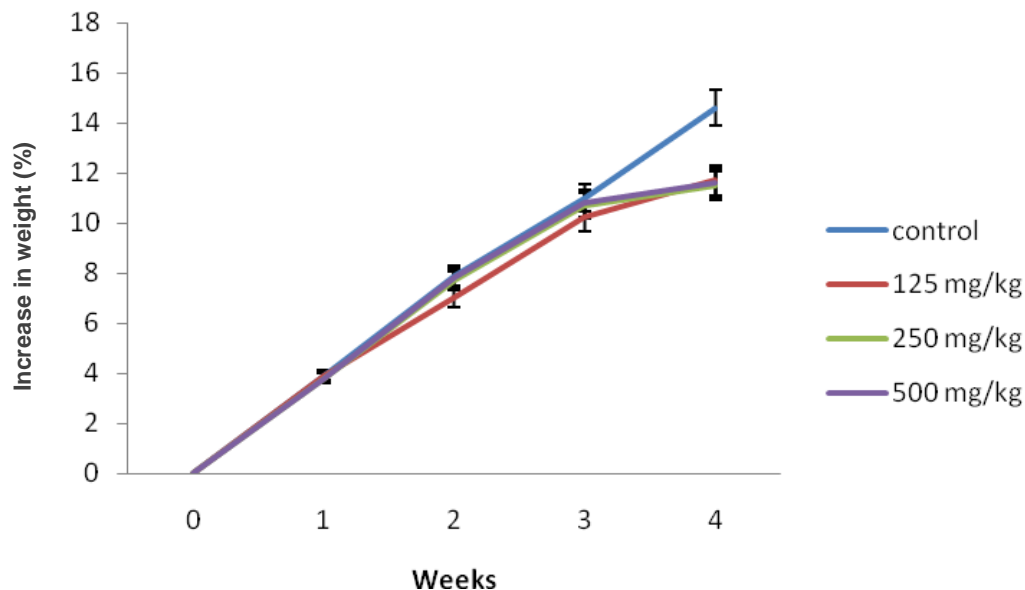


Figure 2. Mean percentage weight increase of the control and treated male rats in the sub-chronic toxicity study.

Table 3. Effect of daily administration of rhizomes of *T. violacea* methanolic extracts for 28 days on biochemical profiles of the control and treated rats in the sub-chronic toxicity study.

Female	Control	Dose of <i>T. violacea</i> extract administered (mg/kg of body weight/day)			
		125	250	500	
ALP U/L	237.2±0.01 ^a	169.0±0.05 ^b	180.2±0.05 ^b	184.3±0.02 ^b	
AST U/L	112.1±0.12 ^b	113.0±0.02 ^b	115.10±0.02 ^b	121.10±0.01 ^b	
ALT U/L	42.30±0.31 ^b	45.25±0.03 ^b	43.10±0.03 ^b	42.10±0.03 ^b	
γGT U/L	5	<5	<5	<5	
Total protein (mg/dl)	6.70±0.05 ^b	6.95±0.04 ^b	6.50±0.03 ^b	6.90±0.01 ^b	
Albumin (mg/dl)	2.10±0.09	2.35±0.10 ^b	2.30±0.03 ^b	2.40±0.03 ^b	
Total bilirubin (mg/dl)	0.30±0.11 ^b	0.30±0.02 ^b	0.30±0.01 ^b	0.30±0.02 ^b	
Urea (mg/dl)	2.10±0.04 ^b	3.01±0.50 ^b	2.40±0.50 ^b	2.70±0.20 ^b	
Creatinine (mg/dl)	0.02±0.07 ^b	0.02±0.05 ^b	0.02±0.01 ^b	0.02±0.10 ^b	
Potassium (mmol/L)	6.62±0.11 ^b	6.80±0.01 ^b	6.86±0.02 ^b	6.90±0.13 ^b	
Sodium (mmol/L)	140.0±0.12 ^b	143.1±0.11 ^b	141.2±0.12 ^b	144.0±0.12 ^b	
Calcium (mg/dl)	10.9±0.01 ^b	9.80±0.02 ^b	10.3±0.01 ^b	10.2±0.03 ^b	

Mean ± SD triplicate determinations (n = 8). Values in the same row with different alphabets are significantly different (p < 0.05).

(Guyton and Hall, 2000). Reduction in total protein, albumin and globulin are indications of diminished synthetic function of the liver or might be due to impaired hepatocellular function. Low serum albumin content may suggest infection or continuous loss of albumin (Tietz et al., 1994; Yakubu et al., 2003). Thus, the insignificant change in serum concentration of total protein, albumin and globulin in the treated and control group further suggests that the extract does not impair hepatocellular or secretory functions of the liver at any of the doses tested an interpretation that is confirmed by the

histological analysis which showed no lesions (Figure 3a and b). Kidney function was evaluated by means of serum urea, creatinine and blood electrolyte concentrations. Increased blood creatinine is a good indicator of compromised kidney function. In the present study, serum creatinine, urea and electrolytes such as sodium and calcium were not affected by the extract treatment.

However, a slight insignificant increase was observed in the levels of urea, sodium and potassium when compared with control. However, the values are still within the normal range. These results suggest that the extract

Table 4. Mean hematological values in rats treated with the *T. violacea* methanolic extract for 28 days.

Parameter	Dosage (mg/kg of body weight/day)			
	Control	125	250	500
Red cell count/L	7.26 x 10 ^{12a}	6.73 x 10 ^{12a}	6.82 x 10 ^{12a}	6.80 x 10 ^{12a}
Hemoglobin g/dl	14.9 ^a	13.9 ^a	13.6 ^a	13.8 ^a
PCV %	37 ^a	37 ^a	36.9 ^a	36.8 ^a
Haematocritic	0.42 ^a	0.40 ^a	0.40 ^a	0.40 ^a
MCV	58 ^a	59 ^a	58 ^a	58 ^a
MCH	21 ^a	21 ^a	20 ^a	20 ^a
MCHC	35 ^a	35 ^a	35 ^a	35 ^a
RDW	12.3 ^a	14.2 ^b	13.7 ^b	12.8 ^a
White cell count/L	6.90 x 10 ^{9a}	6.50 x 10 ^{9a}	6.3 x 10 ^{9a}	7.25 x 10 ^{9a}
Neutrophils/L	1.79 x 10 ^{9a}	1.40 x 10 ^{9a}	1.37 x 10 ^{9a}	1.45 x 10 ^{9a}
Lymphocytes/L	4.97 x 10 ^{9b}	5.07 x 10 ^{9b}	5.67 x 10 ^{9b}	6.10 x 10 ^{9a}
Monocytes/L	0.14 x 10 ^{9a}	0.26 x 10 ^{9a}	0.10 x 10 ^{9a}	0.19 x 10 ^{9a}
Platelet count/L	949 x 10 ^{9a}	942 x 10 ^{9a}	941 x 10 ^{9a}	939 x 10 ^{9a}

Values in the same row with different alphabet are significantly different ($p < 0.05$).

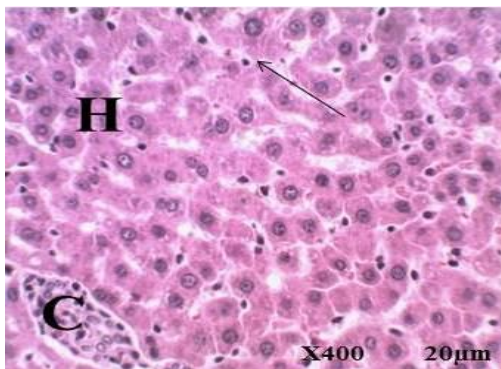


Figure 3a. Photomicrograph of liver section from a normal rats showing central vein (C), hepatocytes (H) and sinusoidal spaces with Kuffer cells (arrow) (Scale bar: 20 μ m x 400 magnification; H&E stain).

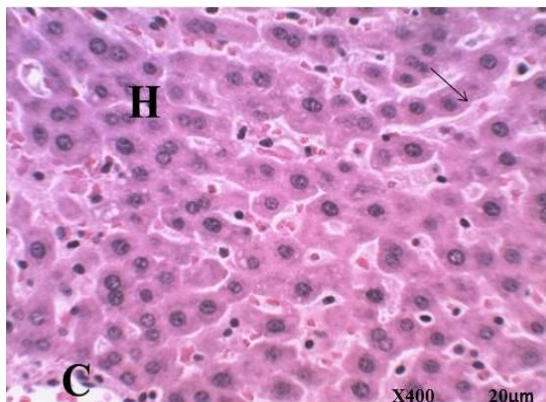


Figure 3b. Photomicrograph of liver section from rats treated with 500 mg/kg bwt/day (28 days) showing no lesion (Scale bar: 20 μ m x 400 magnification; H&E stain).

does not alter the kidney function.

Evaluation of hematological parameters is important in toxicity assessment as changes in haematological indices have a higher predictive value for human toxicity (Adebayo et al., 2005). Subchronic administration of methanolic rhizome of *T. violacea* (RTV) extracts daily for 28 days did not cause any significant change in hematological profile apart from the number of lymphocytes, which increased significantly ($P < 0.05$) in the group treated with 500 mg/kg dose as compared to the control (Table 4). However, the values obtained are within the normal range (Olson et al., 2000; Andrew, 1965; Mohammad and Woodward, 1986; Archer et al., 1977; Birgel et al., 1986). The results showed no deleterious effects on blood cell counts and hemoglobin content, thereby suggesting that RTV had no toxic effect on blood system. The significant dose dependent increase in lymphocytes suggests that the extract may contain biologically active compound(s) that can boost the immune system (WHO, 2003) or it may be due to an imbalance in the rate of hematological parameter synthesis and catabolism (OECD, 2001). The non-significant effect of the extracts on RBC, HGB, RDW, MCV, MCH, platelets and MCHC means that the extract does not affect erythropoiesis, morphology or osmotic fragility of the red blood cells (Guyton and Hall, 2000). Since monocytes have been shown to increase in cases of infection (Mohammad and Woodward, 1986), the reduction in monocytes with the administration of the extract suggests that the extract does not provoke tissue damage or infection (Barry, 1995). The alteration produced by the extract of *T. violacea* rhizomes on the lymphocytes, as well as its non-significant effect on red blood cells suggests a dose selective, stimulatory effect on the bone marrow (Andrew, 1965).

Conclusion

The results suggest that consumption of methanolic extracts of the rhizomes of *T. violacea* may be relatively safe and that the rhizomes may contain biologically active principles that have the ability to boost the immune system by increasing the population of defensive white blood cells. This property may account for its utility in folk medicine.

REFERENCES

- Abou-Arab AA, Abou-Donia MA (2000). Heavy metals in Egyptian spices and medicinal plants and the effect of processing on their levels. *J. Agric. Food Chem.* 48(6):2300-2304.
- Adebayo AH, Abolaji AO, Opata TK, Adegbenro KI (2010). Effects of ethanolic leaf extract of *Chrysophyllum albidum* G. on biochemical and haematological parameters of albino Wistar rats. *Afr. J. Biotechnol.* 9(14):2145-2150.
- Adebayo JO, Adesokan AA, Olatunji LA, Buoro DO, Soladoye AO (2005). Effect of Ethanolic extract of *Bougainvillea spectabilis* leaves on haematological and serum lipid variables in rats. *Biokemistri* 17:45-50.
- Albert DA, Telephone BN, Jacques YD, Albert (2011). Acute and subchronic oral toxicity assessment of the aqueous extract from the stem bark of *Erythrina senegalensis* DC (Fabaceae) in rodents. *J. Ethnopharm.* 134(3):697-702.
- Amresh GR, Singh PN, Rao VC (2008). Toxicological screening of traditional medicine Laghupatha (*Cissampelos pareira*) in experimental animals. *J. Ethnopharmacol.* 116:454-460.
- Andrew W (1965). *Comparative hematology*. New York: Grune Stratton, pp.144-146.
- Archer RK, Jeffcott LB, Lehmann H (1977). *Comparative clinical haematology*, Oxford: Blackwell pp.611-613.
- Barry SL (1995). *Animal Clinical Pathology*. In: Micheal JD, Mannfred AH eds. *CRC Handbook of Toxicology*, CRC Press, Inc. U.S.A. pp.517-537.
- Birgel Junior EH, Benesi FJ, Lenz FF, Birgel EH (1986). Estudo das variações de parâmetros hematológicos de animais de laboratório I hemograma de ratos (*Rattus norvegicus*). In: Conferência Anual da Sociedade Paulista DE Medicina Veterinária. 41., São Paulo, 1986. *Resumos*. São Paulo: Sociedade Paulista de Medicina Veterinária pp.1-3.
- Bungu L, Maryna van de V, Carminita F (2009). Evidence for an *in vitro* anticoagulant and antithrombotic activity in *Tulbaghia violacea*. *Afr. J. Biotechnol.* 7(6):681-688.
- Crook MA (2006). *Clinical Chemistry and Metabolic Medicine*. 7th Edition. Hodder Arnold, London p.426.
- Duke JA (1997) *The Green Pharmacy: New Discoveries in Herbal Remedies for Common Diseases and Conditions from the World's Foremost Authorities on Healing Herbs*. Rodale, Retrieved from: www.greenpharmacy.com
- Duncan AC, Jager AK, Van Staden J (1999). Screening of Zulu medicinal plants for angiotensin converting enzyme (ACE) inhibitors. *J. Ethnopharm.* 68:63-70.
- Dusane T, Yaowapa S, Prapaporn S, Saowalak S, Oraphan P, Sittichai C (2007). Inhibitory Effect of Essential Oils on the Growth of *Aspergillus flavus*. *KMITL Sci. Tech. J.* 7:1-7.
- Ezeonwumelu JOC, Julius AK, Muhoho CN, Ajayi AM, Oyewale AA, Tanayen JK, Balogun SO, Ibrahim A, Adzu B, Adiukwu CP, Oloro J, Kiplagat DM, Goji ADT, Okoruwa AG, Onchweri AN, Reddy PMK (2011). Biochemical and Histological Studies of Aqueous Extract of *Bidens pilosa* Leaves from Ugandan Rift Valley in Rats. *Br. J. Pharmacol. Toxicol.* 2(6):302-309.
- Feldman BV, Zinkl JG (2000). *Schalm's Veterinary Hematology*, 5th ed. Philadelphia, Lea Febiger pp.1210-1218.
- Gaidamashivili M, Van Staden J (2001). Interaction of lectin-like proteins of South African medicinal plants with *Staphylococcus aureus* and *Bacillus subtilis*. *J. Ethnopharm.* 80:131-135.
- Guyton AC, Hall JE (2000). *Textbook of Medical Physiology* (Tenth Edition) Harcourt International Edition, W.B Saunder Company Philadelphia pp.279-281.
- Kneifel W, Czech E, Kop B (2002). Microbial contamination of medicinal plants – A Rev. *Planta. Med.* 68(1):5-15.
- McGaw LJ, Jager AK, Van Staden J (2000). Antibacterial, anthelmintic and anti-amoebic activity in South African medicinal plants. *J. Ethnopharmacol.* 72:247-263.
- Mohammad SF, Woodward SC (1986). Characterisation of a potent inhibitor of platelet aggregation and release reaction isolated from *Allium sativum* (Garlic). *Thrombosis Res.* 44:793-806.
- Motsei ML, Lindsey KL, Van Staden J, Jager AK (2003). Screening of traditionally used South African plants for antifungal activity against *Candida albicans*. *J. Ethnopharm.* 86:235-241.
- OECD (2001). *The OECD guideline for testing of chemical. The organization of Economic co-operation development*, Paris pp.1-14.
- OECD (2002). *Guidelines for the Testing of Chemicals/Section 4: Health Effects Test No. 423: Acute Oral toxicity - Acute Toxic Class Method*. Organization for Economic Cooperation and Development, Paris, France.
- OECD (2008). *Repeated dose oral toxicity test method*. In: *OECD Guidelines for testing of chemicals, N°407*. Organization for Economic Cooperation and Development, Paris, France.
- Ogbonnia SO, Mbaka GO, Anyika EN, Ladiju O, Igbokwe HN, Emordi JE and Nwakakwa N (2010). Evaluation of Anti-diabetics and Cardiovascular Effects of *Parinari curatellifolia* Seed Extract and *Anthoclista vogelli* Root Extract Individually and Combined on Postprandial and Alloxan-Induced Diabetic Albino Rats. *Br. J. Med. Res.* 1(3):146-162.
- Ogbonnia SO, Florence E, Nkemehule, Emmanuel N, Anyika EN (2009). Evaluation of acute and subchronic toxicity of *Stachytarpheta angustifolia* (Mill) Vahl (Fam. Verbanaceae) extract in animals. *Afr. J. Biotechnol.* 8(9):1793-1799.
- Olorunnisola OS, Bradley G, Afolayan AJ (2011a). Ethnobotanical information on plants used for the management of cardiovascular diseases in Nkonkobe Municipality, South Africa. *J. Med. Plants Res.* 5(17):4256-4260
- Olorunnisola OS, Bradley G, Afolayan AJ (2011b). Antioxidant properties and cytotoxicity evaluation of methanolic extract of dried and fresh rhizomes of *Tulbaghia violacea*. *Afr. J. Pharm. Pharmacol.* 5(22):2490-2497.
- Olson H, Betton G, Robinson D, Thomas K, Monro A, Kolaja G, Lilly P, Sanders J, Spes G, Bracken W, Dorato M, Deun KV, Smith P, Berger B, Heller A (2000). Concordance of toxicology of pharmaceuticals in humans and animals. *Regul. Toxicol. Pharmacol.* 32:56-67.
- PushpaLatha B, Rama Manohar Reddy L, Mannur Ismail S, Vijaya T (2010). Medicinal Plants and Their Derivatives as Potential Source in Treatment of Obesity. *Asian J. Exp. Biol. Sci.* 1(4):719-727.
- Sacher RA, Mepheron RA (1991) *Widmann's clinical interpretation of laboratory test*, U.S.A., Pennsylvania. 3rd edition. pp.416-443.
- Tietz NW, Prude EL, Sirgard- Anderson O (1994). *Tietz textbook of Clinical Chemistry*. (Burtis, C.A and Ashwood, E.R eds). W.B. Saunders Company: London pp.1354-1374.
- Van Wyk B-E, Gericke N (2000). *People's plants: a Guide to Useful Plants of Southern Africa*, 1st Edition, Brizza Publications, Pretoria p.351.
- Van Wyk BE, Van OB, Gericke N (1997). *Medicinal plants of South Africa*, 1st Ed, Brizza Publications, Pretoria p.138.
- Varadarasou M, Mounnissamy S, Kavimani, Gnanapragasam S, Sabarimuthu D, Quine, Kuppuswamy S (2010). Evaluation of acute and sub-acute toxicity of ethanol extracts of *Cansjera rheedii* J. Gmelin (Opiliaceae). *J. Brew. Dist.* 1(1):11-14.
- WHO (2003). *WHO guidelines on good agricultural and collection practices (GACP) for medicinal plants*. World Health Organization, Geneva.
- Yakubu MT, Bilbis LS, Lawal M, Akanji MA (2003). Effect of repeated administration of sildenafil citrate on selected enzyme activities of liver and kidney of male albino rate. *Niger. J. Pure Appl. Sci.* 18:1395-4000.