

## Full Length Research Paper

## Fenthion induced toxicity and histopathological changes in gill tissue of freshwater African catfish, *Clarias gariepinus* (Burchell, 1822)

Peace Onas Somdare<sup>1</sup>, Christopher Didigwu Nwani<sup>2\*</sup>, Alfreda O. Nwadinigwe<sup>3</sup>, Jacinta Chinedu Nwani<sup>4</sup>, Gregory Ejike Odo<sup>2</sup>, Ogechi Nnabuchi Ugbor<sup>2</sup>, Juliana A Ukonze<sup>5</sup> and Ada Bridget Chidi Ezeibe<sup>6</sup>

<sup>1</sup>Department of Biological Sciences, Federal University Lokoja, Kogi State, Nigeria.

<sup>2</sup>Department of Zoology and Environmental Biology, University of Nigeria Nsukka, Enugu State, Nigeria.

<sup>3</sup>Department of Plant Science and Biotechnology, University of Nigeria Nsukka, Enugu State, Nigeria.

<sup>4</sup>Department of Crop Science and Land Scape Management, Ebonyi State University Abakaliki, Ebonyi State, Nigeria.

<sup>5</sup>Department of Vocational Teacher Education, University of Nigeria Nsukka, Enugu State, Nigeria.

<sup>6</sup>Department of Agricultural Economics/CDR, University of Nigeria Nsukka, Enugu State, Nigeria.

Received 4 May, 2015; Accepted 15 June, 2015

Fenthion is an organophosphate pesticide commonly used in agriculture and public health for the control of insect pests. The present study investigated the toxic effect of fenthion and the histopathological alterations in the gill tissue of African catfish *Clarias gariepinus*. The 96 h LC<sub>50</sub> value of fenthion in *C. gariepinus* determined by probit analysis was found to be 39.97 mg/L. Fish exposed to different fenthion concentrations showed clinical signs such as erratic swimming, attempt to jump out of water, increased opercula frequencies, air gasping, mucus secretion followed by exhaustion and death. To evaluate the histopathological changes in the gill tissue, fish were exposed to 2.0, 4.0 and 8.0 mg/L corresponding to 1/20, 1/10 and 1/5<sup>th</sup>, respectively of 96 h LC<sub>50</sub> of fenthion for 21 days and 7 days recovery. Gill disorder and fusion of the secondary lamellar were pronounced in all treatments. Alterations in gill structure exposed to the highest concentration were oedema, lifting of lamellar epithelia, destruction of gill architecture and lamellar fusion. From the findings, it can be deduced that fenthion-induced alterations are irreversible and therefore should be applied with caution in the environment so as to reduce its damage to aquatic organisms.

**Key words:** *Clarias gariepinus*, fenthion, lethal concentration, histopathology.

### INTRODUCTION

Organic insecticide poisoning remains one of the major health issues in both developing and developed communities (Peter and Cherian, 2000). A great propor-

tion of acute poisoning cases are caused by exposure to pesticides, especially organophosphate (OP) compounds. The primary mechanism of action of OP pesticides is

\*Corresponding author. E-mail: didigwunwani@yahoo.com, chris.nwani@unn.edu.ng. Tel: +2348037509910.

based on inhibition of the acetylcholinesterase (AChE) enzyme (Eto, 1979). Once AChE has been inactivated, acetylcholine (ACh) accumulates throughout the nervous system, resulting in overstimulation of muscarinic and nicotinic receptors. Fenthion (*O,O*-Dimethyl *O*-[3-methyl-4-(methylsulfanyl) phenyl] phosphorothioate) is a systemic OP insecticide widely used in both agricultural and urban areas for controlling many sucking and biting pests (Cong et al., 2009; Sevgiler and Uner, 2010). Like all organophosphate insecticides, fenthion acts on the nervous system as inhibitor of acetylcholinesterase (AChE), an enzyme that hydrolyzes acetylcholine (ACh). Acetylcholine is a molecule that is involved in the transmission of nervous signals from nerves to muscles and between neurons in the brain (Jungera, 2014). Due to fenthion toxicity, the Environmental Protection Agency (EPA) has classified it as restricted use pesticide (RUP) that warrants special handling (ATSDR, 2005). Large amounts of pesticides find their ways into water bodies due to repeated application for the control of pest. The indiscriminate use of pesticides, careless handling, accidental spillage or discharge into natural water ways have harmful effects on fish population and other aquatic organisms and may contribute to long term effects (Nwani et al., 2013b).

Histopathological studies help to establish causal relations between contaminant exposure and various biological responses (Boran et al., 2012) and have proven to be a sensitive tool used in detecting direct effects of chemical compounds within target organs of fish in laboratory experiments (Altinok and Capkin, 2007; Capkin et al., 2009). A study on histopathology provides very important and useful data concerning changes in cellular or sub cellular structure of an organ much earlier than external notification. One of the advantages of using histopathological biomarkers in environmental studies is that it allows the examination of target organs (Gernhofer et al., 2001) and the alterations found in these organs are easier to identify than functional ones (Fanta et al., 2003). These alterations serve as warning signs of damage to the well-being of an organism.

Research has demonstrated that fenthion induced DNA damage and should be considered potentially hazardous to humans (Wu et al., 2011). Recent research by Kanter and Celik (2012) revealed that exposure of frogs to fenthion induced an increase in melondialdehyde (MDA) and antioxidant defense systems. The effect of fenthion on biochemical changes in *Cirrhina mrigala* (Israel and Sam, 2012), liver function and pigmentation (Muralidharan and Pillai, 2012) in *Cyprinus carpio* have been reported. Studies have demonstrated that exposure of fish to different pesticides resulted to histopathological changes in the gill, liver and kidney tissues (Auta, 2001; Maduenho and Martinez, 2008; Capkin and Altinok, 2013). The fish species *Clarias gariepinus* is an attractive model for ecotoxicological studies because of its hardiness in culture, omnivorous feeding habits and availability throughout the

year. In spite of the wide use of fenthion in Nigeria, there is however paucity of information on its effects on indigenous fish species. The present study was thus aimed at determination of the lethal concentration, behavioral effects and histopathological changes in gill tissues of freshwater African catfish, *C. gariepinus* exposed to fenthion.

## MATERIALS AND METHODS

### Experimental fish specimen and chemical

Freshwater African catfish *C. gariepinus* (Burchell 1822) (Family: Clariidae, Order: Siluriformes), mean standard length of  $27.36 \pm 0.23$  cm and weight of  $197.39 \pm 2.34$  g were procured from Freedom Fisheries Ltd Nsukka, Enugu, Nigeria and transported to our wet laboratory where they were treated with 0.05% potassium permanganate ( $\text{KMnO}_4$ ) for 2 min to avoid any dermal infections. The fish were acclimatized for three weeks in plastic tanks of 300 L capacity and fed *ad libitum* daily with commercial available food (Coppens International Helmond Netherlands) containing 35% crude protein. To maintain hygienic condition and prevent pollution caused by food and feces, fecal matter and other waste materials were siphoned off daily. Dead fish were removed with plastic forceps to avoid possible deterioration of water quality. During the period of acclimation, the water in the tanks was renewed daily with well aerated tap water. The feeding was terminated 24 h prior to the range finding and acute toxicity test to avoid interference of feces. The mean water quality of the test water analyzed daily during the experimental period following the standard methods (APHA, AWWA, WPCF, 2005) had the following physicochemical characteristics: temperature ( $24.40^\circ\text{C}$ ; SE 0.56), dissolved oxygen (6.77 mg/L; SE 0.80), conductivity (285 Mm/cm; SE 6.50), pH (7.22; SE 0.60), and total hardness (as  $\text{CaCO}_3$  - 240 mg/L; SE 6.60). For the present study, commercial formulation of fenthion manufactured by Yufull Industry Co, Ltd., China containing 600 g/L fenthion was purchased from the local market and used.

### Acute toxicity bioassay and behavioral responses

Acute toxicity bioassay to determine the 96 h  $\text{LC}_{50}$  values of fenthion was conducted using standard methods (APHA, AWWA, WPCF, 2005). The range finding test was carried out before determining the concentrations of the test chemical for the definitive test. For the definitive test, a set of 10 fish were randomly exposed to fenthion concentrations of 12, 24, 36, 48, 60 and 72 mg/L derived from a range finding test using plastic aquaria (60 × 30 × 30 cm size) containing 25 L aerated tap water. Another set of 10 fish was simultaneously maintained in equal amount of tap water but without the test insecticide and considered as the control. The experiments were set in triplicates to obtain the  $\text{LC}_{50}$  values of the test chemical. Fish were not fed throughout the experiment and lethality was the toxicity end point. Fish were visually examined daily and considered dead when no sudden swimming in response to gentle touch was observed. Dead fish were removed with plastic forceps and the mortality was recorded at intervals of 24, 48, 72 and 96 h. The  $\text{LC}_{10-90}$  values of the test insecticide for the fish at 24, 48, 72 and 96 h was determined by probit analysis (Finney, 1971). During the acute toxicity test, the no observed effect concentration (NOEC) was determined as the highest concentration in which no mortality was observed while lowest observed effect concentration (LOEC) was also determined using acute toxicity results. The safe levels of the test pesticide was estimated by multiplying the 96 h  $\text{LC}_{50}$  with

**Table 1.** Cumulative mortality of *Clarias gariepinus* exposed to various concentrations of fenthion.

Concentration (mg l <sup>-1</sup> )	Number of fish exposed	Number of deaths				Mortality (%)	Survival (%)
		24 h	48 h	72 h	96 h		
Control	30	0	0	0	0	0	100
12	30	0	0	0	0	0	100
24	30	2	2	2	4	13	87
36	30	2	6	10	12	40	60
48	30	4	10	12	18	53	47
60	30	12	16	22	24	80	20
72	30	24	30	30	30	100	0

**Table 2.** Lethal concentration of fenthion (mg/L) (95% confidence interval) depending on exposure time for *Clarias gariepinus* (n=10 in three replicates).

Lethal concentration (mg/L)	Exposure time (h)			
	24 h	48 h	72 h	96 h
LC <sub>10</sub>	36.14 <sup>a</sup> (0.59-48.16)	30.90 <sup>b</sup> (8.03-40.36)	28.04 <sup>b</sup> (14.08-35.39)	23.97 <sup>c</sup> (18.84-27.85)
LC <sub>30</sub>	49.70 <sup>a</sup> (17.79-79.51)	41.22 <sup>b</sup> (21.94-52.06)	37.11 <sup>b</sup> (25.37-44.43)	32.42 <sup>c</sup> (27.92-36.04)
LC <sub>50</sub>	61.99 <sup>a</sup> (45.76-81.74)	50.32 <sup>b</sup> (37.15-73.60)	45.06 <sup>c</sup> (35.87-55.32)	39.97 <sup>d</sup> (35.95-43.93)
LC <sub>70</sub>	77.30 <sup>a</sup> (57.83-458.20)	61.43 <sup>b</sup> (48.88-133.89)	54.71 <sup>c</sup> (45.75-76.34)	49.27 <sup>d</sup> (44.80-55.33)
LC <sub>90</sub>	106.33 <sup>a</sup> (71.56-778.35)	81.94 <sup>b</sup> (61.55-374.99)	72.41 <sup>c</sup> (58.10-136.00)	66.64 <sup>d</sup> (58.74-80.92)

Values in rows with different superscript letters differ significantly ( $p < 0.05$ ).

different application factors (AF) and were based on the methods of Hart et al., (1948), Sprague (1971), CWQC (1972), NAS/NAE (1973), IJC (1977), and CCREM (1991). The behavioral responses of *Clarias gariepinus* at different concentrations of fenthion were observed from 24 to 96 h of the exposure.

#### Sublethal concentrations and tissue preparation

The 96 h LC<sub>50</sub> value of fenthion in the present study was determined to be 39.97 mg/L. Based on this value, three sublethal concentrations of 2.0, 4.0 and 8.0 mg/L corresponding to 1/20, 1/10 and 1/5<sup>th</sup> of fenthion, respectively were prepared by serial dilution of the stock solution. A total of 30 acclimatized fish were exposed to each of the aforementioned sublethal test concentrations in triplicates of 10 fish per replicate. Control fish specimens were maintained in dechlorinated tap water without fenthion. The exposure lasted for 21 days after which the fish were withdrawn from the insecticide and kept for seven days in dechlorinated tap water for possible recovery. To avoid catabolism due to starvation during the chronic exposure, the fish were fed daily small quantity of food (approximately 1% of total body weight) an hour before renewal of the test solution. On day 1, 7, 14, 21 and 7 days recovery, one fish from each replicate treatment group and control was sacrificed after anesthetizing with tricaine methanesulfonate (MS 222) to minimize stress. The fish were dissected and gill tissues were removed, preserved in 10% phosphate buffered formalin for 24 h, dehydrated by a series of upgraded ethanol solution, embedded in paraffin, and sectioned at 5 µm thick. A total of three tissue sections per fish for each replicate concentration were routinely processed and stained with Hematoxylin and Eosin (H & E) and examined by light microscopy according to Roberts (2001). Photomicrographs were then taken at (x100) objective and

the fish of the control groups were compared with that of exposed groups under the guidance of a pathologist.

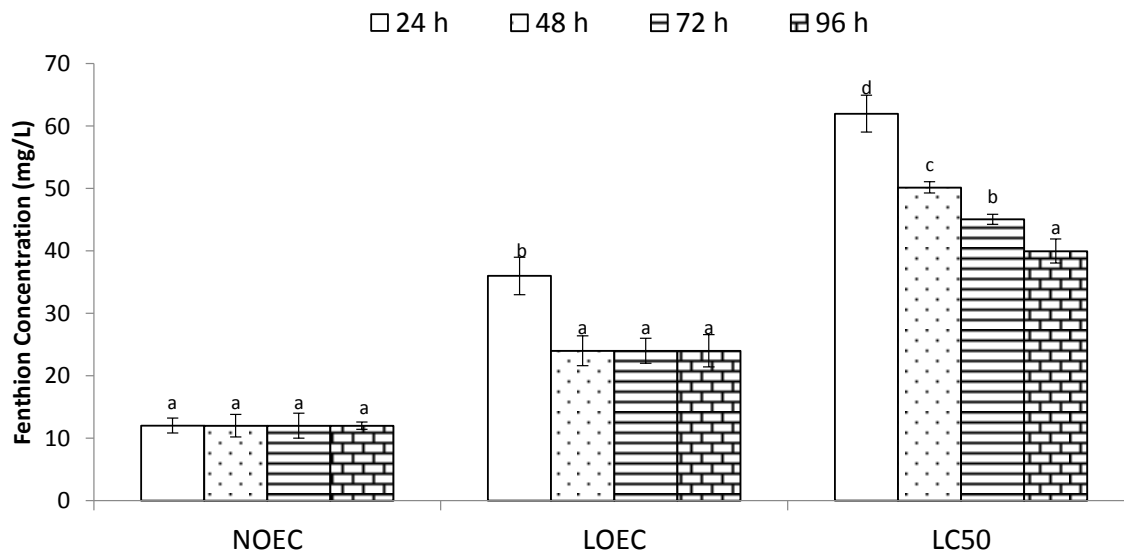
#### Statistical analysis

The data obtained were statistically analyzed using statistical package for social sciences (SPSS) version 21.0 software (SPSS, Inc., Chicago, Illinois, USA) and Duncan's multiple range test was used to determine the significant difference at 5% probability level.

## RESULTS

#### Median lethal concentration (LC<sub>50</sub>) and safe level

The mortality of *C. gariepinus* exposed to different concentrations of fenthion is presented in Table 1. A dose-dependent increase and time dependent decrease was observed in mortality rate such that as the exposure time increases from 24 to 96 h, the median lethal concentration required to kill the fish was reduced. The LC<sub>50</sub> values (with 95% confidence limits) of different concentrations of fenthion were found to be 61.99 (45.76 to 81.74), 50.32 (37.15 to 73.60), 45.06 (35.87 to 55.32) and 39.97 (35.95 to 43.89) mg/L for 24, 48, 72 and 96 h exposure, respectively (Table 2). The statistical end points of acute toxicity test are shown in Figure 1. NOEC was not significantly different during acute toxicity test (p



**Figure 1.** Statistical end points of acute toxicity testing in *Clarias gariepinus* exposed to fenthion for different durations (24, 48, 72 and 96 h).

**Table 3.** Estimate of safe levels of fenthion at 96 h exposure time in *Clarias gariepinus*.

Pesticide	96h LC <sub>50</sub> (mg/L)	Method	AF	Safe level (mg/L)
Fenthion	39.97	Hart et al. (1948)*	-	9.96 x 10 <sup>-1</sup>
		Sprague (1971)	0.1	3.99
		CWQC (1972)	0.01	3.99 x 10 <sup>-1</sup>
		NAS/NAE (1973)	0.01-0.00001	3.99 x 10 <sup>-1</sup> - 3.99 x 10 <sup>-4</sup>
		CCREM (1991)	0.05	1.99
		IJC (1977)	5% of 96 h LC <sub>50</sub>	1.99

\*C = 48 h LC<sub>50</sub> × 0.03/S<sup>2</sup>, where C = presumable harmless concentration and S = 24 h LC<sub>50</sub>/48 h LC<sub>50</sub>

> 0.05). LOEC was not significant ( $p > 0.05$ ) except at 24 h of the exposure where it was significant. The estimated safe levels of fenthion in *C. gariepinus* varied from 3.99 to 3.997 (Table 3).

### Behavioural responses of *C. gariepinus* exposed to fenthion

The behavioural responses of the test fish were observed at 24 to 96 h of the exposure (Table 4). In the control group, normal behavioural responses such as non-hyperactivity, normal swimming patterns and fin movements were observed. Fish exposed to different concentrations of fenthion displayed behavioural abnormalities in response to the test chemical. At the initial exposure, fish were alert, stopped swimming and remained static in position in response to the sudden changes in the surrounding environment. After some few seconds, fish in the experimental group tried to avoid the

test water by swimming rapidly and trying to jump out of the aquaria. Fish in aquaria that had higher concentrations of the pesticide showed abnormal behaviour and tried to avoid the test water by swimming very fast, jumping and displaying erratic with vigorous jerky movements, faster opercula movement, and gulping of air. Skin discoloration was mostly observed in fish that were exposed to the highest concentration of fenthion while it was least in the lowest concentration. After sometime, the fish lost their balance and became exhausted owing to respiratory difficulty. They settled down passively at the bottom of the aquaria and died.

### Histopathological observations of gills in *Clarias gariepinus* exposed to fenthion

Histopathological changes in *C. gariepinus* were observed during the experiment (Figures 2 to 4). No alterations were observed in the gills of the control. The

**Table 4.** Effects of fenthion on the behavioural characteristics of *Clarias gariepinus* at different exposure durations.

Concentration (mg/L).	Equilibrium status	Fin movement	Hyperactivity	Jerky movement	Swimming rate
<b>24 h</b>					
Control	+++	+++	-	-	+++
12	+++	+++	-	-	+++
24	+++	+++	-	-	+++
36	++	++	+	++	++
48	++	++	+	+++	++
60	+	+	+	+++	+
72	+	+	+	+++	+
<b>48 h</b>					
Control	+++	+++	-	-	+++
12	+++	+++	-	-	+++
24	+++	+++	-	-	+++
36	++	++	+	+	++
48	+	++	+	++	++
60	+	+	++	+++	+
72	+	+	++	+++	+
<b>72 h</b>					
Control	+++	+++	-	-	+++
12	++	++	-	+	+++
24	+	+	+	++	++
36	+	+	+	++	+
48	+	+	++	++	+
60	-	-	+++	+++	-
72	-	-	+++	+++	-
<b>96 h</b>					
Control	+++	+++	-	-	+++
12	++	++	-	+	++
24	++	++	+	++	++
36	+	+	+	++	+
48	+	+	++	+++	+
60	-	-	+++	-	+
72	-	-	+++	-	-

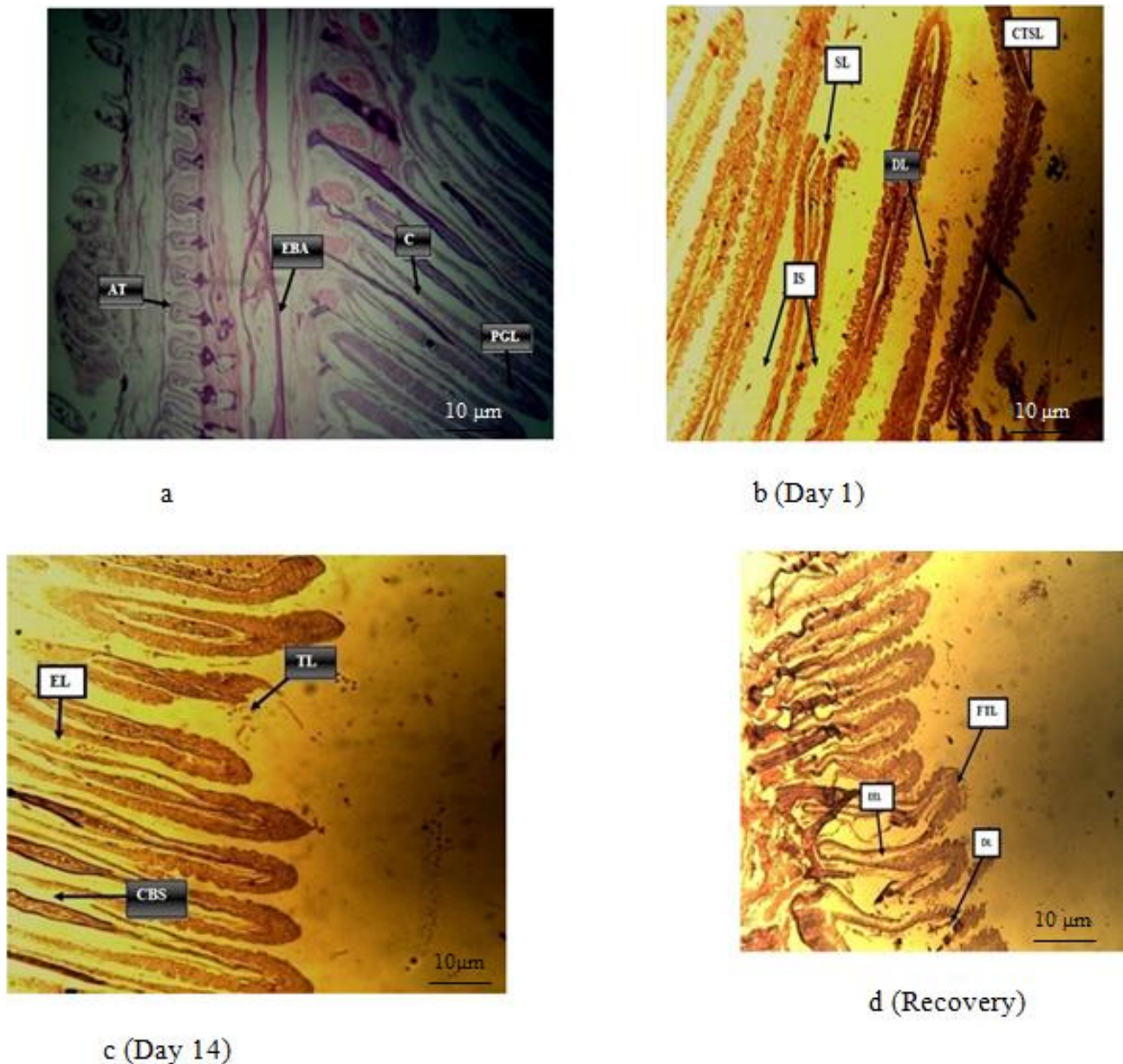
-, None; +, mild; ++, moderate; +++, strong.

severity and frequency of gill lesions were found to be more pronounced in fish exposed to the highest concentration of fenthion. Histopathological alterations were concentration and duration dependent. The most common pathological changes in the gills of the exposed fish species were fusion of the tip of lamella, deformed lamella, congestion of blood spaces, epithelial lifting, intercellular space variation and hypertrophy of lamella (Table 5).

## DISCUSSION

Acute and chronic toxicity tests are mostly used to

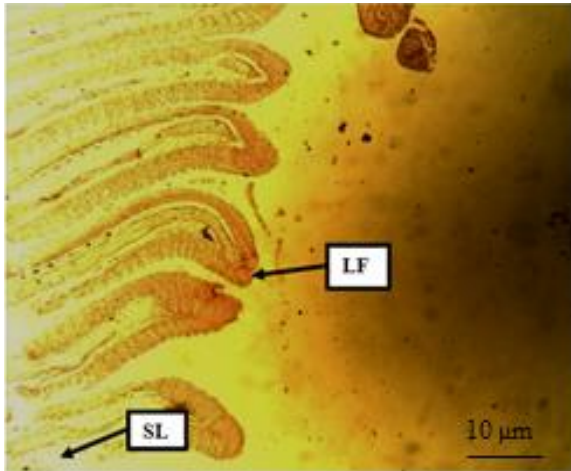
assess the toxicity of chemicals on non-target organisms (Santos et al., 2010). The 96 h LC<sub>50</sub> is one of the most important parameters for evaluating the toxic effects of pollutants (Nwani et al., 2015). In the present study, the 96 h LC<sub>50</sub> values of fenthion for the African catfish, *C. gariepinus* was found to be 39.97 mg/L. This suggests that fenthion is toxic to fish. The observed mortality was dose and time dependent such that as the exposure time increased from 24 to 96 h, the median lethal concentration required to kill the fish was reduced. The 100% mortality observed in fish exposed to 72.0 mg/L of fenthion indicates that the insecticide was very toxic. The 96 h LC<sub>50</sub> value obtained in the present investigation was higher than the 1.5 mg/L 96 h LC<sub>50</sub> value of fenthion



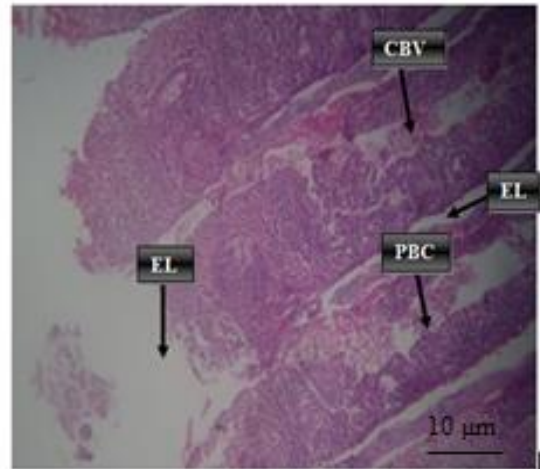
**Figure 2.** Photomicrograph of gill section of *Clarias gariepinus* of the control (A) showing normal adipose tissue (AT), efferent branchial artery (EBA), cartilage (C) and primary gill lamella (PGL) and fish exposed to 2.0 mg/L (b-d) fenthion showing intercellular spaces (IS), fusion of the tip of secondary lamella (SL), deformed lamella (DL), destruction of the curved tip of secondary lamella (CTSL), epithelial lifting (EL) and congestion of blood spaces (CBS).

previously reported in *C. carpio* (Muralidharan, 2012). The disparity in the toxic potential of the pesticide may be attributed to the difference in age and hardness of the test species and water quality parameters. According to Johnson and Toledo (1993), the difference in the toxic potential of fenthion can be related to its accumulation, biotransformation and excretion. In general, toxicity of chemicals to aquatic organisms has been reported to be affected by temperature, pH, dissolved oxygen, size and age, strain of species, water quality, concentration and

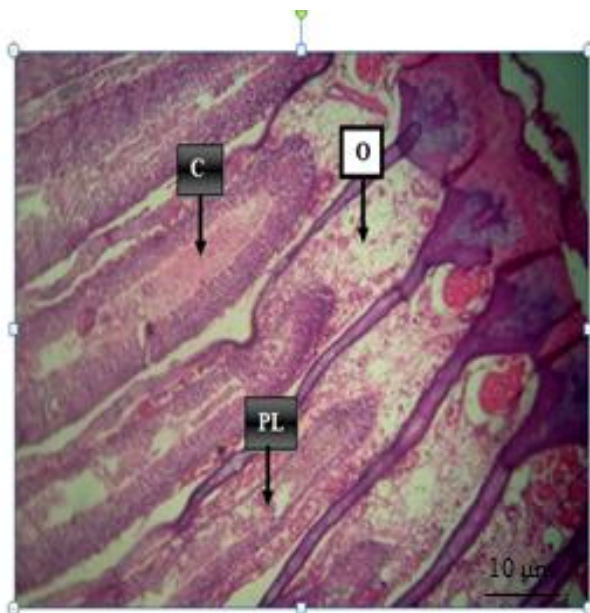
formulation of test chemicals (Nwani et al., 2010; Boran et al., 2012; Rauf and Arain, 2013). The magnitude of toxic effects of pesticides also depends on the length and weight, corporal surface/body weight ratio and breathing rate (Murty, 1986). Oh et al. (1991) also reported that varied inhibition of acetylcholinesterase, detoxification and absorption are factors causing the selective toxicity of pesticides for various species of fish. The safe levels obtained for fenthion in the present study varied from  $3.99 \times 10^{-4}$  to 3.99.




**a** (Day 1)



**b** (Day 14)



**c** (Recovery)

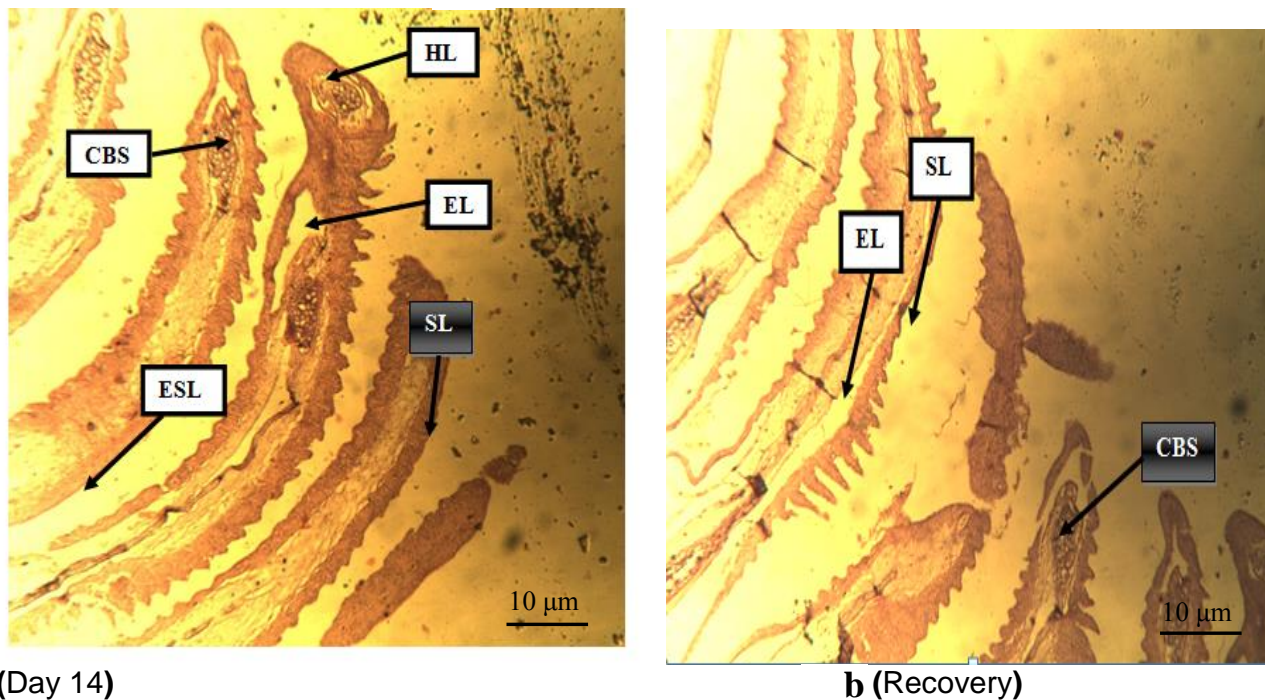


**d** (Day 1)

**Figure 3.** Photomicrographs of gill section of *Clarias gariepinus* in fish exposed to 4.0 mg/L (a-c) fenthion showing severe lamellafusion (LF), proliferation of blood cells (PBCs), epithelial lifting (EL), congestion (C), oedema (O), destruction of primary lamella (PL) and fish exposed to 8.0 mg/L, (d) fenthion congestion of blood spaces (CBS), partial epithelial lifting (PEL), clogged blood vessel and erosion of secondary lamella (ESL).

However, the large variation in safe levels determined by various methods has resulted in controversy over its acceptability as extrapolation of laboratory data to field data was not always meaningful hence, the difficulty in deciding the acceptable concentration that may be considered 'safe' based on laboratory experiments (Buikema et al., 1982; Pandey et al., 2005). Behavioural changes in fish are the most sensitive indicators of potential toxic effects of pesticide exposure (Banaee et

al., 2011; Rauf and Arain, 2013). Clinical symptoms observed during acute exposure of *C. gariepinus* to fenthion in the present study are consistent with the findings of other authors and may indicate fenthion-induced suppressed activity of acetylcholinesterase. The abnormal behaviour exhibited by fish in the experimental groups such as abnormal swimming behaviour are due to inhibition of AChE activity leading to accumulation of acetylcholine in cholinergic synapses thus causing hyper



**Figure 4.** Photomicrograph of gill sections of *Clarias gariepinus* exposed to 8.0 mg/L (a-b) fenthion showing hypertrophy of the tip of lamella (HL), epithelial lifting (EL), congestion of blood spaces (CBS) and destroyed secondary lamella (SL).

**Table 5.** Summarized histopathological effects in the gill tissues of *Clarias gariepinus* exposed to fenthion and the control.

Conc. (mg/L)	Duration (days)	Congestion of blood spaces	Destruction primary of lamella	Destruction of secondary lamella	Epithelial lifting	hypertrophy	Lamella fusion	oedema
Control	1	0	0	0	0	0	0	0
2.0	1	0	0	0	0	0	0	0
4.0	1	0	0	0	1	0	1	0
8.0	1	3	0	0	2	0	0	0
Control	14	0	0	0	0	0	0	0
2.0	14	1	1	1	1	0	0	0
4.0	14	2	0	0	2	0	2	0
8.0	14	3	0	0	3	3	0	0
Control	Recovery	0	0	0	0	0	0	0
2.0	Recovery	0	1	1	0	0	0	0
4.0	Recovery	3	0	0	0	0	0	1
8.0	Recovery	3	0	0	3	0	0	0

Lesions were scored based on their severity (0: none, 1: mild, 2: moderate, 3: severe).

stimulation. Fenthion may inhibit AChE activity due to its accumulation in the brain tissues. This may lead to impairment of the normal functioning of nerve impulse causing physiological and behavioural modifications that can lead to reduction in survival ability (Muralidharan, 2014a). The behavioural symptoms observed during C.

*gariepinus* exposure to fenthion in this study is similar to observations by other authors on the responses of different fishes exposed to organophosphate pesticides. It has been reported that under stress condition, fish become hyperactive, perhaps to get out of the stressful medium and would require an increased amount of oxygen



to meet their energy demand (Alkahem et al., 2011).

Muralidharan (2012) reported that hyperactivity of fish exposed to pollutants could be attributed to impaired gill function and the secretion of increased amount of mucus to coat the body and gills may be attempt to get relief from the irritating pollutants. The secretion of copious mucus by fish could also be a defence mechanism to neutralize the effect of pesticides which gradually cover the body, gills, and buccal cavity. Repeated opening and closing of the mouth and opercula covering accompanied by partially extended fin (coughing) as observed in the present study could be due to clearance of the accumulated mucus debris in the gill region for proper breathing. Similar behavioural changes in *C. gariepinus* exposed to atrazine and chlorpyrifos (Nwani et al., 2013a) and *C. mrigala* exposed to diazinon (Rauf and Arain, 2013) have been reported.

Exposure of organisms to sub-lethal concentrations of pesticides in the environment has been reported to result in biochemical, physiological and histopathological alterations in vital tissues (Anbu and Ramaswamy, 1999). The histological results observed in gill tissues of *C. gariepinus* in the present study indicate that sub-lethal concentrations of fenthion caused moderate to severe alteration in gill architecture which are important organs performing vital functions. Histopathological lesions observed in gill tissues of *C. gariepinus* exposed to fenthion in the present study are similar to reports in *C. carpio* exposed to (Muralidharan, 2014b). Similar pathological lesions in the gill architecture were observed in *Oreochromis niloticus* exposed to dimethoate (Elezaby et al., 2001), *Puntius gonionotus* exposed to paraquat (Cengiz and Unlu, 2006), *Oncorhynchus mykiss* exposed to the fungicide captan (Boran et al., 2012) and in *Gobiocypris rarus* (Yang et al., 2010), *Gnathonemus petersii* (Alazemi et al., 2012) and *C. carpio* (Blahova et al., 2014) exposed to atrazine. Epithelial hypertrophy could be as a result of epithelial detachment as stated by Machado and Fanta (2003). Epithelial lifting increases the distance through which the toxicant reach the blood stream thereby causing impaired oxygen uptake (Kumar et al., 2010) and could result in dysfunction or even non-functional gills and eventually suffocate the fish. Lamella fusion could be a protective mechanism as it reduces the amount of vulnerable gill surface area. According to Olurin et al. (2006) these pathological changes may be a reaction to toxicant intake or an adaptive response to prevent the entry of the pollutants through the gill surface and probably increase capillary permeability. The oedema observed in fish gills exposed to fenthion could be due to acute inflammatory nature of the lesion induced by fenthion. Oedema with epithelial separation was reported by Eller (1971) as additional change in fish gills exposed to toxicants.

Though histological changes observed in the present study and that of Muralidharan (2014b) revealed that the changes were concentration dependent, some authors

reported that such structural changes are non-toxicant specific (Meyers and Hendricks, 1985), which could be mere stress response of fish to toxicant exposures (Gabriel et al., 2007). The structural changes observed in tissues throughout the duration of exposure were expected to normalize as reported by Myers et al. (1992) who stated that it is possible for the gill to regenerate and recover from the alterations but no such regeneration and recovery were observed at the post exposure test which shows that the changes observed were non reversible.

## Conclusion

Fenthion is toxic to fish and possibly other aquatic organisms. It has the potential to damage the physiology of fish leading to observed changes in behavioural pattern with resultant dose dependent mortality. Histopathological results clearly indicate that sublethal concentrations of fenthion had destructive effects in the gill tissues of *C. gariepinus*. The study shows the significance of behavioural parameters in assessing the risk associated with pesticide exposure to fish. Environmental monitoring programs for the pesticide is necessary in view of the hazard and side effects that might be associated with excessive use on non-target organisms especially fish.

## Conflict of interests

The author(s) did not declare any conflict of interest.

**Abbreviations:** OP, Organophosphate; AChE, acetylcholinesterase; ACh, acetylcholine; EPA, Environmental Protection Agency; RUP, restricted use pesticide; MDA, melondialdehyde; KMnO<sub>4</sub>, potassium permanganate.

## REFERENCES

- Agency for Toxic Substances and Disease Registry (ATSDR) (2005). Toxicologic Information about Insecticides Used for Eradicating Mosquitoes (West Nile Virus Control). Department of Health and Human Services: ATSDR. [http://www.atsdr.cdc.gov/consultations/west\\_nile\\_virus/fenthion.html](http://www.atsdr.cdc.gov/consultations/west_nile_virus/fenthion.html). Accessed: June 25th, 2014.
- Alazemi BM, Lewis JW, Andrews EB (2012). Gill damage in the freshwater fish *Gnathonemus petersii* (family: Mormyridae) exposed to selected pollutants: an ultrastructural study. *Environ. Technol.* 17(2): 225- 238.
- Alkahem-Al-Balawi HF, Ahmad Z, Al-Akel AS, Al-Misned F, Suliman, EM, Al-Ghanim KA (2011). Toxicity bioassay of lead acetate and effects of sublethal exposure on growth, haematological parameters and reproduction in *Clarias gariepinus*. *Afr. J. Biotechnol.* 10: 11039-11047.
- Altinok I, Capkin E (2007). Histopathology of rainbow trout exposed to sublethal concentrations of methiocarb, a carbamate pesticide, to rainbow trout. *Toxicol. Pathol.* 35: 405-410.
- Anbu RB, Ramaswamy M (1999). Adaptive changes in respiratory movements of an air breathing fish, *Channa striatus* (Bleeker)

- exposed to carbamate pesticide, sevin. *J. Ecobiol.* 3:11-16.
- APHA, AWWA, WPCF (2005). Standard methods for the examination of water and waste water. 21st edition. New York: American Public Health Association.
- Auta J (2001). Toxicity of Dimethoate to Juveniles of *Oreochromis niloticus* (Trewavas) and *Clarias gariepinus* (Tengels). Ph.D. Thesis. Ahmadu Bello University, Zaria, Nigeria.
- Banaee M, Sureda A, Mirvaghefi AR, Ahmadi K (2011). Effects of diazinon on biochemical parameters of blood in rainbow trout (*Oncorhynchus mykiss*). *Pestic. Biochem. Physiol.* 99:1-6.
- Blahova J, Modra H, Sevcikova M, Marsalek P, Zelnickova L, Skoric M, Svobodova Z (2014). Evaluation of biochemical, haematological and histopathological responses and recovery ability of common carp (*Cyprinus carpio*) after acute exposure to atrazine herbicide. ID 980948. <http://dx.doi.org/10.1155/2014/980948>.
- Boran H, Capkin E, Altinok I, Terzi E (2012). Assessment of acute toxicity and histopathology of the fungicide captan in rainbow trout. *Exp. Toxicol. Pathol.* 64:175-179.
- Buikema JR, Naider-Lehner AL, Cairns JR (1982). Biological monitoring: part IV. Toxicology testing. *Environ. Mol. Mutagen* 33: 239-262.
- Canadian council of Resources and Environmental Ministry (CCREM) (1991). Canadian water quality guidelines, Inland Waters Directorate. Environment Canada: Ottawa, UN, Canada.
- Capkin E, Altinok I (2013). Effect of chronic carbosulfan exposure on liver antioxidant enzyme activities in rainbow trout. *Environ. Toxicol. Pharmacol.* 36:80-87.
- Capkin E, Birincioglu S, Altinok I (2009). Histopathological changes in rainbow trout (*Oncorhynchus mykiss*) after exposure to sublethal composite nitrogen fertilizers. *Ecotoxicol. Environ. Saf.* 72: 1999-2004.
- Cengiz EI, Unlu E (2006). Sublethal effects of commercial deltamethrin on the structure of the gills, liver and gut tissues of mosquito fish, *Gambusia affinis*: a microscopic study. *Environ. Toxicol. Pharmacol.* 21:246-253.
- Committee on Water Quality Criteria (CWQC) (1972). A Report of the Committee on Water Quality Research Series. EPA-R3-73-003, US Environmental Protection Agency Report; CWQC: Cincinnati, OH, USA.
- Cong NV, Phuong NT, Bayley M (2009). Effect of exposure of diazinon on cholinesterase activity and growth in *Channa striatus*. *Ecotoxicol. Environ. Saf.* 72: 699-703.
- Elezaby MM, El-Serafy S, Heckmann RK, Sharf E, Seddek MM (2001). Effects of some toxicants on the freshwater fish, *Oreochromis niloticus*. *J. Egypt. German Soc. Zool.* 36:407-434.
- Eller LL (1971). Histopathologic lesions in culthroat trout (*Salmo clark*) exposed chronically to the insecticide endrin. *Am. J. Pathol.* 64 - 321.
- Eto M (1979). Organophosphorus Pesticides: Organic and Biological Chemistry. Boca Raton (FL): CRC Press.
- Fanta E, Rios FS, Romao S, Vianna ACC, Freiburger S (2003). Histopathology of the fish *Corydoras paleatus* contaminated with sublethal levels of organophosphorus in water and food. *Ecotoxicol. Environ. Saf.* 54(2):119-130.
- Finney YT (1971). Probit Analysis. Cambridge University Press: Cambridge.
- Gabriel UU, Amakiri EU, Ezeri GN. (2007). Haematology and gill pathology of *Clarias gariepinus* exposed to refined petroleum oil, kerosene under laboratory conditions. *J. Anim. Vet. Adv.* 6(3):461-465.
- Gernhofer M, Pawet M, Schramm M, Muller E, Triebkorn R (2001). Ultra structural biomarkers as tools to characterize the health status of fish in contaminated streams. *J. Aquat. Ecosyst. Stress Recover.* 8:241-260.
- Hart WB, Weston RF, Dermann JG (1948). An apparatus for oxygenating test solution which fish are used as test animals for evaluating toxicity. *Trans. Am. Fish. Soc.* 75:288.
- International Joint Commission (IJC) (1977). New and Revised Great Lakes Water Quality Objectives. Great Lake Basin, Windsor; IJC: Ottawa, ON, Canada.
- Israel SS, Sam MS (2012). Biochemical changes in certain tissues of *Cirrhinus mrigala* (Hamilton) (Cyprinidae: cypriformes) exposed to fenthion. *Int. J. Environ. Sci.* 2:1268-1277.
- Johnson CM, Toledo MCF (1993). Acute toxicity of endosulfan to the fish *Hyphessobrycon bifasciatus* and *Brachydanio rerio*. *Arch. Environ. Contam. Toxicol.* 24:151-155.
- Jungera P (2014). Fenthion safety summary for veterinary use on dogs, cats, cattle, sheep, goats and swine. Toxicity, poisoning, intoxication, overdose, antidote. Parasitipedia.net. Accessed 18<sup>th</sup> February 2015.
- Kanter A, Celik I (2012). Acute effects of fenthion on certain oxidative stress biomarkers in various tissues of frogs (*Rana ridibunda*). *Toxicol. Ind. Health* 28(4):369-376.
- Kumar M, Prasad MR, Srivastava K, Tripathi S, Srivastava AK (2010). Branchial histopathological study of Catfish *Heteropneustes fossilis* following exposure to purified neem extract, Azadirachtin. *World J. Zool.* 5(4):239-243.
- Machado M, Fanta E (2003). Effects of the organophorous methyl parathion on the branchial epithelium of a freshwater fish *Metynnis eossevelti*. *Braz. Arch. Biol. Technol.* 46(3):361-372.
- Maduenho LP, Martinez CBR (2008). Acute effects of diflubenzuron on the freshwater fish *Prochilodus lineatus*. *Comp. Biochem. Physiol.* 148:265-272.
- Meyers TR, Hendricks JD (1985). Histopathology. In: Rand, G. M., Petrocellis, R. (Editors). *Fundamentals of Aquatic toxicology: Methods and Application*. Hemisphere Publishing Corp, Washington, DC.
- Muralidharan L (2012). Haemato-Biochemical alterations induced by chronic exposure to fenthion in *Cyprinus carpio*. *Trends Fish. Res.* 1(3):19-25.
- Muralidharan L (2014a). Chronic toxic impacts of fenthion on the profiles of enzymes in the freshwater fish *Cyprinus carpio* (Linn). *Int. J. Fish. Aquat. Stud.* 1(4):51-56.
- Muralidharan L, Pillai S (2012). Chronic effects of organophosphorus insecticides. 'fenthion' in melanophore pigments of *Cyprinus carpio* (Linn). *ARPN J. Sci. Technol.* 2:296-300.
- Muralidharan L (2014b). Histopathological studies on carp (*Cyprinus carpio*) exposed to fenthion. *Int. J. Adv. Res.* 2: 11-26.
- Murty AS (1986). Toxicity of Pesticides to Fish. CRC Press Inc Boca Raton.
- Myers MS, Olson OP, Johnson LL, Stehr CS, Homt R, Varansi U (1992). Hepatic neoplasm and related lesions and exposure to toxic chemicals in marine fish from U.S West. *Environ. Health Perspect.* 90:7-15.
- NAS/NAE (1973). Water Quality Criteria, EPA-R3-033; US Government Printing Office: Washington, DC, USA.
- Nwani CD, Ama UI, Okoh F, Oji UO, Ogbonyealu RC, Agha A (2013a). Acute toxicity of the chloroacetanilide herbicide butachlor and its effects on behaviour of the freshwater fish *Tilapia zilli*. *Afr. J. Biotechnol.* 12:499-503.
- Nwani CD, Ekwueme HI, Ejere VC, Onyike CC, Chukwuka CO, Onas PS, Nwadinigwe AO (2015). Physiological effects of paraquat in juvenile African catfish *Clarias gariepinus* (Burchell 1822). *J. Coast. Life Med.* 3(1):35-43.
- Nwani CD, Ivoke N, Ugwu DO, Atama C, Onyishi GC, Echi PC, Ogbonna SA (2013b). Investigation on acute toxicity and behavioural changes in a freshwater catfish, *Clarias gariepinus* (Burchell, 1822), exposed to organophosphorous pesticide, Termifos. *Pak. J. Zool.* 45(4):959-965.
- Nwani CD, Lakra WS, Nagpure NS, Kumar R, Kushwaha B, Srivastava SK (2010). Mutagenic and genotoxic effects of carbosulphan in freshwater fish *Channa Punctatus* (Bloch) using micronucleus assay and alkaline single-cell gel electrophoresis. *Food Chem. Toxicol.* 48: 202-208.
- Oh HS, Lee SK, Kim YH, Roh JK (1991). Mechanism of selective toxicity of diazinon to killifish (*Oryzias latipes*) and loach (*Misgurnus anguillicaudatus*). *Aquat. Toxicol. Risk Assess.* 14: 343-353.
- Olurin K, Olojo E, Mbaka G, Akindede A (2006). Histopathological responses of the gill and liver tissues of *Clarias gariepinus* fingerlings to the herbicide, glyphosate. *Afr. J. Biotechnol.* 5:2480-2487.
- Pandey S, Kumar R, Sharma S, Napure NS, Srivastava SK, Verma MS (2005). Acute toxicity bioassays of mercuric chloride and malathion on air-breathing fish *Channa punctatus* (Bloch). *Ecotoxicol. Environ. Saf.* 61:114-120.
- Peter JV, Cherian AM (2000). Organic insecticides. *Anaesth. Intensive Care* 28:11-21.

- Rauf A, Arain N (2013). Acute toxicity of diazinon and its effects on haematological parameters in the Indian carp, *Cirrhinus mrigala* (Hamilton). Turk. J. Vet. Anim. Sci. 37:535-540.
- Roberts RJ (2001). Fish Pathology. Third Edition. Bailliere Tindall, London.
- Santos LH, Araujo AN, Fachini A, Pena A, Deleure-Matos C, Montenegro MCB (2010). Ecotoxicological aspects related to the presence of pharmaceuticals in the aquatic environment. J. Hazard Mat. 175:45-95.
- Sevgiler Y, Uner N (2010). Tissue-Specific effects of fenthion on glutathione metabolism modulated by NAC and BSO in *Oreochromis niloticus*. Drug Chem. Toxicol. 33(4):348-356.
- Sprague JB (1971). Measurement of pollutant toxicity to fish. I. Bioassay methods for acute toxicity. Water Res. 3:793-821.
- Wu JC, Hseu YC, Tsai JS, Chen LC, Chye SM, Chingchen S (2011). Fenthion and terbufos induce DNA damage, the expression of tumor-related genes and apoptosis in HEPG2 cells. Environ. Mol. Mutag. 52(7):529-537.
- Yang I, Zha J, Li W, Li Z, Wang Z (2010). Atrazine affects kidney and adrenal hormones (AHs) related genes expressions of rare minnow (*Gobiocypris rarus*). Aquat. Toxicol. 97:204-211.