

Full Length Research Paper

Effects of artemether on the plasma and urine concentrations of some electrolytes in rats

R.O. Akomolafe^{1*}, I.O. Adeosun¹, J.B. Fakunle², E.O. Iwalewa³, A.O. Ayoka¹, O.E. Ajayi¹, O.M. Odeleye⁴ and B.O. Akanji⁵

¹Department of Physiological Sciences, Obafemi Awolowo University, Ile-Ife, Nigeria.

²Department of Chemical Pathology, Obafemi Awolowo University, Ile-Ife, Nigeria.

³Department of Pharmacology, Obafemi Awolowo University, Ile-Ife, Nigeria.

⁴Department of Pharmacognosy, Obafemi Awolowo University, Ile-Ife, Nigeria.

⁵Department of Chemical Pathology, Obafemi Awolowo University Teaching Hospital Complex, Ile-Ife, Nigeria.

Accepted 24 March, 2011

This study was carried out to determine the changes in the urine levels of sodium (Na⁺), potassium (K⁺), and calcium (Ca²⁺) of rats during a week of intramuscular administration of artemether (12.5 to 50.0 mg/kg/day), another one week thereafter and their concentrations in the plasma at the end of the study. At 12.5 and 25.0 mg/kg of artemether, urine Na⁺ concentration was significantly increased throughout the study ($p < 0.05$), except on Day 7 (at 12.5 mg/kg) and Day 11 (at 25.0 mg/kg), when it was not significantly different from the control. At 12.5 mg/kg of the drug, urine K⁺ concentration was significantly increased throughout the study ($p < 0.05$). Artemether caused no significant changes in urine Ca²⁺ concentration in the control rats as well as those that received 12.5 and 25.0 mg/kg of artemether. Progressive and significant reductions in the urine concentrations of all the electrolytes at 50.0 mg/kg of artemether were observed. Their concentrations in the plasma were also significantly reduced at this dose of the drug. A dose-dependent degeneration of the renal tissue of all the experimental rats was also observed. We concluded that high doses of artemether caused progressive degeneration of the renal tissue of rats, inability of the damaged kidneys to concentrate urine, which manifested as excessive water loss and electrolyte depletion.

Key words: Artemether, electrolytes in plasma, urine concentrations, rats.

INTRODUCTION

Artemether, one of the derivatives of artemisinin, is reputed for its efficacy in the treatment of malaria, including those resulting from infection by chloroquine-resistant strains of plasmodium (Qinghaosu antimalarial coordinating research group, 1979; China cooperative research group on Qinghaosu and its derivatives as anti-malarials, 1982). Though in combination with other anti-malarials, it is gaining ground as one of the first lines of treatment of cerebral malaria caused by chloroquine-resistant plasmodium (Van Vugt et al., 1999; Nosten et al., 2000). It has been reported that intramuscular administration of multiple doses of the drug to dogs, rats and rhesus monkeys produced neurotoxic effects such as

gait disturbances, loss of spinal and pain reflexes (Petras et al., 1997; Sumalee et al., 1997; Nontprasert et al., 1998; 2000; Xiao et al., 2002). High doses of artemether were also reported to have caused neuronal necrosis in the region of the brainstem of rats (Raymond et al., 1998; Xiao et al., 2002). Anorexia and a dose-dependent reduction in body weight have also been reported at these high doses (Qigui et al., 1998). We have studied the changes in some of the visceral functions of Wistar rats following one week of intramuscular administration of 12.5 to 50.0 mg/kg of artemether (Akomolafe et al., 2006). We reported a pattern of anorexia which manifested as a significant reduction in the food and water intake of all the treated rats. This was accompanied by significant increases in their urine output. These effects persisted until even one week after the stoppage of drug administration in those rats that received 50.0

*Corresponding author. E-mail: rufakom@yahoo.co.uk.

mg/kg of the drug, whereas those that received lower doses had only their food intake restored during this period (Akamolafe et al., 2006). We concluded that the significant increase in urine output without a corresponding increase in the water intake of the rats could exacerbate dehydration and lead to a deleterious effect on the ionic balance of the body fluid of the rats (Akamolafe et al., 2006). We also postulated that high doses of artemether could cause impaired renal function of the treated rats and that the significant increase in urine output could be due to other effects of the drug on thirst, anti-diuretic hormone output and the osmotic pressure of their blood (Akamolafe et al., 2006). The plasma levels of some electrolytes namely sodium (Na^+), potassium (K^+), and calcium (Ca^{2+}) are very important for the proper functioning of the neuromuscular and cardiovascular systems (Guyton and Hall, 2001; Ganong, 2003). Excessive loss of these ions from the body through urine stool or sweat could have serious deleterious effects on these two systems likewise their excessive retention (Guyton and Hall, 2001; Ganong, 2003). There is a dearth of information on the influence of artemether on the plasma and urine levels of these important electrolytes of the body fluid in laboratory animals, especially rats. This study was carried out to determine the effects of artemether on the plasma and urine levels of Na^+ , K^+ , and Ca^{2+} of rats with a view to shedding more light on its toxicity in their body fluid and renal tissue.

MATERIALS AND METHODS

Experimental animals

Eighty adult Wistar rats (200 to 250 g) were used for this study. The rats were obtained from the Animal Holding of the Department of Physiological Sciences, Obafemi Awolowo University, Ile-Ife, Nigeria. They were kept in the laboratory under natural light/dark cycle and were fed on normal mouse cubes (Ladokun feeds, Ibadan, Nigeria) and water. The rats were divided into four groups labeled I, II, III and IV. Each of the groups consisted of twenty rats, ten males and ten females. Each of the rats was housed in a separate metabolic cage (Ohaus R Model; Ohaus, Pine Brook, NJ, USA) with access to food and water *ad libitum*. The rats were acclimatized for 2 weeks before the commencement of the experiments.

Drug administration

Injectable form of artemether (80 mg/ml) manufactured by Kunming Pharmaceutical Factory, Kunming, People's Republic of China) was dispensed in 1 ml ampoules for intramuscular injection.

Dose regimens

Each rat in Group I that weighed 250 g was given 0.16 ml of normal saline (equivalent to the volume of the drug that was administered to each 250 g rat that received 50.0 mg/kg/day) for 1 week. This group served as the control. Each of the rats in Groups II, III and IV

received 12.5, 25.0 and 50.0 mg/kg/day of artemether respectively via the intramuscular route for 1 week.

Urine samples were collected into clean specimen bottles for 24 h on the day before the commencement of drug administration and this was taken as the Day 0 urine for each of the rats. This procedure was repeated for Days 3, 7, 11 and 14 of the study, that is, one week of drug administration and another one week later. The concentrations of Na^+ , K^+ and Ca^{2+} in the samples were measured. The urine concentrations of Na^+ and K^+ were determined by Flame Photometry using Coming 410C Flame Photometer. The Ca^{2+} level was measured using Cresolphthalein Complexone method (Burtis and Ashwood, 2001).

On Day 14, the rats were sacrificed under chloroform anaesthesia. A midline incision was made with a surgical blade to expose the abdominal organs. Blood was collected from the hearts of the rats by cardiac puncture and delivered into lithium heparinized specimen bottle. A new syringe was used for the collection of blood from each rat; the blood was immediately centrifuged at 3000 revolutions per minute for 20 min. The plasma was thereafter separated into a specimen bottle in readiness for analysis. The concentrations of Na^+ , K^+ , and Ca^{2+} in the samples were determined using the same methods that were used in the analysis of urine.

The rats kidneys were dissected out and kept inside 10% formalin until their sections were cut and stained with eosin and hematoxylin for histological studies. Photomicrographs of the tissues were taken using Lect₃ Dialux Microscope (Bright Field) at $\times 40$ magnification.

Statistical analysis

The results were expressed as mean \pm SEM and subjected to one-way analysis of variance (ANOVA). Significant differences were further tested by the Duncan's Multiple Range and Student Neuman Keuls tests. Student's t-test was used to compare the urine concentration of the electrolyte for each day with the Day 0 value for each group. Differences with probability values of $p < 0.05$ were considered significant.

RESULTS

Effect of artemether on urine concentration of electrolytes

Sodium (Na^+): Throughout the study, there was no significant change in the concentration of Na^+ in the urine of the control rats (Figure 1). At 12.5 and 25.0 mg/kg, urine Na^+ concentration was significantly higher than the Day 0 value and the control rats throughout the study ($p < 0.05$), except on Day 7 (at 12.5 mg/kg) and Day 11 (at 25.0 mg/kg), when it was not significantly different from these values. At 50.0 mg/kg, the urine Na^+ concentration decreased gradually and significantly throughout the study ($p < 0.05$).

Potassium (K^+): The K^+ concentration in the urine of the control rats did not vary significantly throughout the study (Figure 2). At 12.5 mg/kg, K^+ concentration in the urine was significantly higher than that of the control rats and that of the Day 0 value throughout the study ($p < 0.05$). At 25.0 mg/kg, there was no significant change in K^+

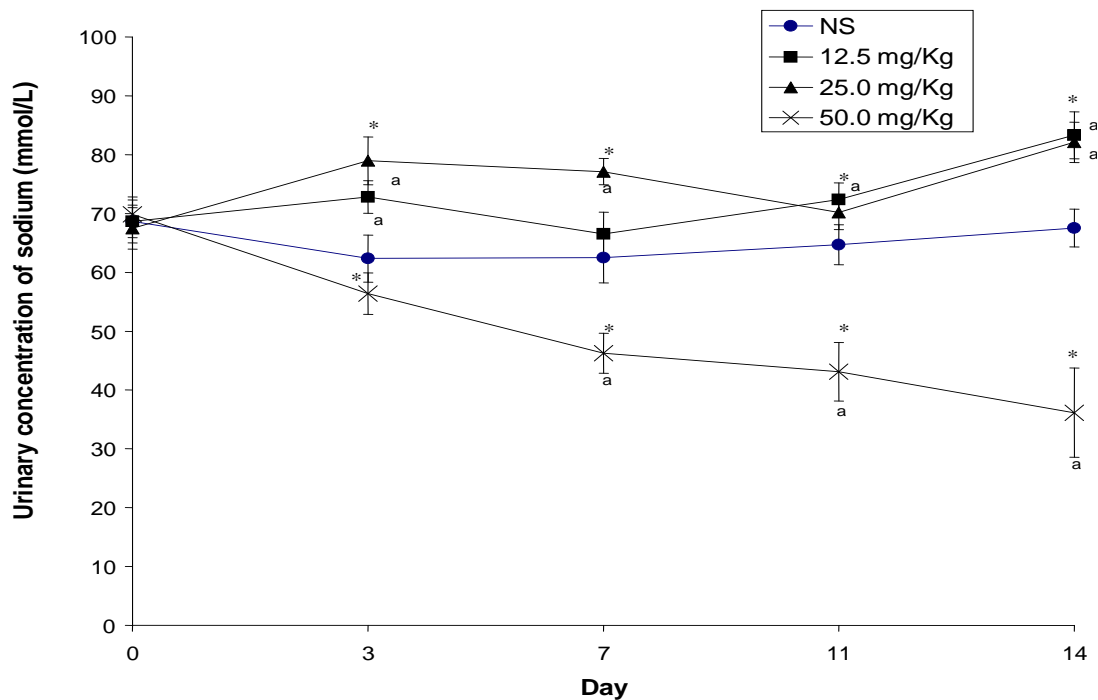


Figure 1. Variation in the urine concentration of sodium due to a week of intramuscular administration of artemether to rats. Each point is mean \pm SEM (n = 20). *, Significantly different from the Day 0 value ($p < 0.05$); a, significantly different from control (NS) ($p < 0.05$).

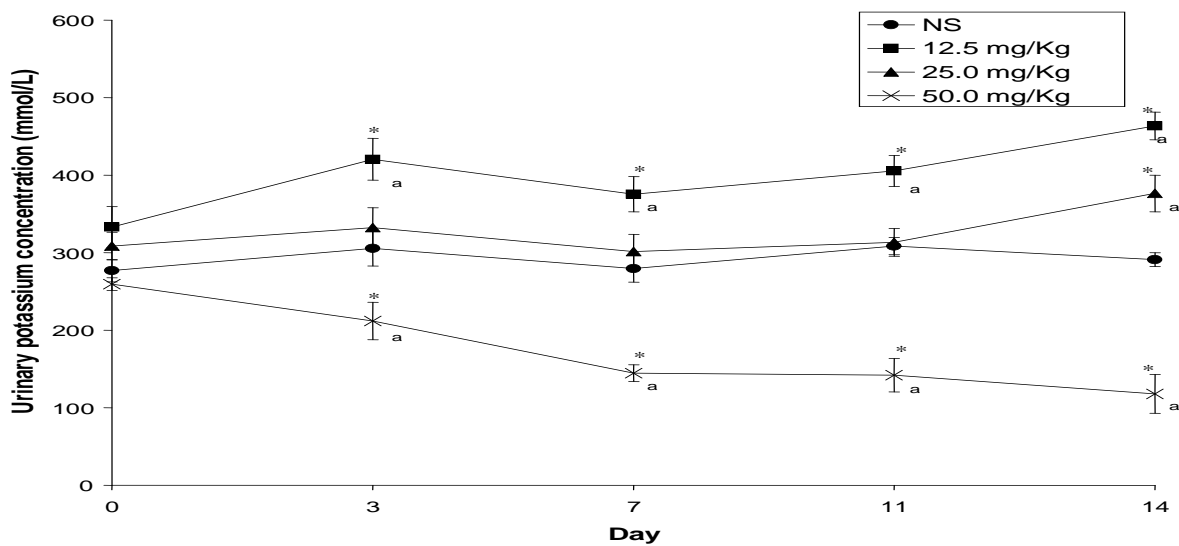


Figure 2. Variation in the urine concentration of potassium due to a week of intramuscular administration of artemether to rats. Each point is mean \pm SEM. (n = 20). *, Significantly different from the Day 0 value ($p < 0.05$). a, significantly different from control (NS) ($p < 0.05$).

concentration throughout the study. At 50.0 mg/kg, the K^+ concentration decreased gradually and significantly throughout the study ($p < 0.05$).

Calcium (Ca^{2+}): No significant change in urine Ca^{2+}

concentration was observed in the control rats as well as those that received 12.5 and 25.0 mg/kg of artemether, throughout the study (Figure 3). At 50.0 mg/kg, urine Ca^{2+} concentration was significantly reduced throughout the study ($p < 0.05$).

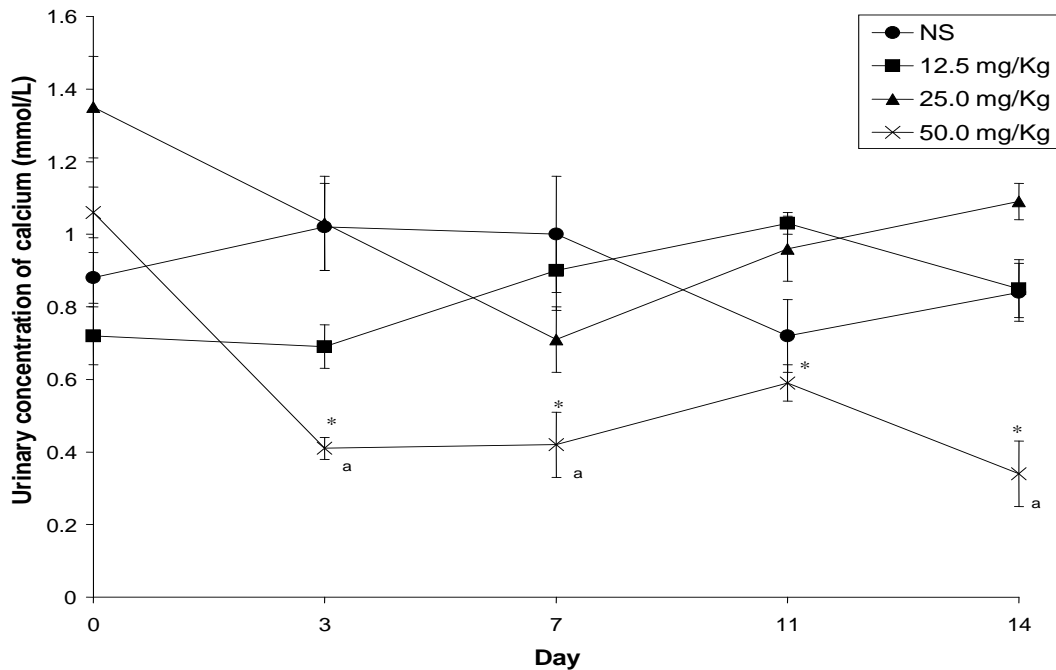


Figure 3. Variation in the urine concentration of calcium due to a week of intramuscular administration of artemether to rats. Each point is mean \pm SE (n = 20). *, Significantly different from the Day 0 value (p < 0.05). a, significantly different from control (NS) (p < 0.05)

DISCUSSION

This study showed a dose-dependent degeneration of the renal tissue of the rats under the influence of high doses of artemether (Plates 1 to 4). Chemical compounds which furnish oxygen based radicals are reputed for their cell membrane lipid peroxidation properties. Lipid peroxidation refers to the oxidative degradation of lipids. It is the process whereby free radicals take electrons away from lipids in cell membranes, resulting in cell damage. The endoperoxide bridge in artemether molecule produces free radicals which are responsible for the lipid peroxidation properties of the drug (Goodman and Gilman, 1985; Meshnick, et al., 1991, 1993; Maeno et al., 1993). The degenerative changes observed in the renal tissue of the treated rats could be attributed to the destruction of the membrane of the renal tubular cells of the rats by the free radicals produced by the drug.

Analysis of the urine of the rats for electrolytes revealed a progressive and significant reduction in the concentration of the electrolytes at 50.0 mg/kg of artemether. This indicated that the rats that received this dose of artemether produced more dilute urine with each passing day of the study, despite the anorexia induced by the drug. Inability of the kidney to concentrate or dilute the urine is one of the features of damaged nephrons (Leaf and Cotran, 1980; Neiman, and Lorenz, 1989; Guyton and Hall, 2001; Dunn, 2003; Ganong, 2003). Rapid tubular flow occurs in the remaining nephrons of the diseased kidneys. The renal tubules lose their ability to

concentrate or dilute the urine (Guyton and Hall, 2001). This study indicated that high doses of artemether are toxic to the renal tissue of the rats. We have earlier reported a significant increase in the volume of the urine produced by rats that received 50.0 mg/kg of artemether, during treatment and even one week post-treatment, without a corresponding increase in their food and water intake for the same period (Akamolafe et al., 2006). The excessive fluid loss of rats that received this dose of artemether could lead to dehydration and a severe depletion of the major electrolytes of their body fluid. The photomicrograph of the kidney of rats that were given this dose of artemether showed a very high degree of tissue degeneration. The continuous significant decreases in the urine concentration of the electrolytes could not have been due to increased reabsorption of the electrolytes by the renal tubules, but rather to the artemether-induced anorexia and the excessive water loss that usually accompanies increased electrolyte loss in urine (osmotic diuresis).

Throughout the study, there was no significant change in the concentration of Na^+ in the urine of the control rats (Figure 1). This is an indication that the kidney function of the rats was not impaired, as evidenced by the photomicrograph of their kidneys (Plate 1). At 12.5 and 25.0 mg/kg, urine Na^+ concentration was significantly higher than the Day 0 and control values throughout the study (p < 0.05), except on Day 7 (at 12.5 mg/kg) and Day 11 (at 25.0 mg/kg), when it was not significantly different from these values. Our earlier report indicated that rats that

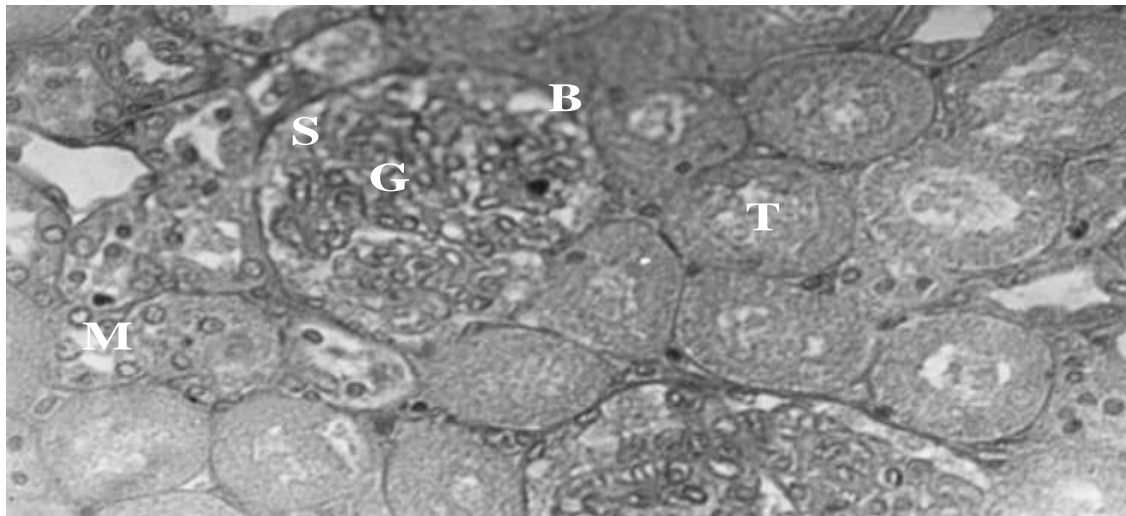


Plate 1: Photomicrograph of the kidney of rats that received normal saline i.m. for 7 days (Control 1 rats). Mag x 400. The kidney tissue shows no pathological changes, as reflected by the Bowman's capsule (B), the glomerulus (G), renal tubules (T) and other cells of the renal tissue. The glomerulus (G) and the capsular space (S) are distinct and intact. The tubules retain their normal shapes and the tubular cells have well defined boundaries, and nuclei. The mesangial cells (M) are normal in size shape and number.

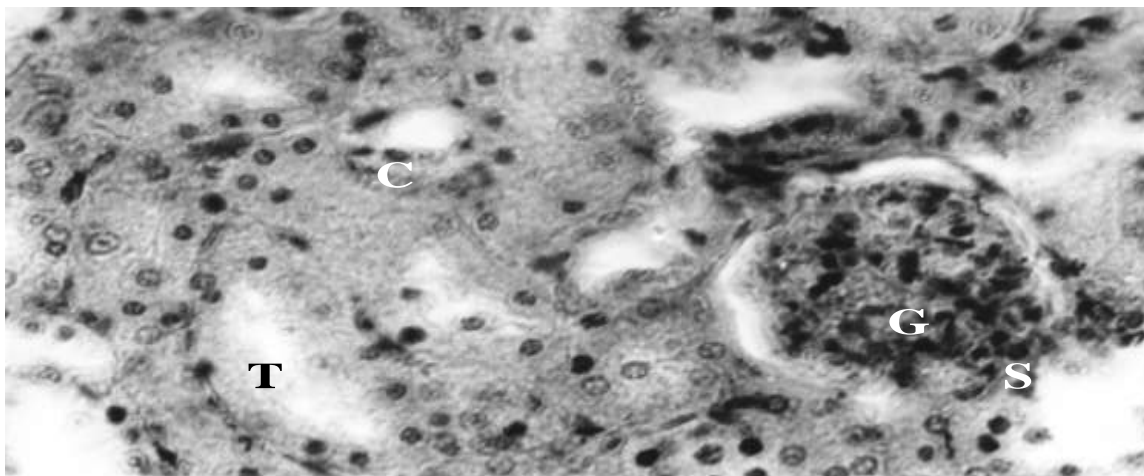


Plate 2. Photomicrograph of the kidney of rats that received 12.5 mg/kg of artemether i.m. for 7 days. Magx400. The glomerulus (G) has expanded to the extent of almost closing the capsular space(S). The tubular cells (C) are densely stained. The tubules (T) have started losing their integrity as reflected in the distortion of their shape.

received 25.0 mg/kg of artemether had significantly increased urine output which lasted for even a week after treatment, without a corresponding increase in food and water intake, most especially during treatment (Akomolafe et al., 2006).

The significant increase in urine Na^+ concentration at 25.0 mg/kg of artemether is an evidence of dehydration induced by the drug. The integrity of the nephrons of the rats had been severely compromised as revealed by Plate 3. The significant increase in urine Na^+ concentration at this dose of the drug could also be a reflection of excessive sodium loss by the damaged

kidneys of the rats.

The K^+ concentration in the urine of the control rats did not vary significantly throughout the study (Figure 2). At 12.5 mg/kg, K^+ concentration in the urine was significantly higher than the control and Day 0 values throughout the study ($p < 0.05$). At 25.0 mg/kg, there was no significant change in K^+ concentration throughout the study. Potassium, once absorbed by the intestinal tract, is partially removed from the plasma by glomerular filtration and is then nearly completely reabsorbed in the proximal tubule. Unlike sodium, it is effectively re-excreted by the distal tubules. There is no threshold level for K^+ (Guyton

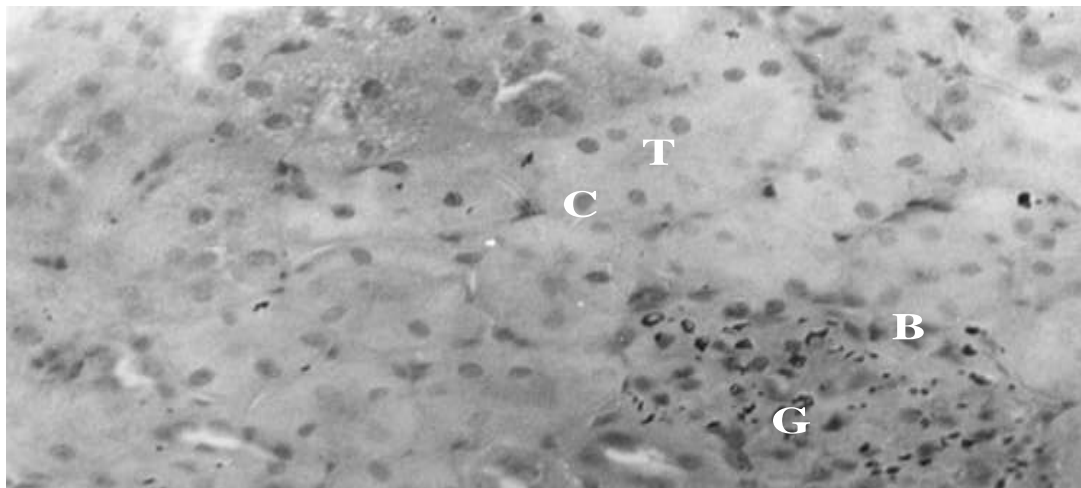


Plate 3. Photomicrograph of the kidney of rats that received 25.0 mg/kg of artemether, i.m. for 7 days. Mag×400. The Bowman's capsule (B) started breaking down. The glomerulus (G) has undergone degeneration. The capsular space (C) has been completely obliterated. The tubular cells (S) are still densely stained. The tubules (T) have lost much of their integrity as their boundaries are no more well defined. The intertubular space (P) are almost completely closed due to inflammation of the tubules.

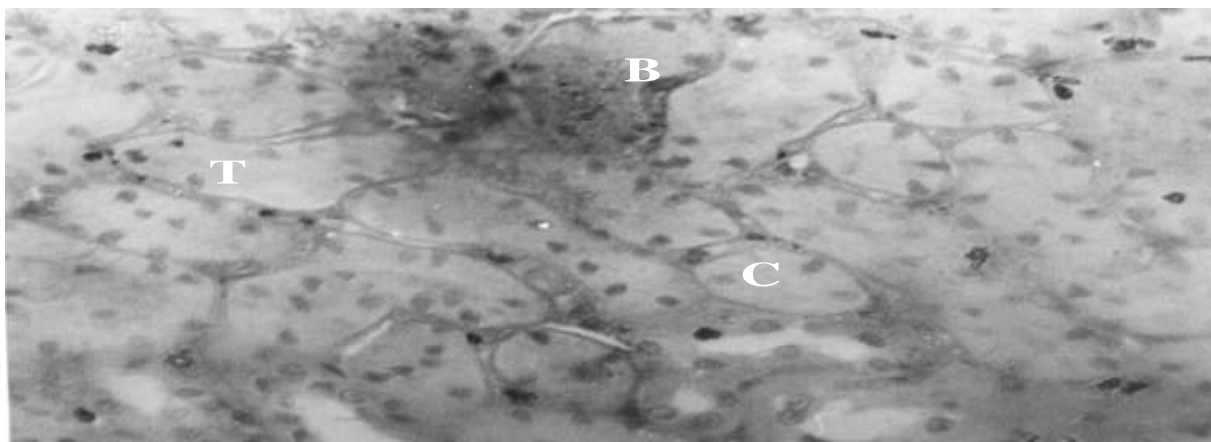


Plate 4. Photomicrograph of the kidney of rats that received 50.0 mg/kg of artemether i.m. for 7 days. Mag×400. The Bowman capsule (B) is almost non-existent due to degeneration. The densely stained tubular cells (C) are still observable, though the tubular integrity (T) has been grossly distorted as a result of inflammation and degenerative changes.

and 25.0mg/kg of artemether in this study could be attributed to the differences in the renal handling of the two electrolytes. Potassium is mainly an intracellular electrolyte. The damaged renal tissue could also be a source for additional K^+ in the body fluid of the rats.

Artemether caused no significant change in urine Ca^{2+} concentration in the control rats as well as those that received 12.5 and 25.0 mg/kg of artemether, throughout the study (Figure 3). It could be due to the fact that artemether does not have any appreciable effects on renal Ca^{2+} excretion at these doses of the drug. However, this needs further verification.

The plasma Na^+ concentration was significantly increased at 25.0 mg/kg of artemether only ($p < 0.05$) (Figure

4). This is in conformity with the observed significant elevation of the urine concentration of this electrolyte in rats that received this dose of artemether. The significantly increased Na^+ concentration in the plasma of rats that received 25.0 mg/kg of the drug could be due to the same reasons given for the elevated urine level of the electrolyte. The reductions observed at 12.5 and 50.0 mg/kg of the drug were not significant. The plasma K^+ concentration increased significantly at all the doses of artemether studied, except at 50.0 mg/kg where it was significantly reduced (Figure 5). The significant increase in the plasma concentrations of this electrolyte at lower doses of artemether could be as a result of the drug-induced renal tissue damage at these doses, while the

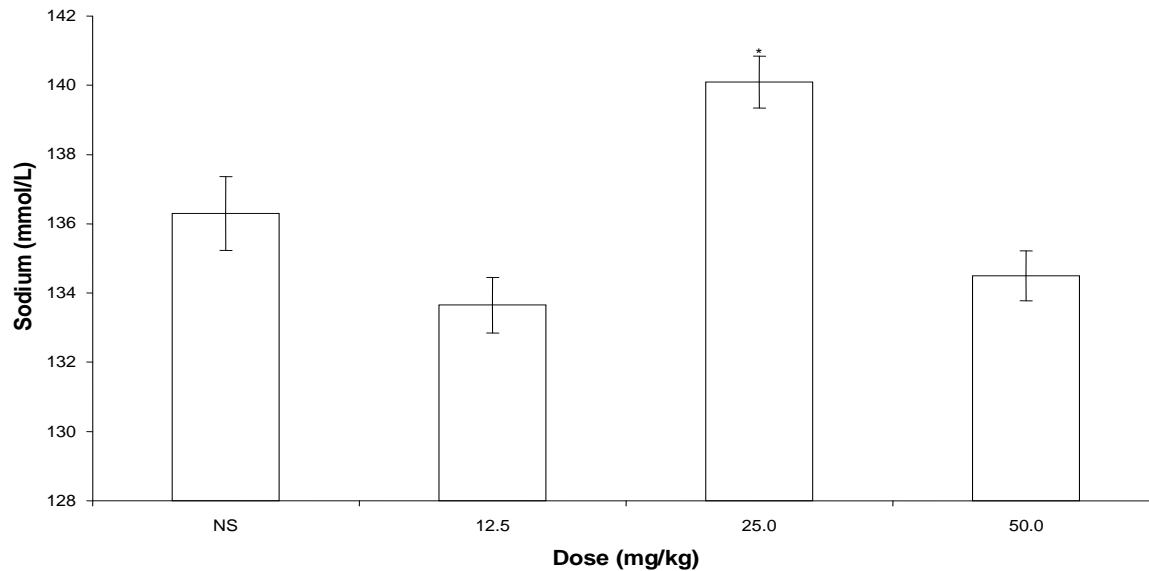


Figure 4. Effect of artemether on the plasma sodium concentration of rats. *Significantly different from control ($p < 0.05$). The plasma Na^+ concentration was significantly increased at 25.0 mg/kg of artemether only ($p < 0.05$). The reduction observed at 12.5 and 50.0 mg/kg of the drug was not significant.

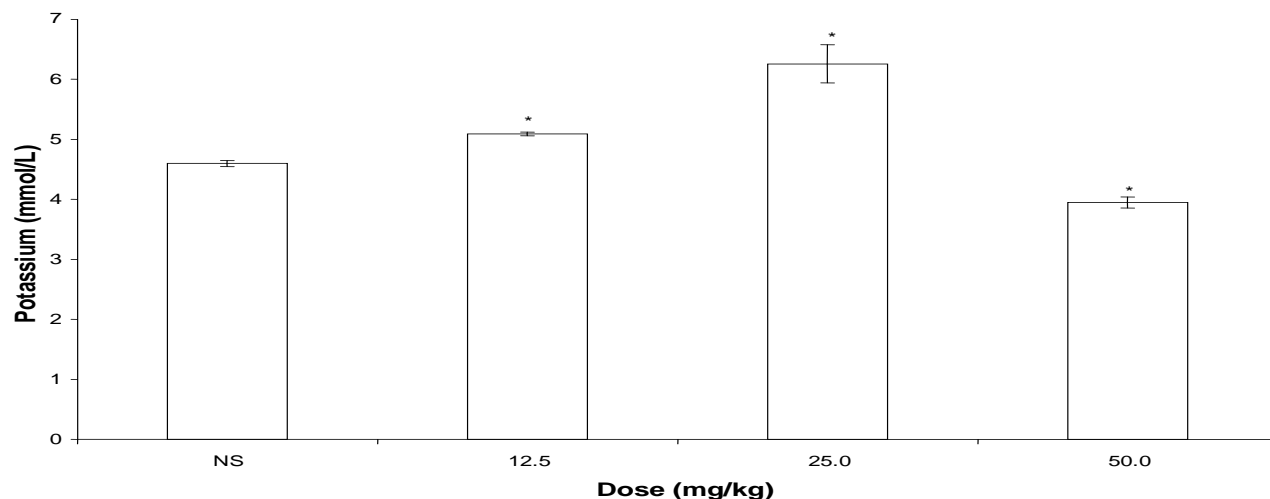


Figure 5. Effect of artemether on the plasma potassium concentration of rats. *Significantly different from control ($p < 0.05$). The plasma K^+ concentration increased significantly at all the doses of artemether studied, except at 50.0 mg/kg where it was significantly reduced.

significant decrease at 50.0 mg/kg could be attributed to the earlier reported sustained significant reduction in food consumption, increased urine output, as well as much degeneration of the nephrons induced by artemether. There was no significant difference in the plasma Ca^{2+} level of the control rats and those that received 12.5 and 25.0 mg/kg of artemether (Figure 6). This is an indication that, at these doses of artemether, calcium excretion was not adversely affected by the renal tubular damage induced by the drug. However, a significant decrease in

the plasma level of this electrolyte was observed at 50.0 mg/kg of the drug.

Conclusion

High doses of artemether caused progressive degeneration of the renal tissue, inability of the nephrons to concentrate urine, excessive water loss and electrolyte depletion in rats.

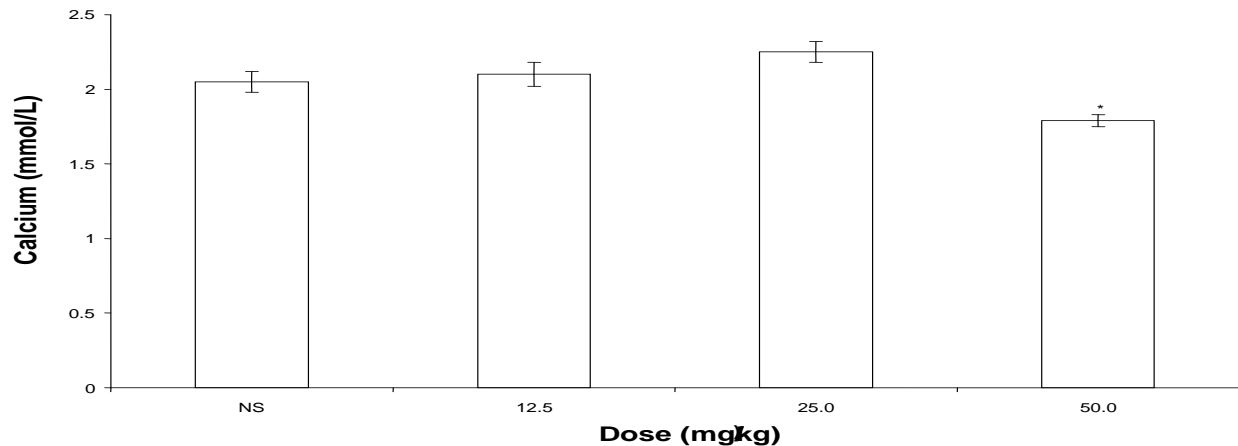


Figure 6. Effect of artemether on the plasma calcium concentration of rats. *Significantly different from control ($p < 0.05$). There was no significant difference in the plasma Ca^{2+} level of the control rats and those that received 12.5 and 25.0 mg/kg of artemether. At 50.0 mg/kg, plasma Ca^{2+} decreased significantly.

ACKNOWLEDGMENTS

We are grateful to Obafemi Awolowo University, Ile-Ife for financing this study and to Mr. J.A. Ibeh, of the Department of Anatomy and Cell Biology, and Messrs T. A. Ogundoyin, F. A. Abidoye, C. O. Ola, R. T. Olatoye, and A. E. Adebisi of the Department of Physiological Sciences for their technical assistance in the process of carrying out this research work

REFERENCES

- Akomolafe RO, Adeosun IO, Fakunle JB, Iwalewa EO, Ayoka AO, Akanji BO, (2006). Changes in the visceral functions of plasmodium-infected and uninfected rats following administration of artemether. *Clin. Exp. Pharmacol. Physiol.* 33: 1180-1183
- Burtis CA, Ashwood ER (2001). *Tietz fundamentals of clinical chemistry*. W.B. Saunders Co. Philadelphia USA. pp. 598-640.
- China Cooperative Research Group on Qinghaosu and its Derivatives as Antimalarials (1982). Studies on the toxicity of qinghaosu and its derivatives. *J. Trad. Chin. Med.* 2: 31-38
- Dunn (2003). Kidney failure in Dogs and Cats. A publication of the pet center. *Internet Anim. Hospital*, pp. 22-28.
- Ganong (2003). *Review of medical physiology* 21st Edition. Lange Medical Books/Mc Graw Hill, pp. 701-733.
- Goodman LS, Gilman A (eds) (1985). *The Pharmacological Basis of Therapeutics* 8th Ed. Macmillan co. Inc. New York. pp. 118-125.
- Guyton AC, Hall J E (2001). *Textbook of Medical Physiology*. Tenth Edition. Harcourt International Edition. Published by W.B. Saunders Company, Philadelphia, Pennsylvania, pp. 377-455.
- Leaf A, Cotran BS (1980). *Renal pathophysiology* 2nd edition New York: Oxford University Press, pp. 95-98.
- Maeno Y, Toyoshima T, Fujidra H, Ho K, Meshnick SR, Benakis A, Milhou WK, Aikawa M (1993). Morphological effects of artemisinin in *Plasmodium falciparum*. *Am. J. Trop. Med. Hyg.* 49: pp. 485-491.
- Meshnick SR, Thomas A, Ranz Xu, CM Pan H (1991). Artemisinin (qinghaosu): the role of intracellular hemozoin in its mechanism of antimalarial action. *Mol. Biochem. Parasitol.* 49: 181-190.
- Meshnick SR, Yang YZ, Lima V, Kuypers F, Kamchonwongpaisan S, Yuthavong Y (1993). Iron-dependent free radical generation and the antimalarial artemisinin (qinghaosu). *Antimicrobial Agents Chemother.* 37: 1108-1114.
- Neinman LI, Lorenz JM (1989). Physiology and pathophysiology of body water and electrolytes. In: Kaplan LA, Peace AJ, Eds *clinical chemistry; Theory, Analysis and correlation* St. Louis, Mosby-Year Book pp. 114-123.
- Nontprasert A, Norsten-Bertrand M, Pukrittayakamee S, Vanijanonta S, Angus BJ, White NJ (1998). Assessment of the neurotoxicity of parenteral artemisinin derivatives in mice. *Am. J. Trop. Med. Hyg.* 59: 519-522.
- Nontprasert A, Sasithon P, Marika N, Sirivan V, Nicholas JW, 2000. studies of the neurotoxicity of oral artemisinin derivatives in mice. *Am. J. Trop. Med. Hyg.* 62(3): 409-412.
- Petras JM, Kyle DE, Gettayacamin M, Young GD, Bauman RA, Webster HK, Corcoran KD, Peggins JD, Vane MA, Brewer TG (1997). Arteether; Risk of two-week administration of Macaca mulatta. *Am. J. Trop. Med. Hyg.* pp. 390-396
- Qigui L, Thomas GB, James OP (1998). Anorexic toxicity of dihydroartemisinin, artemether, and arteether in rats following multiple intramuscular doses. *Int. J. Toxicol.* 17: 663-676
- Qinghaosu Antimalarial Coordinating Research Group (1979). antimalarial studies on qinghaosu. *Chin. Med. J.* 92: 811-816
- Qinghaosu Antimalarial Coordinating Research Group, Haiman Island (1979). Observations on the clinical effect of qinghaosu in the treatment of chloroquine-resistant malaria. *J. Nat. Drug.* 9: 12-16.
- Nosten F, Van Vugt M, Prince R, Luxemburger C, Thyway KL, Brockman A, McGready R, Kuile F, Looareesuwan S, White NJ (2000). Effects of artesimate-mefloquine combination on incidence of plasmodium falciparum malaria and mefloquine resistance in Western Thailand; A prospective study. *Lancet.* 356: 297-302.
- Raymond GG, Donald BN, Qigui Li JO, Thomas JB (1998). Dose-dependent brainstem neuropathology following repeated arteether administration in rats. *Brain Res. Bull.* 45 (2): 199-202
- Sumalee K, Paul M, Paul H, Herman Z, Steven RM (1997). Artemisinin neurotoxicity: Neuropathology in rats and mechanistic studies in vitro. *Am. J. Trop. Med. Hyg.* 56(1): 7-12
- Van Vugt M, Wilairatana P, Gemperti B, Gathman I, Phaipum L, Brockman A, Luxemburger C, White NJ, Nosten F, Looareesuwan S (1999). Efficacy of six doses of artemether-lumefantrine (Benflumetol) in multidrug-resistant plasmodium falciparum malaria. *Am. J. Trop. Med. Hyg.* 60(6): 736-942.
- Xiao S, Yang Y, You Q, Utzinger J, Guo H, Peiying J, Mei J, Guo J, Bergquit R, Tanner M (2002). Potential long-term toxicity of repeated orally administered doses of artemether in rats. *Am. J. Trop. Med. Hyg.* 66(1): 30-34.