

Full Length Research Paper

# Single nucleotide substitution mutations and polymorphisms in *ECM1* gene in lipoid proteinosis in siblings of a Pakistani family

Syed M. Shahid<sup>1\*</sup>, Abid Azhar<sup>1</sup>, Syeda N. Nawab<sup>1</sup>, Rozeena Shaikh<sup>1</sup>, Muhammad Ismail<sup>2</sup> and Azam J. Samdani<sup>3</sup>

<sup>1</sup>The Karachi Institute of Biotechnology and Genetic Engineering (KIBGE), University of Karachi, Karachi, Pakistan.

<sup>2</sup>Institute of Biomedical and Genetic Engineering (IBGE), Islamabad, Pakistan.

<sup>3</sup>Department of Dermatology, Jinnah Postgraduate Medical Center, Karachi, Pakistan.

Accepted 7 July, 2011

A number of mutations in extracellular matrix protein 1 (*ECM1*) that is a glycoprotein and expressed in skin and other tissues are reported to cause a rare, autosomal recessive disorder called *lipoid proteinosis* (LP). The peculiar manifestation of LP is hoarseness of voice caused by laryngeal infiltration in infancy. Skin and mucous membrane changes clinically become apparent, and the disease typically follows a slowly progressive, yet often benign, course. About 300 cases of LP have been reported, but occurrence in siblings is rare. In this study, two siblings (18 and 24-year-old) of a Pakistani family were reported to have LP. This study presents two brothers with scaly itchy lesions on whole body, hoarse voice and macroglossia. Their deceased father had similar clinical manifestations but mother, younger brother and sister were unaffected. Blood from affected and clinically unaffected family members were collected with informed consent. The *ECM1* gene containing 10 exons were amplified and sequenced. Both patients showed non-pathogenic missense and silent mutations in exon 6 and 8. In exon 6, a nucleotide C was substituted to T (C→T) at codon 2, in patient 1. This non-pathogenic missense mutation causes appearance of amino acid cysteine instead of arginine that is part of normal *ECM1* protein. In patient 2, polymorphism of nucleotide C to T (C/T) was observed in exon 6 that may lead to the appearance of cysteine and/or arginine in the resulting gene product. In exon 8, a nucleotide G was substituted to A (G→A) at codon 53, in patient 1. This substitution leads to a silent mutation as serine is coded by both forms of codon. In patient 2, polymorphism of nucleotide G to A (G/A) was observed in exon 8 that do not cause any change in the coded amino acid. These findings represent a set of missense and silent mutations supporting an unusual function of *ECM1* protein, broadening the spectrum of disease-linked mutations in rare cases of LP.

**Key words:** Lipoid proteinosis, extracellular matrix protein 1 (*ECM1*), missense, silent mutation, single nucleotide polymorphism, exons 6 and 8, genodermatosis.

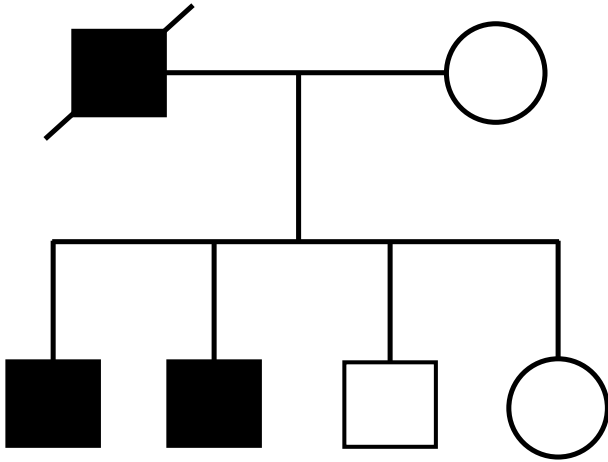
## INTRODUCTION

Lipoid proteinosis (LP) is a rare autosomal recessive

genodermatosis which is characterized by deposition of an amorphous hyaline material in skin, mucosa and viscera. LP is also known as *hyalinosis cutis et mucosae* or Urbach-Wiethe disease (OMIM: 24700) which was first described by Urbach and Wiethe (1929). The peculiar manifestation of LP is onset in infancy with hoarseness of voice caused by laryngeal infiltration. Skin and mucous membrane changes clinically become apparent, and the

\*Corresponding author. E-mail: [smshahid@uok.edu.pk](mailto:smshahid@uok.edu.pk).  
Tel:009221-99261180 or 0092300-2759170. Fax: 009221-34823886-7.

**Abbreviation:** LP, Lipoid proteinosis.



**Figure 1.** Family pedigree of the affected and unaffected members. Two sons and deceased father are affected, while the mother, son and only daughter have normal phenotype.

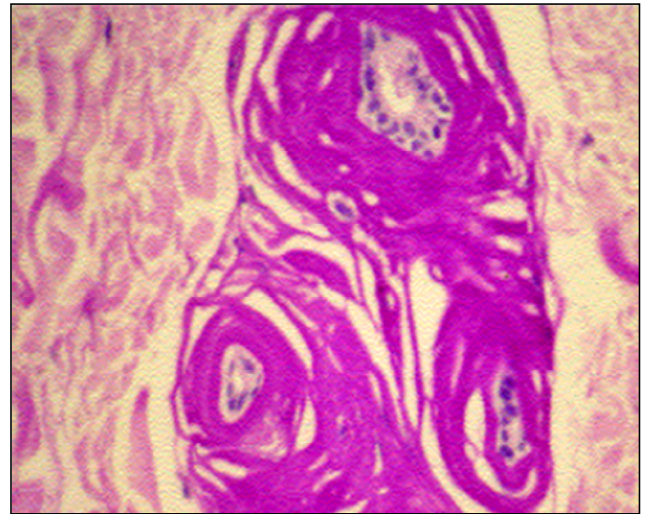
disease typically follows a slowly progressive, yet often benign, course. Virtually, any organ may be involved, but visceral involvement rarely leads to clinically significant consequences. The exceptions are involvement of the central nervous system and respiratory tract, which may result in seizures and airway obstruction, respectively. Lifespan is otherwise normal (Horey et al., 2009; Dyer, 2008).

Lipoid proteinosis has been linked to mutations in the gene encoding extracellular matrix protein 1 (*ECM1*). To date, no effective treatment is known (Chan et al., 2007). The *ECM1* protein has important physiological and biological roles in epidermal differentiation, binding of dermal collagens and proteoglycans, and regulation of angiogenesis. The precise function of *ECM1* is still unknown. Many pathogenic mutations have been reported so far, mostly nonsense, missense or splice site mutations with the majority occurring in exon 6 or 7 of the 10-exon in *ECM1* gene encoding a glycoprotein (Salih et al., 2011). LP is histologically characterized by intercellular deposits of periodic acid Schiff (PAS)-positive hyaline material in the skin, mucous membranes and internal organs. Loss-of-function mutations in the gene encoding *ECM1* on chromosome 1q21.7 have been identified in LP; fewer than 20 variants have been reported, that occurred in siblings rarely.

This study reports an unusual finding of non-pathogenic single nucleotide base substitution mutations in exons 6 and 8 in two brothers of a Pakistani family suffering from LP. The results of this study help to understand the spectrum of genetic variations in this rare case of genodermatosis.

## MATERIALS AND METHODS

Following informed consent and approval from institutional



**Figure 2.** Periodic Acid Schiff (PAS)-diastase staining result showing deposition of PAS-positive and diastase resistant material in skin at the dermal-epidermal junction and surrounding blood vessels in the dermis.

ethical committee two brothers of 18 and 24 years of age suffering from LP, from Karachi, Pakistan were selected for this study. Both patients were presented with scaly itchy lesions on the whole body, hoarse voice and macroglossia. These lesions started at infancy in both brothers. Their hoarseness/ and low pitch voice was so severe that it was difficult to hear them. On examination, they had eczema, with multiple infections and scars on their faces, chest and back. Patients were found to have characteristic features of LP such as multiple beaded papules along the eyelids, fissured lips and slight macroglossia with a hard woody tongue having a homogeneous look. According to their mother, her husband had died almost with similar skin problem and hoarseness, whereas their younger brother and sister were normal (Figure 1).

Routine investigations (Blood CP, SUCCE and LFT) together with abdomen USG and CT scan were normal. However, buccal mucosa biopsy with PAS stain was suggestive of this condition. Skin sections stained with haematoxylin and eosin (H&E) showed widespread deposition of hyaline-like material around blood vessels and adnexal epithelia, and thickening of the basement membrane at the dermal-epidermal junction. On periodic acid-Schiff (PAS) staining and PAS-diastase, these sites were PAS positive and diastase resistant (Figure 2).

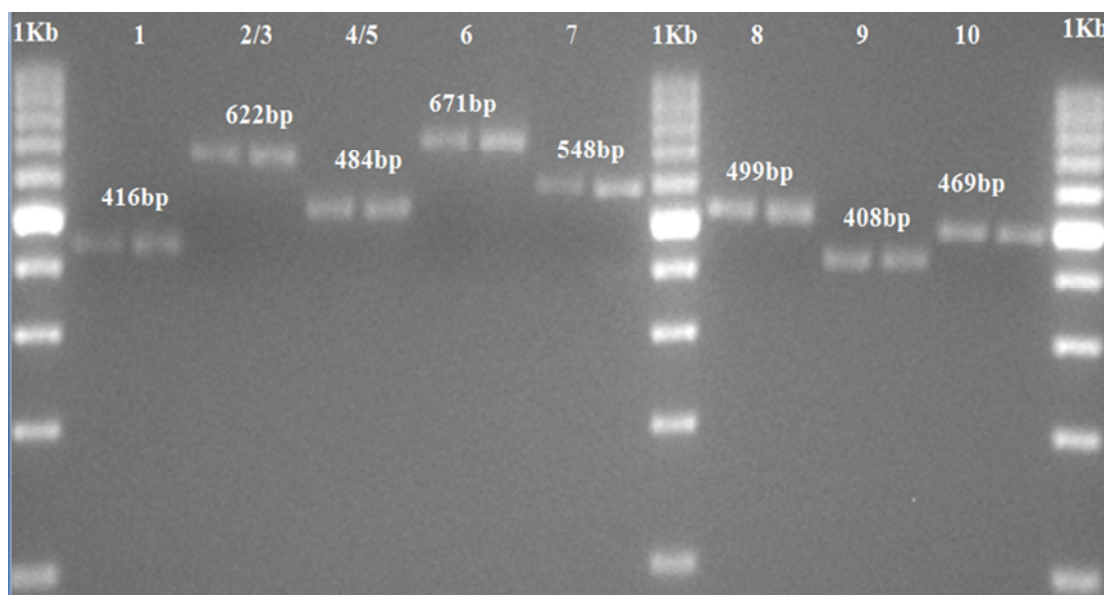
## Detection of mutation in *ECM1* gene

The DNA of the patients and their clinically unaffected family members were extracted from peripheral blood by the standard phenol-chloroform DNA extraction method (Maniatis et al., 1982). Polymerase chain reaction (PCR) amplification of *ECM1* gene was performed using eight pairs primers (forward and reverse) encompassing all 10 exons and situated in flanking introns as described earlier (Hamada et al., 2003) and briefly given in Table 1.

For PCR amplification, the 50  $\mu$ l PCR reaction volume was used containing 1xPCR amplification buffer, 250 ng genomic DNA, 0.6 mM/each primer, 1.5 mM  $MgCl_2$ , 0.2 mM/each dNTPs and 2.5 U Taq DNA polymerase. The amplification was performed by using standard protocol (Hamada et al., 2003; Hougenhouck- Tulleken et al., 2004). The amplifications were performed at 95°C for 5 min, followed by 35 cycles of 95°C for 45 s, primer-specific annealing

**Table 1.** Genomic primers used for PCR amplification of *ECM1*.

<i>ECM1</i> exon	Primer sequence (5'-3')	PCR product size (bp)	Annealing temperature (°C)
<i>ECM1</i> -1F	AGCTGGGACTGAAGTCATGGC	416	62
<i>ECM1</i> -1R	TAAAGGCTCCACTGGCCTAG		
<i>ECM1</i> -2/3F	TCCTACACTCTTGATCTCCA	622	59
<i>ECM1</i> -2/3R	GGTGTCAACAGGATCCATAG		
<i>ECM1</i> -4/5F	CAGTGACCCTCCAGGTTTCT	484	59
<i>ECM1</i> -4/5R	CAGAGCCCACCGTCTTGCT		
<i>ECM1</i> -6F	AGCCTTGAGAAGCAGGAGGA	671	59
<i>ECM1</i> -6R	AGTGAACGGGACCTGAGGTT		
<i>ECM1</i> -7F	TTATCTGCCTGCCAGTGTC	548	59
<i>ECM1</i> -7R	ACATGGATGGATGGACTGGC		
<i>ECM1</i> -8F	CACATCAACAGTTGCCTCCT	499	59
<i>ECM1</i> -8R	GGCATCTTCTGGCATCAGAT		
<i>ECM1</i> -9F	AGTTGCCTAGTCCTTCCCA	408	60
<i>ECM1</i> -9R	AGGCCAGGTCAGAGTGAAGA		
<i>ECM1</i> -10F	AATCCAGCTGTGCAAGGCAG	469	62
<i>ECM1</i> -10R	GTAATGAGTGTTTCAGATGGG		

**Figure 3.** Amplification of *ECM1* exons 1 to 10 resolved on 2.5% agarose gel.

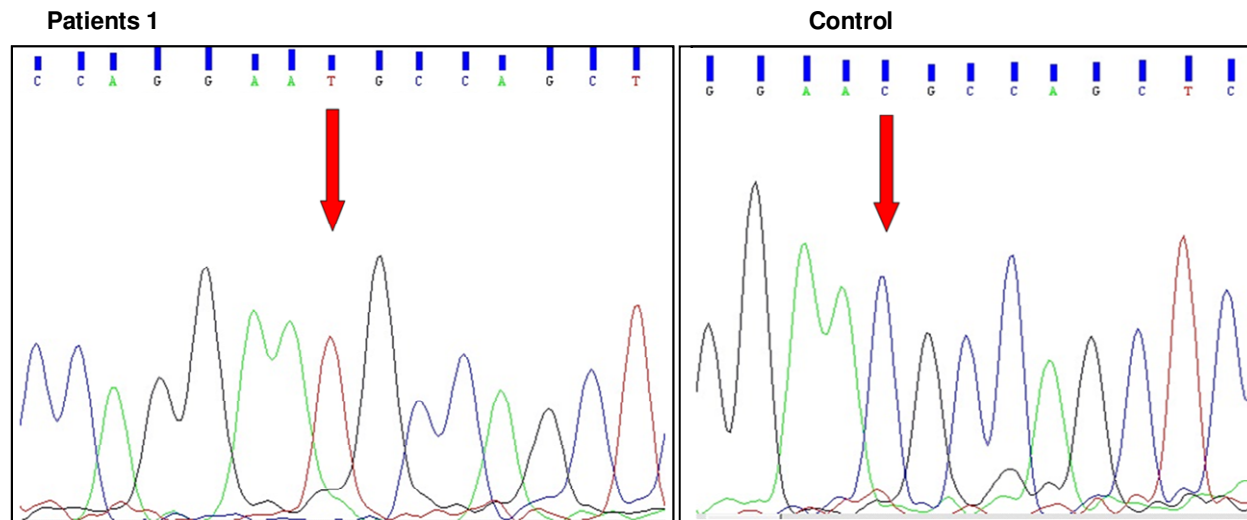
temperature for 45 s, 60°C for 45 s. PCR products (5 µl) were analyzed by 2.5% agarose gel electrophoresis (Figure 3). PCR products were then purified by using commercial kit (QIAquick PCR Purification Kit, Qiagen, Crawley, UK) and sequenced directly using Big Dye® Terminator v3.1 cycle sequencing kit in an ABI 3100 genetic analyzer (Applied Biosystems, Foster City, CA, USA).

## RESULTS

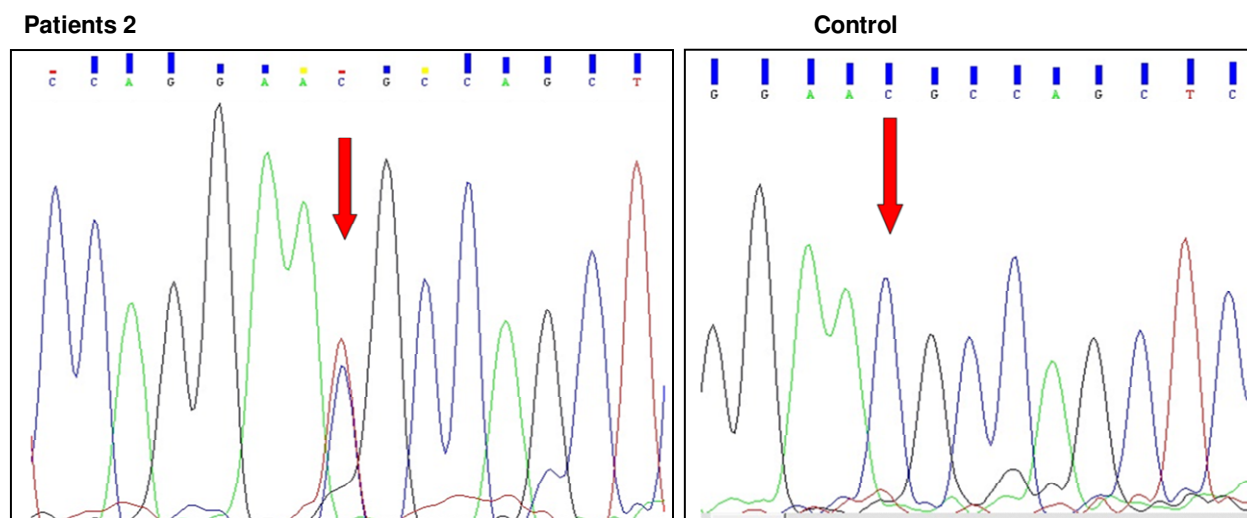
Direct sequencing of PCR amplified products from the affected siblings with LP were shown to have one base

point mutation by substitution of a nucleotide in exon 6 and 8. In patient 1, a nucleotide C was substituted to T (C→T) as compared to normal control, at codon 2, in exon 6 (Figure 4). This non-pathogenic missense mutation replaces the of amino acid residue arginine (CGC) to cysteine (TGC), unlike the normal *ECM1* protein. In patient 2, at the same location, polymorphism of nucleotide C to T (C/T) was observed (Figure 5), which may lead to the appearance of cysteine and/or arginine in the resulting gene product.

The sequence analysis of exon 8 in patient 1 and control



**Figure 4.** Sequence analysis of patient 1 showing a nucleotide C substitution to T (C→T) as compared to normal, at codon 2 in exon 6.



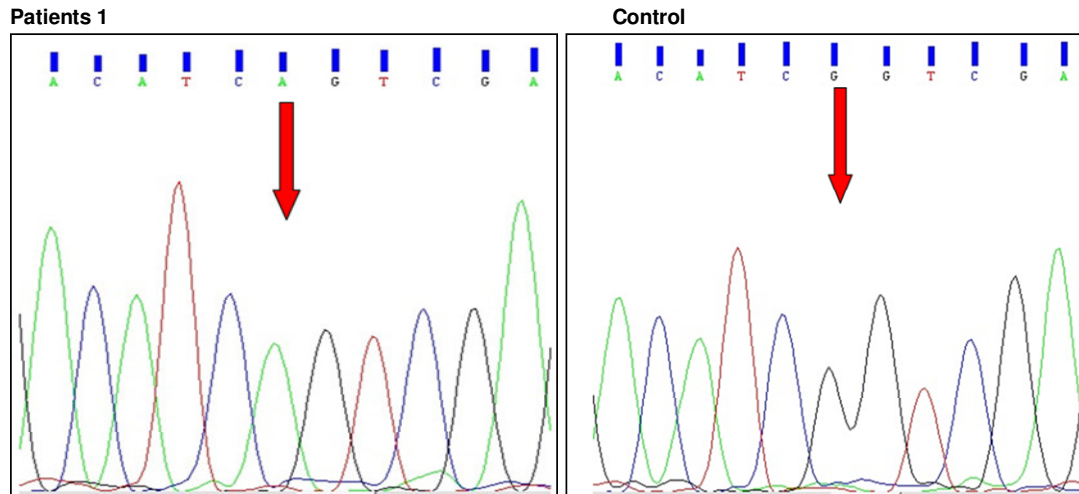
**Figure 5.** Sequence analysis of patient 2 showing single nucleotide polymorphism of C to T (C/T) as compared to control in exon 6.

Subjects showed that a nucleotide G was substituted to A (G→A) at codon 53, in exon 8 (Figure 6). This substitution leads to a silent mutation as in both forms of codon code for same amino acid residue serine (TCG → TCA). In patient 2, at the same location of exon 8, polymorphism of nucleotide G to A (G/A) was observed (Figure 7), but this does not cause any change in the coded amino acid.

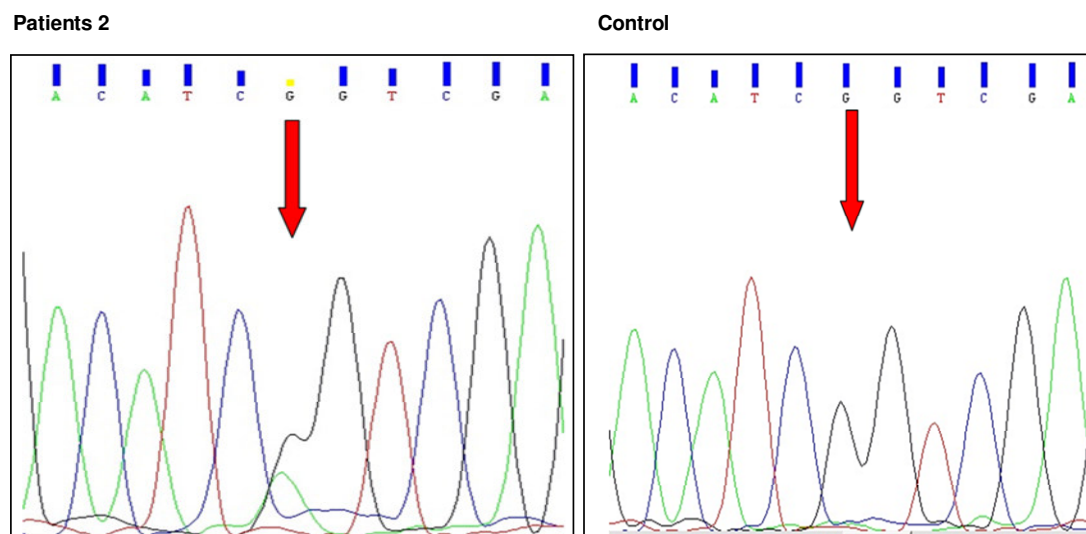
## DISCUSSION

A number of recent genetic studies reported the involvement of homozygous frame shift, missense, non-

sense and single nucleotide substitution, deletion and insertion mutations in *ECM1* gene LP which is located on chromosome 1q21.2 (Salih et al., 2011; Samdani et al., 2010; Kumar et al., 2009; Nasir et al., 2009). About 300 cases of LP have been so far reported. It is found worldwide, but is more common in some countries, such as South Africa, where a founder effect has been demonstrated (Van Houghenouck-Tulleken et al., 2004). The *ECM1* has three known splice variants: *ECM1a*, *ECM1b* and *ECM1c*. To date, 41 distinct germline missense, nonsense, splice site, small and large deletions and insertions, have been reported (Chan et al., 2007). Approximately, 50% of the mutations cluster to



**Figure 6.** Sequence analysis of patient 1 and control showing a nucleotide G substitution to A (G→A) at codon 53, in exon 8.



**Figure 7.** Sequence analysis of patient 2 in exon 8 showing polymorphism of nucleotide G to A (G/A) as compared to control.

exon 6 and 7 of the gene (Wang et al., 2006). The exact pathogenesis of this disease is unknown. It was considered either as a lysosomal storage disease or disorder of disturbance in collagen synthesis. Recently, loss of function mutations in the gene encoding ECM1 on band 1q21 has been identified as the cause of lipid proteinosis. The most common location is at exons 6 and 7, patients with exon 6 mutation result in a more severe phenotype, while exon 7 mutations display slightly milder clinical features (Kumar et al., 2009).

This study reports an unusual finding of non-pathogenic single nucleotide base substitution mutations in exons 6 and 8 in two brothers suffering from LP of a Pakistani family. The coding region of *ECM1* gene containing 10

exons were amplified and sequenced. Both patients were shown to have one base mutation by substitution of a nucleotide in exons 6 and 8. In patient 1, a nucleotide C was substituted to T (C→T) at codon 2, in exon 6 (Figure 4). This non-pathogenic missense mutation causes conversion of amino acid residue arginine (CGC) to cysteine (TGC) unlike the normal ECM1 protein. In patient 2, at the same location, polymorphism of nucleotide C to T (C/T) was observed (Figure 5), which may lead to the appearance of cysteine and/or arginine in the resulting gene product.

The sequence analysis of exon 8 in patient 1 and control subjects showed that a nucleotide G was substituted to A (G→A) at codon 53, in exon 8 (Figure 6).

This substitution leads to a silent mutation as in both forms of codon code for same amino acid residue, serine (TCG → TCA). In patient 2, at the same location of exon 8, polymorphism of nucleotide G to A (G/A) was observed (Figure 6), but this does not cause any change in the coded amino acid. Earlier, a case of homozygous 62-bp insertion (Nasir et al., 2009) and a case of homozygous frame shift mutation leading to premature termination of *ECM1* protein causing LP (Samdani et al., 2010) have been reported in Pakistani families.

This study presents an unusual missense and silent mutations in siblings of Pakistani family suffering from LP. These findings support an unusual function of *ECM1* protein and broaden the spectrum of disease-linked mutations in this rare case of genodermatosis in this region. The identification of these mutations in *ECM1* gene may be of help in making the involvement of *ECM1* gene clear in LP. The results of this study may also be exploited to establish a phenotype-genotype correlation, more precise and accurate prognosis and/or diagnosis, carrier screening for the transfer of LP within families horizontally as well as vertically and also in making the effective strategies for genetic counseling in this regard.

## REFERENCES

- Chan L, Liu L, Hamada T, Sethurama G, McGrath JA (2007). The molecular basis of lipoid proteinosis: mutations in extracellular matrix protein 1. *Exp. Dermatol.*, 16: 881-890.
- Dyer JA (2008). Lipoid Proteinosis; skin in nutritional, metabolic, and heritable diseases. In Fitzpatrick's Dermatology in general medicine (Wolf K, Goldsmith L, Katz S et al), 7<sup>th</sup> Ed, New York: McGraw Hill, pp 1288-1292.
- Hamada T, Wessagowit V, South AP, Ashton GH, Chan I, Oyama N (2003). Extracellular matrix protein1 (*ECM1*) gene mutations in lipoid proteinosis and genotype phenotype correlation. *J. Invest. Dermatol.*, 120: 345-350.
- Horey L, Wollina U, Potikha T, Hafner A, Ingber A, Liu L, McGrath J, Zlotogorski A (2009). Lipoid proteinosis: identification of two novel mutations in the human *ECM1* gene and lack of phenotype-genotype correlation. *Acta. Derm. Venereol.*, 89: 528-530.
- Kumar P, Sampath V, Manoharan K (2009). Lipoid Proteinosis in a child with recurrent respiratory infection. *J. Indian Soc. Tele Dermatol.*, 3(4): 6-11.
- Maniatis T, Fritsch EF, Sambrook J (eds) (1982). *Molecular Cloning. A laboratory manual*. Cold Spring Harbor, NY; Cold Spring Harbor Laboratory Press.
- Nasir M, Latif A, Ajmal M, Ismail K, Hameed A (2009). A novel homozygous 62-bp insertion in *ECM1* causes lipoid proteinosis in a multigeneration Pakistani family. *Br. J. Dermatol.*, 161: 688-669.
- Salih MA, Abu-Amero KK, Alrasheed S, Alorainy IA, Liu Lu, McGrath JA, Maldergem LV, Al-Fakey YH, Al-Suhaibani AH, Oystreck DT, Bosley TM (2011). Molecular and neurological characterizations of three Saudi families with lipoid proteinosis. *BMC Med. Gen.*, 12: 31.
- Samdani AJ, Azhar A, Shahid SM, Nawab SN, Shaikh R, Qader SA, Mansoor Q, Khoso BK, Ismail M (2010). Homozygous frame shift mutation in *ECM1* gene in two siblings with lipoid proteinosis. *J. Dermatol. Case Rep.*, 4(4): 77-81.
- Urbach E, Wiethe C (1929). Lipoidosis cutis et mucosae. *Virchows Arch. Path. Anat.*, 273: 285-319.
- Van Hougenhouck-Tulleken W, Chan I, Hamada T, Thornton H, Jenkins T, McLean WH, McGrath JA, Ramsay M (2004). Clinical and molecular characterization of lipoid proteinosis in Namaqualand, South Afr. *Br. J. Dermatol.*, 151: 413-423.
- Wang CY, Zhang PZ, Zhang FR, Liu J, Tian HQ, Yu L (2006). New compound heterozygous mutations in a Chinese family with lipoid proteinosis. *Br. J. Dermatol.*, 155: 470-472.