

Case Report

Resolution of intracerebral *Bacillus cereus* infection following open neck injury after comprehensive treatment

Guo-Jie Yao, Jie Gong*, Ge Zhang, Cheng-Cai Li, Zheng Liu, Wei Du, Guo-zheng Xu, Ke Wei.

Department of Neurosurgery, Wuhan General Hospital of Guangzhou Command, PLA, No. 627, Wuluo Road, Wuhan, Hubei, China, 430070, China.

Accepted 24 January, 2012

***Bacillus cereus* can cause a wide range of infections that are often overlooked in clinical practice. A case of intracerebral *B. cereus* infection following open neck injury in a 5-year-old child which was successfully treated with comprehensive therapy consisting of antibiotics and ventriculoperitoneal shunt placement is reported.**

Key words: *Bacillus cereus*, comprehensive therapy, ventriculoperitoneal shunt placement.

INTRODUCTION

Case report

A 5 year old child weighing 15 kg was admitted to our hospital on May 8, 2010 with a complaint of neck and chest pain for 6 h following a road accident causing a puncture wound to the neck with a wooden stake. Brain and neck CT showed mild pneumatosis in the pontine cistern (Figure 1A) and bubble shadows in the muscular layer of the neck and vertebral canal; there were no residual foreign bodies or cervical spine fracture(s). Chest X-ray revealed pulmonary contusion. On physical examination, the child was disoriented and tachypnoic with mild collapse in the right thoracic cage together with extensive coarse rales bilaterally. Debridement in combination with foreign body removal was performed immediately. During surgery, a wound 3 mm in length which extended into the muscular layer was found on the left side of the neck. 2 wooden foreign bodies (3×1 cm) were removed during surgery. Post-operatively, intravenous ceftriaxone (1 g once daily) was administered for anti-infection therapy (Figure 2). The rales in both

lungs improved and sputum culture was positive for *Klebsiella pneumoniae* sensitive to aztreonam. After treatment with aztreonam from May 13 to 18, the pulmonary infection was controlled. However, brain and neck magnetic resonance imaging (MRI) revealed a cystic mass in the neck (Figure 1B).

On May 18, the patient developed high-grade fever with maximum body temperature reaching 39.3°C (Figure 2). From May 25 to June 5, intravenous ceftriaxone (1 g once daily) was given. CSF culture was negative. The cystic mass in the neck enlarged over time accompanied by tenderness and an increase in local skin temperature. Cyst fluid culture on June 15 was negative. On July 9, a second CT scan of the brain revealed hydrocephalus (Figure 1C). Cyst puncture was performed on July 12, 15 and 20 and cyst fluid culture was tested using Kirby-Bauer antibiotic testing (disk diffusion antibiotic sensitivity testing). The testing was positive for *Bacillus cereus* which was sensitive to erythromycin, penicillin, ceftriaxone, clindamycin, piperacillin-tazobactam and chloramphenicol. Following consultation between pediatricians and infectious disease physicians, combination therapy was recommended. Subsequently, intravenous piperacillin-tazobactam (2.25 g once every 8 h) and chloramphenicol (3 ml twice daily) were administered for 15 days. During the treatment, recurrent fever occurred and the maximal body temperature was 39.6°C. 2 weeks after the start of combination therapy

*Corresponding author. E-mail: jiegong163@163.com; leosoko@sina.com. Tel: +86-027-68878529.

Abbreviations: CSF, Cerebral spinal fluid; CT, computed tomography; MRI magnetic resonance imaging.

fluctuating fever was still present and the maximal body temperature still reached 39.6°C. After a second consultation, intravenous meropenem (0.5 g 3× daily) was administered for 33 days. To prevent fungal infection secondary to long-term antibacterial treatment, prophylactic fluconazole was also given for 33 days. The patient's body temperature recovered gradually and anti-infection therapy was discontinued on September 2.

One week later, the patient still had fluctuating low-grade fever but body temperature was generally normal. The maximal body temperature was 38.5°C. 2 consecutive CSF cultures were positive for *B. cereus* which was sensitive to gentamicin. The neck cyst was connected to the subarachnoid space. It was difficult to resolve the cyst with hydrocephalus being present. The patient had ventriculomegaly and there was the possibility of further enlargement of the bilateral lateral cerebral ventricles and third and fourth ventricles. Following consultation with neurosurgeons and neurologists, right external ventricular drainage was performed on September 9. At the same time, gentamicin in normal saline (20,000 U/100 ml) was used to irrigate the cerebral ventricles. During irrigation, purulent fluid was noted. Subsequently, the CSF became clear and the size of the cerebral ventricle(s) decreased.

From September 9 to 14, the increase in body temperature was not controlled, and cefepime (1 g twice daily) was administered with the addition of metronidazole. During the treatment, fluctuating low-grade fever was still present and the maximal body temperature reached 38.3°C. Cerebrospinal fluid culture was positive for *B. cereus* which was sensitive to penicillin and gentamicin. From September 14 to October 1, intravenous penicillin (1,600,000 U three times daily) was administered. Computed tomography showed that the size of the cerebral ventricle had returned to normal (Figure 1D). We attempted to replace the external ventricular drainage with a ventriculoperitoneal shunt. However, 1 CSF culture was positive for *B. cereus* (September 18), although 5 cultures were negative (September 17, 20, 23, 25 and 27). Thus, ventriculoperitoneal shunt placement was not carried out. On October 3, right external ventricular drainage was alternated with left external ventricular drainage, and intravenous penicillin (1,600,000 U three times daily) was given in combination with ornidazole, which was added to prevent meningitis from anaerobic infection. However, CSF cultures on October 10, 14 and 18 were positive for *B. cereus*, and the CSF again became cloudy. Following external drainage, the CSF became clear, and the cerebral ventricle remained unchanged (Figure 1E). On October 19, left external ventricular drainage was discontinued. Because of the risk for infection following long-term external ventricular drainage, ventriculoperitoneal shunting was performed. Post-operatively, fever was not noted. On November 8, the CSF became clear and three consecutive CSF cultures

were negative for *B. cereus* (November 8, 11 and 14). Brain CT revealed that the cerebral ventricle was normal (Figure 1F). The patient recovered and was discharged 2 weeks later.

For monitoring treatment, serum C-reactive protein was also measured to assess the stress response, and evaluate trauma, infection, inflammation and surgery (Figure 2). Immunoturbidimetry was performed to measure C-reactive protein using a kit (YZB/USA 1479-2008) in an immunology analyzer (Beckman Immage; Beckman Coulter, Inc, Fullerton, CA USA). It has been found that C-reactive protein has considerable value for the prognosis/diagnosis of postoperative infections (Nunes et al., 2011).

DISCUSSION

B. cereus is a member of the family *Bacillaceae* and is widely distributed in dust, air and water. *B. cereus* is a motile, aerobic or facultatively anaerobic, spore-forming, gram-positive or gram-variable bacterium. With regard to being a human pathogen, *B. cereus* is probably known best as a mediator of self-limited foodborne illness. However, there is increasing awareness that *B. cereus* can be an opportunistic pathogen, causing infections in critically ill and debilitated patients, transplant recipients, patients with foreign bodies, intravenous drug abusers and other immunocompromised patients (de Almeida et al., 2003; Hilliard et al., 2003; Gaur and Shenep, 2001). In clinical practice such infections are frequently overlooked as members of the family *Bacillaceae*, except for the *B. anthracis*, are usually regarded as laboratory contaminants (Ebrahimi et al., 2009).

Our patient had a clear history of trauma, and foreign bodies had penetrated into the brain. Although we lacked direct evidence that there was a correlation between the neck injury and infection, we speculated that *B. cereus* was the pathogen. We believe the pathogen originated from the wooden foreign bodies and entered the brain causing intracerebral infection. The CSF culture was performed using pediatric blood culture bottles (Pedi-Bac T; BioMerieux, Inc., Durham, NC). When the result of blood culture was positive gram stain smear was performed and subcultured on blood agar at the same time for identification. Based on the combined results of gram stain, blood agar plate culture and biochemical tests we identified the pathogen. When the CSF culture was negative, fever and other symptoms resolved rapidly.

As far as we know, only 11 cases of brain abscess caused by *B. cereus* have been reported previously (Mochiduki et al., 2007; Kuwabara et al., 2006; Mori et al., 2002; Psiachou-Leonard et al., 2002; Sakai et al., 2001; Bert et al., 1995; Jones et al., 1992; Jenson et al., 1989; Pennington et al., 1976). There have also been case reports of *B. cereus* meningitis (Barrie et al., 1992; Berner et al., 1997). A survey conducted by Hilliard et al.

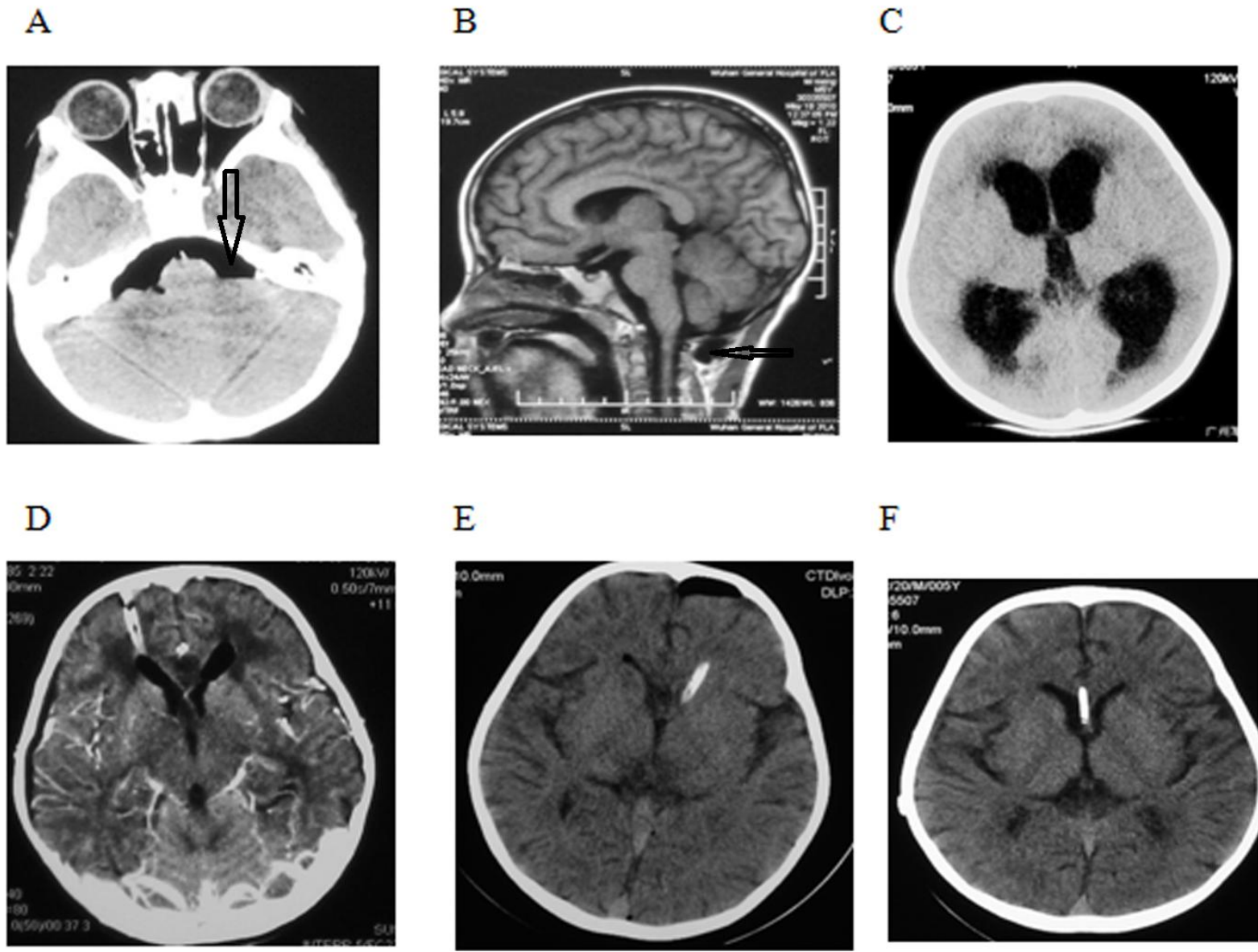


Figure 1. (A) Pneumatosis in the pontine cistern at 3 hours after trauma (May 8, 2010); (B) Cystic mass in the neck on MRI (May 18, 2010); (C) Hydrocephalus (July 9, 2010); (D) After right external ventricular drainage (September 17, 2010); (E) After left external ventricular drainage (October 15, 2010); (F) Normal cerebral ventricle two months after ventriculoperitoneal shunt placement (December 20, 2010).

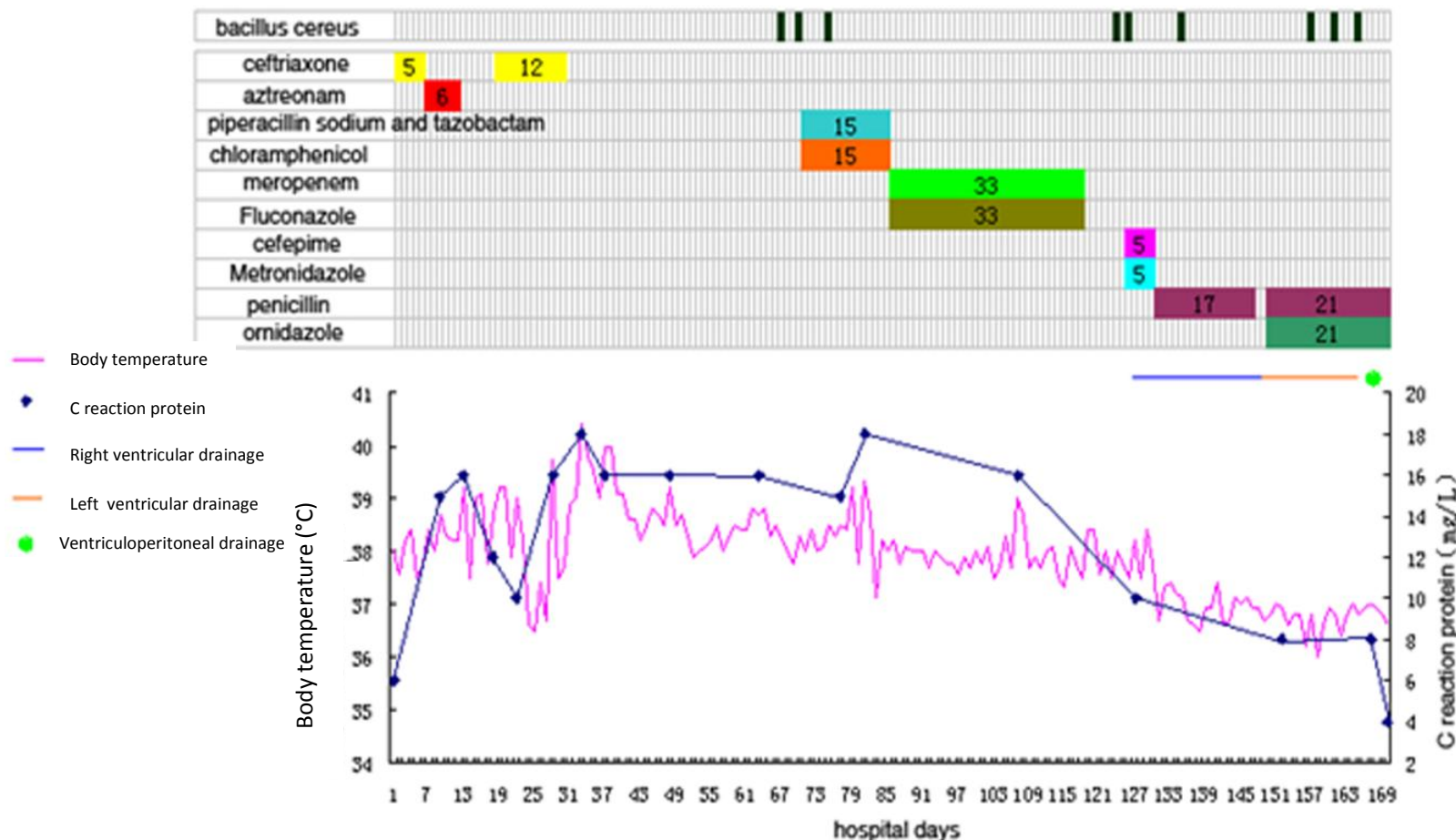


Figure 2. Body temperature, drugs, and C-reactive protein level during the treatment.

(2003) reported systemic *B. cereus* infection in 22 patients among whom 16 were premature infants. Although the mortality rate of *B. cereus* infection in neonates is not high, the actual incidence of infection of *B. cereus* or other bacilli is probably higher than reported (Hilliard et al., 2003). This may be attributed to not attempting to identify the exact type of bacilli.

Generally, *B. cereus* is resistant to penicillin and cephalosporins. Studies have reported that *B. cereus* is sensitive to aminoglycosides, clindamycin, vancomycin, carbapenems, chloramphenicol and erythromycin (Weber et al., 1988). As for systemic infection, vancomycin in combination with another antibiotic (such as an aminoglycoside, clindamycin, etc) is empirically

recommended before the results are obtained from susceptibility testing. In addition, contaminant foreign bodies such as the intravascular catheters and tubes for ventricular shunt should be removed or replaced to avoid persistent and recurrent infection (Sakai et al., 2001).

Previous studies have confirmed the effectiveness and necessity of surgical intervention in the

treatment of brain abscess and necrotizing fasciitis, although such surgery may cause damage to tissues. In the present study, a ventriculoperitoneal shunt was considered at the early stage of hydrocephalus, but this strategy was not adopted due to uncontrolled intracerebral infection and positivity of CSF culture. Following long-term anti-infection therapy and external ventricular drainage, the CSF became clear, and the symptoms resolved significantly following ventriculoperitoneal shunt placement. Although the culture was positive before surgery, following surgery and anti-infection therapy the culture was negative.

The improvement of the brain abscess in the present report is attributed to comprehensive therapy. When hydrocephalus was identified, we hesitated to perform ventriculoperitoneal shunting. We postulate that appropriate pharmacotherapy can cure *B. cereus*-induced brain abscess. Weber et al. (1988) showed in their susceptibility testing that *B. cereus* was sensitive to imipenem, vancomycin, chloramphenicol, gentamicin, and ciprofloxacin, but insensitive to penicillin and cephaloridine. Except for the treatment with imipenem, their results were largely consistent with those in our report. Luna et al. (2007) found that all 42 *B. cereus* isolates tested were sensitive to chloramphenicol, ciprofloxacin, gatifloxacin, gentamicin, levofloxacin, linezolid, moxifloxacin, rifampicin, streptomycin, tetracycline, tigecycline and vancomycin. Three *B. cereus* isolates were insensitive to clindamycin and one isolate was insensitive to clarithromycin and clindamycin. However, not all patients will recover after pharmacotherapy.

Generally, when the size of a brain abscess is larger than 2.5 cm in diameter, surgical drainage is required following 6-8 weeks of anti-infection therapy regardless of the pathogen. For patients with hydrocephalus, early surgical cerebral drainage is preferred. In addition, early anti-infection therapy is necessary, but the symptoms may not completely resolve. The residual symptoms may resolve after surgical intervention. Besides anti-infection therapy, for patients with neutropenia, granulocyte colony-stimulating factor is recommended to increase the leukocyte count, which is also critical.

Based on the treatment of *B. cereus* infection, we speculate that early and long-term treatment with sufficient doses of multiple antibiotics is crucial. Once intracerebral infection with or without hydrocephalus is confirmed, active surgical intervention is preferred.

REFERENCES

- Barrie D, Wilson JA, Hoffman PN, Kramer JM (1992). *Bacillus cereus* meningitis in two neurosurgical patients: an investigation into the source of the organism. *J. Infect.* 25: 291-297.
- Berner R, Heinen F, van Velthoven V, Sauer M, Korinthenberg R (1997). Ventricular shunt infection and meningitis due to *Bacillus cereus*. *Neuropediatrics*, 28: 333-334.
- Bert F, Ouahes O, Lambert-Zechovsky N (1995). Brain abscess due to *Bacillus macerans* following a penetrating periorbital injury. *J. Clin. Microbiol.*, 33: 1950-1953.
- de Almeida SM, Teive HA, Brandi I, Nabhan SK, Werneck LC, Bittencourt MA, Medeiros CR, Pasquini R, de Mello HH (2003). Fatal *Bacillus cereus* meningitis without inflammatory reaction in cerebral spinal fluid after bone marrow transplantation. *Transplantation*, 76: 1533-1534.
- Ebrahimi CM, Kern JW, Sheen TR, Ebrahimi-Fardooee MA, van Sorge NM, Schneewind O, Doran KS (2009). Penetration of the blood-brain barrier by *Bacillus anthracis* requires the pXO1-encoded BslA protein. *J. Bacteriol.*, 191: 7165-7173.
- Gaur AH, Shenep JL (2001). The expanding spectrum of diseases caused by *Bacillus cereus*. *Pediatr. Infect. Dis. J.*, 20: 533-534.
- Hilliard NJ, Schelonka RL, Waites KB (2003). *Bacillus cereus* bacteremia in a preterm neonate. *J. Clin. Microbiol.*, 41: 3441-3444.
- Jenson HB, Levy SR, Duncan C, McIntosh S (1989). Treatment of multiple brain abscesses caused by *Bacillus cereus*. *Pediatr. Infect. Dis. J.*, 8: 795-798.
- Jones BL, Hanson MF, Logan NA (1992). Isolation of *Bacillus licheniformis* from a brain abscess following a penetrating orbital injury. *J. Infect.*, 24: 103-104.
- Kuwabara H, Kawano T, Tanaka M, Kobayashi S, Okabe G, Maruta A, Nagao T, Ishigatsubo Y, Mori H (2006). Cord blood transplantation after successful treatment of brain abscess caused by *Bacillus cereus* in a patient with acute myeloid leukemia. *Rinsho Ketsueki Japanese*, 47: 1463-1468.
- Luna V, King D, Gullledge J, Cannons AC, Amuso PT, Cattani J (2007). Susceptibility of *Bacillus anthracis*, *Bacillus cereus*, *Bacillus mycoides*, *Bacillus pseudomycoides* and *Bacillus thuringiensis* to 24 antimicrobials using Sensititre automated microbroth dilution and Etest® agar gradient diffusion methods. *J. Antimicrob. Chemother.*, 60: 555-567.
- Mochiduki Y, Amemiya T, Yabe M (2007). Brain abscess induced by *Bacillus licheniformis* complications in acute myeloid leukemia (AML) (in Japanese). *Kansenshogaku Zasshi*, 81: 592-596.
- Mori T, Tokuhira M, Takae Y, Mori S, Suzuki H, Abe T, Takeuchi T (2002). Successful non-surgical treatment of brain abscess and necrotizing fasciitis caused by *Bacillus cereus*. *Intern. Med.*, 41: 671-673.
- Nunes BK, Lacerda RA, Jardim JM (2011). Systematic review and meta-analysis of the predictive value of C-reactive protein in postoperative infections. *Rev. Esc. Enferm USP.*, 45: 1488-1494.
- Pennington JE, Gibbons ND, Strobeck JE, Simpson GI, Myerowitz RL (1976). *Bacillus* species infection in patients with hematologic neoplasia. *JAMA*, 235: 1473-1474.
- Psiachou-Leonard E, Sidi V, Tsvitanidou M, Gompakis N, Kolioukas D, Roilides E (2002). Brain abscesses resulting from *Bacillus cereus* and an Aspergillus-like mold. *J. Pediatr. Hematol. Oncol.*, 24: 569-571.
- Sakai C, Iuchi T, Ishii A, Kumagai K, Takagi T (2001). *Bacillus cereus* brain abscesses occurring in a severely neutropenic patient: Successful treatment with antimicrobial agents, granulocyte colony-stimulating factor and surgical drainage. *Intern. Med.*, 40: 654-657.
- Weber DJ, Saviteer SM, Rutala WA, Thomann CA (1988). *In vitro* susceptibility of *Bacillus* spp. to selected antimicrobial agents. *Antimicrob. Agents Chemother.*, 32: 642-645.