

Full Length Research Paper

The effect of Echinacea on kidney and liver after experimental renal ischemia/reperfusion injury in the rats

Gokhan Bayramoglu¹, Sahin Kabay^{2*}, Hilmi Ozden³, Mehmet Cengiz Ustuner⁴, Onur Uysal⁵, Aysegul Bayramoglu⁴, Hakan Senturk¹, Gül Güven³, Cansu Ozbayer⁴, Ali Kutlu¹, Derya Ustuner⁶ and Mediha Canbek¹

¹Artvin Coruh University, Faculty of Arts and Science, Department of Biology, Coruh, Turkey.

²Department of Urology, Dumlupınar University Kütahya, Treating and Research Hospital, Kütahya, Turkey.

³Department of Anatomy, Faculty of Medicine, Eskisehir Osmangazi University, Eskisehir, Turkey.

⁴Artvin Coruh University, Faculty of Medicine, Department of Medical Biology, Coruh, Turkey.

⁵Eskisehir Osmangazi University, Vocational School of Health Services, Eskisehir, Turkey.

⁶Department of Medical Genetic, Faculty of Medicine, Eskisehir Osmangazi University, Eskisehir, Turkey.

Accepted 16 September, 2011

The aim of the study is to investigate the effect of Echinacea on kidney and liver against oxidative stress during renal ischemia-reperfusion (I/R) injury, by determining biochemical parameters and evaluating histological examinations. Adult male Sprague-Dawley rats were evaluated in five groups (each group consists of 8 animals). Group 1 (Control; non-ischemic animals); Group 2 (renal I/R injury+Saline), Group 3 (renal I/R injury + Echinacea, 25 mg/kg), Group 4 (renal I/R injury + Echinacea, 50 mg/kg) Group 5 (renal I/R injury+ Echinacea, 100 mg/kg) were designed to evaluate effects of Echinacea in renal I/R injury on the morphological changes in kidney and liver. A right nephrectomy was performed for I/R injury. On the 15th day following nephrectomy, ischemia and reperfusion was performed. *Echinacea* was administered intraperitoneally. Left kidney and liver were taken after 24 h of reperfusion period for histopathological examinations. The malondialdehyde (MDA) levels, superoxide dismutase (SOD) and catalase (CAT) enzyme activities were determined from tissue homogenates. In the study, Echinacea administration in renal ischemia-reperfusion decreased MDA in kidney and liver. SOD activity was decreased with low and high doses of Echinacea treatment in both kidney and liver. Echinacea administration decreased CAT levels in kidney and no difference was observed between Echinacea doses. CAT was increased in liver low dose group. But CAT was decreased in high doses of Echinacea. Histopathological examinations showed partial improvement in the damages seen in I/R injury after Echinacea administration at both kidney and liver. Echinacea may be effective in preventing oxidative injury.

Key words: Echinacea, ischemia-reperfusion, kidney, liver, antioxidant enzyme.

INTRODUCTION

Renal ischemia and subsequent reperfusion (I/R) injury is a major cause of acute renal failure (Hosseini et al., 2010). I/R injury leads to the production of excess reactive oxygen species (ROS), which can initiate lipid

peroxidation, oxidize proteins to inactive states and cause DNA strand breaks (de Groot and Rauen, 2007; Lien et al., 2003). It has been known that during ischemia, cells and tissues undergo rapid changes which lead to perturbations in signaling pathways and surface molecule expression. These events are thought to contribute to the tissue damage during I/R in various organs (Riedemann and Ward, 2003; Emre et al., 2006). Echinacea species are rich in bioactive metabolites of which lipophilic

*Corresponding author. E-mail: skabay@yahoo.com. Tel: +90274 2652031. Fax: +90274 2652277.

alkamides, water-soluble phenolic compounds (mainly caffeic acid derivatives) and polysaccharides has been reported to possess multifunctional effects, such as immunostimulating, anti-inflammatory, antiviral, anti-cancer and radioprotective, as well as possible antiandrogenic activities are the most recognized for their immunomodulatory properties. Recent reports indicate that Echinacea products inhibit nitric oxide (NO) production in activated macrophages (Liu et al., 2006). It has been found that Echinacea preparations have antioxidative and free radical scavenging properties (Masteikova et al., 2007, Aherne et al., 2007, Agnew et al., 2005). Wang et al. (2009) showed that renal I/R can cause hepatotoxicity in rats. Another study revealed in kidney transplantation model that, the liver was affected during I/R process as evidenced by antioxidant enzymes in pigs (Gulec et al., 2008).

In this study, we aimed to investigate the possible protective effect of Echinacea on kidney and liver against oxidative stress during renal I/R injury by determining biochemical parameters and evaluating histological examinations.

MATERIALS AND METHODS

Animals

Forty adult male Sprague-Dawley rats weighting 250 to 280 g were obtained from TICAM (Medical and Surgical Experimental Research Center, Eskisehir-Turkey) and housed in polycarbonate cages in a room with controlled temperature (22±2°C), humidity (50±5%), and a 12 h cycle of light and dark (07:00 AM TO 07:00 PM light). Rats were fed laboratory pellet chows and given water *ad libitum*. The animals were divided into five groups. Echinacea purpurea (purchase from local drugstore, SOLGAR) was dissolved in serum physiologic.

Experimental protocol

Rats were anesthetized (70 mg/kg ketamine and 0.75 mg/kg chlorpromazine intramuscular) during all surgical procedures. Under anesthesia, a right nephrectomy was performed and the rats were allowed to recover for 15 days before they were subjected to I/R injury. On the 15th day following nephrectomy, rats were fasted overnight. Under anesthesia, a midline laparotomy was made, and using minimal dissection, the left renal pedicle was isolated. The renal pedicle was occluded for 45 min to induce ischemia and then subjected for 24 h of reperfusion (I/R groups). Group (III, IV and V) Echinacea (25, 50 and 100 mg/kg; I/R+ Echinacea groups) or saline (I/R group) was administered intraperitoneally 15 min before ischemia and 12 h after reperfusion. The animals were decapitated after 24 h of reperfusion period.

Histopathological evaluation

Left nephrectomy specimens and livers were processed routinely in 10% formalin solution, and embedded in paraffin. Tissue sections of 5 µm were obtained, and stained with haematoxylin and eosin (H&E). Histopathological examinations were performed under a light microscope (NIKON, Japan). All histopathological examinations were performed by the same histologist of the institute, who was

blinded to the all tissue specimens to which group they belonged to. A minimum of 10 fields for each kidney and liver slides with minimum × 50 magnification were examined to assign the severity of these morphological changes. It was assigned for severity of changes using scores on a scale of none (–), mild (+), moderate (++), and severe (+++) damage in order to perform a comparison between the groups.

Biochemical analyses

Homogenate preparation

After sacrificing the animals, isolated areas of the nephron of their kidneys and liver were quickly removed and perfused immediately with ice-cold normal saline, and homogenized in chilled potassium chloride (1.17%) using a homogenizer. The homogenate was centrifuged at 800×g for 5 min at 4°C in a refrigerated centrifuge to separate the nuclear debris. The supernatant so obtained was centrifuged at 10,500×g for 20 min at 4°C to get the homogenate which was used to assay malondialdehyde (MDA), catalase (CAT), and superoxide dismutase (SOD) activity.

Protocols of lipid peroxidation and enzyme activities measurement

The measurement of MDA levels by thiobarbituric acid reactivity is the most widely used method for assessing lipid peroxidation. 0.1 ml of homogenate, 3 ml of 1% phosphoric acid, 0.5 ml of distilled water and 1.0 ml of 0.6 % 2-thiobarbituric acid were added. The mixture was boiled in water bath for 45 min; afterward, the mixture was cooled in an ice, followed by an addition of 4.0 ml of n-butanol to extract the cold thiobarbituric acid reactants. The optical density of the n-butanol layer was determined at 532 nm after centrifugation at 1,000 g for five minutes and expressed as nmol MDA/g of wet tissue (Mihara and Uchiyama, 1978).

Determination of SOD activity

SOD activity was spectrophotometrically assayed with commercial kits. The Fluka SOD kit USA contains all reagents and solutions required for determining superoxide dismutase activity in an indirect assay method based on xanthine oxidase and a novel color reagent. The homogenate SOD activity was determined by inhibition of Formozan dye (450 nm) employing the xanthin-xanthin oxidase enzymatic method to generate superoxide radicals and calculated the active SOD concentration according to inhibition curve graphic expressed as U/g of wet tissue.

Determination of CAT activity

One unit (1U) of CAT equals the enzyme activity that recognized 1 µmol of hydrogen peroxide in 60 s at 37°C. The three blank samples were prepared according to Goth (1991). CAT activity was measured with determination of absorbance of three blank samples at 405 nm in spectrophotometer. CAT activity (kU/L) was calculated as = $[(Abs_{blank1} - Abs_{blanksample}) / Abs_{blank2} - Abs_{blank3}] \times 271$ (Goth, 1991).

Statistical analysis

All statistical analysis was performed with the computer program "SPSS for Windows" (SPSS Inc; Release 11.5; Sep 6, 2002). All of the data were expressed as means ± SD. Differences between

Table 1. Antioxidant enzyme levels in kidney and liver.

Group	Group number	SOD kidney	SOD liver	MDA kidney	MDA liver	CAT kidney	CAT liver
I	10.0	55.99±6.52	53.23±4.93	1.68±0.31	2.33±.31	308.30±62.81	158.42±35.35
II	20.0	65.97±5.10	67.82±5.80	3.99±10.0	7.39±1.22	1184.84±524.69	304.31±224.51
III	30.0	53.76±5.21	350.7±12.59	1.94±0.51	4.50±0.29	6450.5±614.31	320.96±57.60
IV	40.0	57.12±4.14	36.24±9.25	1.66±0.66	5.64±0.32	517.91±159.31	105.19±8.50
V	50.0	54.89±2.78	32.53±8.23	2.55±0.32	3.38±0.42	284.28±44.93	225.72±149.68
P-values and multiple comparison of the groups	G1-G2	0.06	0.00	0.00	0.00	0.01	0.210
	G1-G3	0.44	0.04	0.06	0.00	0.75	0.132
	G1-G4	.992	0.07	0.01	0.00	0.825	0.929
	G1-G5	.993	0.01	0.332	0.30	0.999	0.848
	G2-G3	0.01	0.00	0.00	0.00	0.01	0.999
	G2-G4	0.17	0.00	0.00	0.00	0.16	0.41
	G2-G5	0.02	0.00	0.01	0.00	0.01	0.762
	G3-G4	0.111	0.999	0.917	0.16	0.476	0.22
	G3-G5	0.16	0.981	0.376	0.18	0.58	0.613
G4-G5	0.912	0.926	0.84	0.00	0.762	0.386	

The significance was tested at n.s $p>0.05$, $p < 0.05$, $p < 0.01$ and $p < 0.001$.

groups were evaluated by one-way analysis of variance (ANOVA) followed by Tukey's multiple comparison tests. The significance was tested at $p>0.05$, $p < 0.05$, $p < 0.01$ and $p < 0.001$.

RESULTS

We showed that MDA levels of Group II (I/R) in renal tissue were significantly higher than Group I (control group), Group III (I/R + Echinacea 25 mg), Group IV (I/R Echinacea 50 mg) and Group V (I/R Echinacea 100 mg). Echinacea administration had significantly decreased MDA levels in groups III, IV and V when compared to Group II. In addition to this, there were no difference in MDA levels between Groups III and IV. SOD levels significantly increased in Group II when compared with control group. Echinacea administration decreased SOD levels in Groups III, IV and V. The CAT levels were increased significantly in Group II when compared with control group, but after Echinacea administration CAT levels decreased. In addition, there were significant difference in CAT levels between Groups III, IV and V. The enzymatic activity changes in kidney were demonstrated in Table 1. MDA levels of Group II (I/R) in liver were significantly higher than control group, Group III (I/R + Echinacea 25 mg), Group IV (I/R + Echinacea 50 mg) and Group V (I/R + Echinacea 100 mg). Echinacea administration significantly decreased the MDA levels in Groups III, IV and V when compared to Group II. The SOD levels significantly increased in Group II when compared with control group. SOD levels in Group III, IV and V decreased significantly when compared with Group II. There were not a significant difference between Group III, IV and V. The CAT levels were increased significantly in Group II when compared with

control group, but after Echinacea administration, CAT levels decreased in Groups IV and V while increased in Groups III when compared with Group II. The enzymatic activity changes in liver and kidney are demonstrated in Table 1. The histopathologic findings of kidney and liver are seen in Figures 1, 2 and Tables 2a and b.

DISCUSSION

In our study, Echinacea administration in renal ischemia-reperfusion decreased MDA in kidney and liver. SOD activity was decreased with low and high doses of Echinacea administration in both kidney and liver. Echinacea administration decreased CAT levels in kidney and it were not any difference between Echinacea doses. CAT increased in liver low dose group. But CAT had decreased in high doses of Echinacea. Karabiga et al. (2007) observed severe leukocyte infiltration in kidney after I/R damage. This infiltration caused tubular epithelial degeneration and necrosis in kidney, and hepatic damage. These results make think that inflammatory process is activated by I/R. Biochemical analysis showed that, I/R significantly increased the levels of MDA and SOD while aprotinin significantly decreased. There was no statistically significant difference between the levels of catalase and glutathione peroxidase between the groups. Gokce et al. (2009) also showed that administration of CsA alone resulted in higher myeloperoxidase (MPO), lipid peroxidation, SOD and CAT activity when compared with the control. In rats treated with CAPE alone, the enzyme activities except CAT were not changed. CAPE treatment prevented the increase in MDA and it increased CAT activity much more, but did not affect the activities of MPO and SOD enzyme. In another study

Table 2a. Histopathological findings in the kidney.

Group	Tubular structure										Glomerulus			Cortex			Medulla	
	Epithelial desquamation and degeneration	Loss of brush border	Epithelial cell swelling	Epithelial cell picnosis	epithelial cell vacuolization	Cast accumulation in the lumen	Focal necrotic areas	Congestion	Bowman capsule space	Necrosis	Congestion	MNL infiltration	PMNL infiltration	Fibrosis	Congestion	MNL infiltration	PMNL infiltration	
Group-2: IRP+SF	+++	+++	+++	+++	++	+++	+++	+++	N	-	+++	+++	+	+	+++	+++	+	
Group-3: IRP+EK 25 mg/kg	+++	+++	+++	+++	++	+++	+++	+++	N	-	+++	+++	-	++	+++	+++	-	
Group-4: IRP+EK 50 mg/kg	+++	+++	++	++	++	+++	++	++	N	-	+++	+	-	+	+++	+	-	
Group-5: IRP+EK 100 mg/kg	++	++	++	++	++	+++	++	+	N	-	++	+	-	+	+++	+	-	
Interpretation	n.s	n.s	n.s	n.s	n.s	.s	n.s	Decrease	n.s	-	n.s	Decrease	Decrease	n.s	n.s	Decrease	Decrease	

-, None; ++, moderate; n.s, no difference; +, mild; +++, severe; N, normal.

Table 2b. Histopathological findings in the liver.

Group	Congestion in			Hepatic vacuolization	Focal necrosis	PMNL infiltration in			MNL infiltration in			Karyolysis and picnosis	Loss of intercellular border	Damage in hepatic cord
	Central vein	Portal area	Sinusoid			Central vein	Portal area	Sinusoid	Central vein	Portal area	Sinusoid			
Group-2: IRP+SF	++	++	++	++	-	+	+	++	+	++	++	++	+	+
Group-3: IRP+EK 25 mg/kg	+++	+++	+++	+	-	+	+	++	+	++	++	++	++	+
Group-4: IRP+EK 50 mg/kg	+	++	++	+	-	-	+	+	-	+	+	++	++	+
Group-5: IRP+EK 100 mg/kg	+	+	+	-	-	+	-	-	+	-	+	+	+	+
Interpretation	Decrease	Decrease	Decrease	Decrease	-	Decrease	Decrease	Decrease	Decrease	Decrease	Decrease	n.s	n.s	n.s

-, None; ++, moderate; n.s, no difference; +, mild; +++, severe.

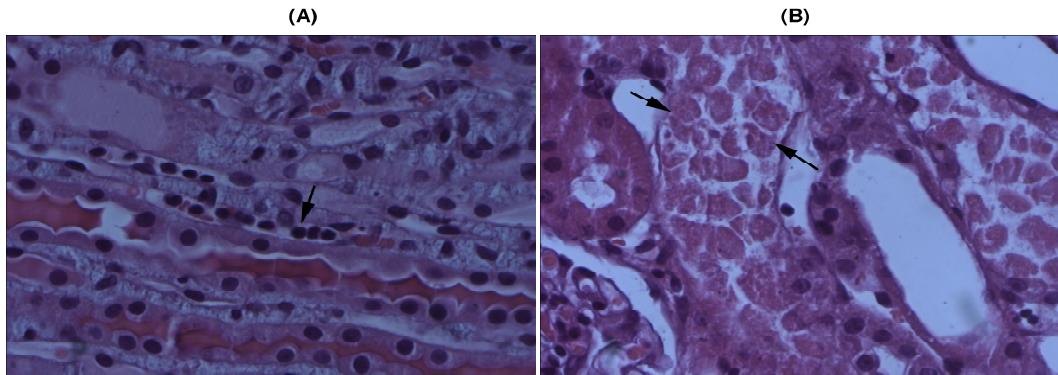


Figure 1. Medullary congestion and MNL infiltration in kidney (A), and degeneration in tubular structures in cortex of kidney (B). H&E×40.

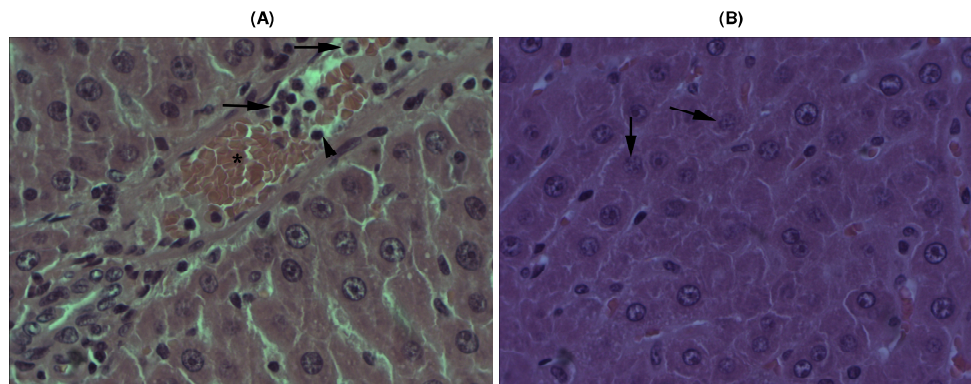


Figure 2. Congestion in portal area PMNL and MNL infiltration (A), karyolysis, damage in hepatic cords and loss of intercellular border in liver (B) H&E×40.

Sing et al. (2005) showed that renal I/R injury caused a severe depletion of antioxidant enzymes, as is apparent from the significantly reduced enzymatic activity of reduced glutathione, glutathione reductase, SOD and CAT. Low-dose of cyclosporine significantly improved the activity of these enzymes. According to Thiemermann et al. (2003), renal I/R demonstrated a substantial increase in kidney MDA levels, suggesting increased lipid peroxidation subsequent to oxidative stress. However, HDL administration produced a significant reduction in MDA levels. In our study when all groups were compared histological; we observed significant decrease in congestion in arrangement of groups from Groups II to group V. In addition, it was noticed that PMNL and MNL infiltration for cortex and medulla had negative correlation with Echinacea doses. The other findings did not show any significant difference between groups but mild decreases in tubular structures were observed in Group V. When we compared all groups; parenchymal focal necrotic area were not seen in any group. Caryolysis of hepatic nucleus, picnosis, loss of intercellular border and damage in hepatic cords were similar for all groups. But when Echinacea dose increased, congestion, hepatic

vacuolization, PMNL infiltration had decreased. There was a negative correlation with Echinacea dose. Karabiga's (2007) histological examination showed that aortic IR significantly increased while aprotinin significantly decreased the parameters of focal necrosis in glomerulus, dilatation of Bowman's capsule, necrosis in tubular epithelium, tubular dilatation and congestion of blood vessels. Aortic IR also significantly increased while aprotinin decreased the parameters of degeneration of tubular epithelium and interstitial inflammatory infiltration. Singh et al. (2004) observed that the histopathological changes in I/R rats showed tubular cell swelling, interstitial edema, tubular dilatation, hyaline casts and moderate to severe necrosis. Treatment with carvedilol preserved the normal morphology of the kidney. Also they showed that the kidneys of untreated ischemic rats showed tubular cell swelling, cellular vacuolization, pyknotic nuclei, medullary congestion and moderate to severe necrosis. Pre-treatment with low-dose of cyclosporine preserved the normal morphology of the kidney and showed normal glomeruli except for slight edema of the tubular cells (Singh et al., 2005). Liao et al. (2010) mentioned that augmenter of liver regeneration

(ALR), which is expressed in both the liver and kidney, and recently, was also found to be an important intracellular survival factor for hepatocytes effectively reduces tubular injury and ameliorates the impairment of renal function. The protective effect of ALR is associated with enhancement of renal tubular cell regeneration.

As seen, there are a lot of studies which examined the effects of the different antioxidants on renal I/R injury. These studies revealed different results for enzymatic activities and severe histopathological findings. Our results are in concordance with some of them but not similar to some of them. As a result, this shows us that it is necessary to make a lot of study on antioxidants for escaping from the speculations about antioxidants such as natural substances. In our study, this may reflect the fact that different doses of Echinacea may not be beneficial in decreasing oxidative injury. These results suggested that Echinacea may be effective in preventing oxidative injury.

Conflict of interest

The authors declare that they have no conflict of interest.

REFERENCES

- Agnew LL, Guffogg SP, Matthias A, Lehmann RP, Bone KM, Watson K (2005). Echinacea intake induces an immune response through altered expression of leucocyte hsp70, increased white cell counts and improved erythrocyte antioxidant defenses. *J. Clin. Pharm. Ther.*, 30: 363-369.
- Aherne SA, Kerry JP, O'Brien NM (2007). Effects of plant extracts on antioxidant status and oxidant-induced stress in Caco-2 cells. *Br. J. Nutr.*, 97: 321-328.
- de Groot H, Rauen U (2007). Ischemia-reperfusion injury: processes in pathogenetic networks: a review. *Transplant. Proc.*, 39: 481-484.
- Emre MH, Erdogan H, Fadillioglu E (2006). Effect of BQ-123 and Nitric Oxide Inhibition on Liver in Rats after Renal Ischemia-Reperfusion Injury. *Ge. Physio. Biophys.*, 25: 195-206.
- Gökçe A, Oktar S, Yönden Z, Aydın M, İlhan S, Ozkan OV, Davarci M, Yalçinkaya FR (2009). Protective Effect of Caffeic Acid Phenethyl Ester on Cyclosporine A-Induced Nephrotoxicity in Rats. *Ren. Fail.*, 31: 843-847.
- Goth LA (1991). Simple method for determination of serum CAT activity and revision of reference range. *Clin. Chim. Acta.*, 196: 143-152.
- Gulec B, Coskun K, Yigitler C, Yigit T, Aydın A, Oner K (2008). Ischemia-Reperfusion Injury in the Liver During Renal Transplantation: Does Perfusion Solution Play Any Role? *Transplant. Proc.*, 40: 59-62.
- Hosseini F, Naseri MKG, Badavi M, Ghaffari MA, Shahbazian H, Rashidi I (2010). Effect of beta carotene on lipid peroxidation and antioxidant status following renal ischemia/reperfusion injury in rat. *Scand. J. Clin. Lab. Invest.*, 70: 259-263.
- Karabiga M, Kiris I, Yilmaz N, Altuntas R, Karahan N, Okutan H (2007). The Effect of Aprotinin on Renal Injury In An Experimental Model Of Aortic Ischemia-Reperfusion *Turkish J. Vasc. Surg.*, 16: 9-18.
- Liao XH, Zhang L, Liu Q, Sun H, Peng CM, Guo H (2010). Augmenter of liver regeneration protects kidneys from ischemia/reperfusion injury in rats. *Nephrol. Dial. Trans.*, 25: 2921-2929.
- Lien YH, Lai LW, Silva AL (2003). Pathogenesis of renal ischemia/reperfusion injury: lessons from knockout mice. *Life Sci.*, 74:543-552.
- Liu CZ, Abbasi BH, Gao M, Murch SJ, Saxena PK (2006). Caffeic Acid Derivatives Production by Hairy Root Cultures of Echinacea purpurea. *Agric. Food Chem.*, 54: 8456-8460.
- Masteikova R, Muselik J, Bernatoniene J, Bernatoniene R (2007). Antioxidative activity of Ginkgo, Echinacea, and Ginseng tinctures. *Medicina (Kaunas)*, 43: 306-309.
- Mihara M, Uchiyama M (1978). Determination of malonaldehyde precursor in tissues by thiobarbituric acid test. *Anal. Biochem.*, 86: 271-278.
- Riedemann NC, Ward PA (2003). Complement in ischemia reperfusion injury. *Am. J. Pathol.*, 162: 363-367.
- Singh D, Chander V, Chopra K (2004). Carvedilol attenuates ischemia/reperfusion induced oxidative renal injury in rats. *Fundam. Clin. Pharmacol.*, 18: 627-634.
- Singh D, Chander V, Chopra K (2005). Cyclosporine protects against ischemia/reperfusion injury in rat kidneys. *Toxicol.*, 207: 339-347.
- Thiemermann C, Patel NSA, Kvale EO, Cockerill GW, Brown PAJ, Stewart KN, Cuzzocrea S, Britti D, Mota-Filipe H, Chatterjee PK (2003). High Density Lipoprotein (HDL) Reduces Renal Ischemia/Reperfusion Injury. *J. Am. Soc. Nephrol.*, 14: 1833-1843.
- Wang BY, Li QX, J, Xie XF, Ao Y, Xun Y (2009). Hepatotoxicity and gene expression down-regulation of CYP isozymes caused by renal ischemia/reperfusion in threat. *Exp. Toxicol. Pathol.*, 61: 169-176.