

Full Length Research Paper

Gastroprotective activity of mirtazapine, escitalopram and venlafaxine in depressed rats

Sally A. El-Awdan¹ and Hala F. Zaki^{2*}

¹Department of Pharmacology, National Research Centre, Dokki, Cairo, Egypt.

²Department of Pharmacology & Toxicology, Faculty of Pharmacy, Cairo University, Egypt.

Accepted 10 October, 2013

The study investigated the gastro-protective effects of certain antidepressants in relation to ranitidine on indomethacin-induced ulcer in depressed rats. Animals were divided into 6 groups (n = 8). Induction of depression was done by clonidine (0.8 mg/kg; i.p.) for 10 days in all groups except the 1st one (normal control). Depressive-like behavior was confirmed by increased immobility time in forced swimming test. Groups 1 and 2 received saline (normal and depressed controls, respectively). Groups 3 to 6 received p.o. mirtazapine (10 mg/kg), escitalopram (10 mg/kg), venlafaxine (20 mg/kg) and ranitidine (50 mg/kg), respectively for 30 days. After the last treatment, gastric ulcer was induced using indomethacin (25 mg/kg; p.o.) in groups 2 to 6. An additional group received indomethacin alone (control indomethacin). Animals were sacrificed and ulcer scores were determined. Part of the stomach was preserved for histopathologic studies while the other part was used for determination of reduced glutathione (GSH), malondialdehyde (MDA), nitric oxide (NO), tumor necrosis factor-alpha (TNF- α) and interleukin-10 (IL-10) contents. Pretreatment with all antidepressants used ameliorated indomethacin-induced changes in rat stomach. Biochemical findings were supported by histologic studies. In conclusion, the observed gastroprotective effects of mirtazapine, escitalopram and venlafaxine are possibly mediated by modulation of inflammatory cytokines and antioxidant effects.

Key words: Mirtazapine, escitalopram, venlafaxine, depression, indomethacin.

INTRODUCTION

Gastric ulcer is a multifactorial etiological disease involving depression, stress and production of reactive oxygen species (ROS) as major factors (Kwiecien et al., 2012; Goodwin et al., 2013). An increased vulnerability to depression (Pare, 1989) in experimental animals is paralleled with ulcer development and the same occurs in humans (Sjodin et al., 1985). Interestingly, certain antidepressants, such as duloxetine, amitriptyline, fluoxetine, were shown to reduce stress ulcer formation, perhaps to a greater extent than that seen with traditional therapies

such as cimetidine and antacids (Dajani et al., 2003; Olden, 2005; Bilici et al., 2009).

Mirtazapine, escitalopram and venlafaxine are extensively used antidepressants in clinical practice. Mirtazapine, a norepinephrine and specific serotonin antidepressant, enhances both serotonin (5-HT) and norepinephrine (NE) neurotransmission (Haddjeri et al., 1996). Escitalopram is the S-enantiomer of the racemic selective serotonin reuptake inhibitor compound citalopram with reported marked antidepressant and

anxiolytic activities (Sanchez et al., 2003). Venlafaxine inhibits the reuptake of 5-HT, NE and dopamine. Although its mechanism of action is similar to the tricyclic antidepressants (TCAs) drugs; it acts more specifically at those receptors and does not bind to the receptors responsible for the side effects of TCAs (Adelman et al., 2000).

Chronic inflammation and oxidative stress have been implicated in the pathophysiology of major depressive disorder (MDD) (Berk et al., 2011). MDD is accompanied by activation of inflammatory pathways, reflected by an increased levels of inflammatory cytokines, such as interleukin-1beta, interleukin-2, interleukin-6, interferon-gamma and tumor necrosis factor-alpha (TNF- α) (Maes, 1999).

The current study aimed to examine the possible anti-ulcer effect of mirtazapine, escitalopram and venlafaxine in indomethacin induced ulcer in depressed rats and to compare their effects with that of ranitidine, a well-known H₂ blocker. Indomethacin-induced gastric ulcer model has been chosen as it produces higher gastric damage in rats when compared to other non-steroidal anti-inflammatory drugs (NSAIDs) (Takeuchi et al., 2005). It seemed also important to investigate the effects of the chosen agents on certain factors known to be involved in ulcer and depression pathophysiology as oxidative stress biomarkers as well as production of pro-inflammatory and anti-inflammatory cytokines.

MATERIALS AND METHODS

Animals

Adult male albino Wistar rats weighing 130 to 160 g between 10 to 12 weeks age were obtained from the animal house colony of the National Research Center. The animals were housed under standard light, temperature, and room humidity conditions during the study. Animal experiments were performed in accordance with guidelines for the use and care of laboratory animals of the Ethics Committee of Faculty of Pharmacy, Cairo University.

Chemicals

All chemicals for laboratory experimentation were purchased from Sigma Chemical (Germany). Indomethacin, mirtazapine, escitalopram, venlafaxine and ranitidine were obtained from Khahira (Egypt), Novartis (Egypt), Lundbeck (Denmark), Wyeth (USA) and Pharco (Egypt) companies, respectively. Drugs were prepared as suspensions in 1% tween 80 and orally administered.

Experimental design

Rats were divided into 6 groups (n = 8). Induction of depression was done by i.p. injection with clonidine (0.8 mg/kg) (Enginar and Eroglu, 1990) once daily for 10 days in all groups except the 1st one which received saline i.p. (normal control). From 10th day

onwards, after the confirmation of depression by forced swimming test (FST), groups 3 to 6 were orally treated with mirtazapine (10 mg/kg) (Ji et al., 2012), escitalopram (10 mg/kg) (Saglam et al., 2008), venlafaxine (20 mg/kg) (Abdel-Wahab and Salama, 2011) and ranitidine (50 mg/kg) (Cayci and Dayioglu, 2009), respectively for 30 days. The 1st two groups received 1% tween 80 (p.o.) and served as normal and depressed control groups, respectively. Rats were subjected again to FST after the last dose of antidepressants. Thereafter, groups 2 to 6 in addition to a 7th group (indomethacin control) received 25 mg/kg indomethacin p.o. (Dengiz et al., 2013). Six hours later, all rats were sacrificed using a high dose of thiopental sodium (50 mg/kg, i.p.), the stomachs were excised and gastric erosions on the surfaces of the stomachs were examined macroscopically for mucosal necrotic lesions, red streaks and red erosions (Mozsik et al., 1982). Total lesions number was counted and the severity of lesions was determined based on the following scores:

- 0 = No ulcer;
- 1 = Lesion size < 1 to 2 mm;
- 2 = Lesion of size 1 to 2 mm;
- 4 = Lesion of size 3 to 4 mm.

Part of each stomach was preserved in 10% formalin for histopathologic examination and the remaining part was used to prepare 10% homogenate in phosphate buffer. The prepared homogenates were used for estimation of stomach contents of lipid peroxides, reduced glutathione (GSH), nitric oxide (NO), TNF- α and interleukin-10 (IL-10).

Forced swimming test

Depression-like behavior in FST was assessed as previously described (Cryan et al., 2001). Rats were individually placed in a transparent plexi-glass cylinder. The latency to immobility was recorded. Immobility was defined as the total absence of movement except slight motions to maintain the head above the water (Cryan et al., 2002). At the end of the experiment, rats were dried and placed back into their home cage with littermates.

Biochemical and histologic analysis

Lipid peroxides were determined as thiobarbituric acid reactive substances (TBARS) using malondialdehyde (MDA) as a reference according to the method described by Mihara and Uchiyama (1978) and expressed as nmol/g wet tissue. GSH content was determined using Ellman's reagent according to the method of Beutler et al. (1963) and expressed as mg/g wet tissue. NO content was determined as total nitrate/nitrite (NO_x) using Griess reagent according to the method described by Miranda et al. (2001) and expressed as μ M/g wet tissue. Stomach contents of TNF- α and IL-10 were estimated using rat specific immunoassay kit (Biosource, USA) and expressed as pg/g wet tissue. Tissue samples preserved for histopathologic examination were fixed in 10% formalin and used to prepare paraffin blocks. Sections of 5 μ m were obtained and stained with Hematoxylin and Eosin (H & E). Images were captured and processed using Adobe Photoshop (version 8).

Statistical analysis

Values were expressed as means \pm standard error (SE). Results of ulcer number and severity were analyzed using Kruskal-Wallis non-

Table 1. Effects of 30 days administration of mirtazapine, escitalopram, venlafaxine and ranitidine on immobility time of depressed rats in forced swimming test (FST).

Group	Immobility time	
	Day 0	Day 30
Normal	1.42 [®] ±0.28	1.61±0.24
Control	2.73*±0.09	3.13*±0.15
Depressed rats		
Mirtazapine (10 mg/kg)	2.58*±0.20	2.05 [®] ±0.16
Escitalopram (10 mg/kg)	2.86*±0.14	1.67 [®] ±0.10
Venlafaxine (20 mg/kg)	2.88*±0.10	1.05 [®] ±0.15
Ranitidine (50 mg/kg)	2.68*±0.16	2.88*±0.10

Induction of depression was done by i.p. administration of clonidine (0.8 mg/kg) for 10 successive days. FST was performed after the last dose of clonidine (day 0) and after the last dose of test agents (day 30). Values are means ± SE of 8 rats. Statistical analysis was done by one way ANOVA followed by Tukey Kramer multiple comparisons test. *Significantly different from normal control group at *p* < 0.05. [®]Significantly different from control depressed group at *p* < 0.05.

parametric one way analysis of variance (ANOVA) followed by Mann Whitney multiple comparisons test. The results of the remaining experiments were analyzed using one way ANOVA followed by Tukey Kramer multiple comparisons test. *P* < 0.05 was accepted as being significant in all types of statistical tests. Graph Pad Software InStat (version 2) was used to carry out these statistical tests.

RESULTS

Effects of mirtazapine, escitalopram, venlafaxine and ranitidine on immobility time of depressed rats in forced swimming test

The results depicted in Table 1 show that clonidine-induced depression increased immobility time of rats in FST when compared to the normal control group. Administration of mirtazapine (10 mg/kg), escitalopram (10 mg/kg) and venlafaxine (20 mg/kg) for 30 days decreased the immobility time of depressed rats by 34.50, 46.64 and 66.45%, respectively when compared to control group. On the other hand, administration of ranitidine (50 mg/kg) did not significantly change immobility time when compared to control depressed group (Table 1).

Effects of mirtazapine, escitalopram, venlafaxine and ranitidine on gastric ulcer number and severity induced by indomethacin in depressed rats

Macroscopic lesions with evident borderlines in various forms and sizes were dispersed irregularly on all stomach

Table 2. Effects of 30 days administration of mirtazapine, escitalopram, venlafaxine and ranitidine on gastric ulcer number and severity induced by indomethacin in depressed rats.

Groups	Score	
	Ulcer number	Ulcer severity
Normal	-	-
Indomethacin	12.50*±0.89	18.80*±1.51
Depressed + indomethacin		
Control	13.00*±1.53	20.30*±2.22
Mirtazapine (10 mg/kg)	3.50 [®] ±0.43	6.17* [®] ±1.66
Escitalopram (10mg/kg)	5.00* [®] ±1.29	5.83* [®] ±0.62
Venlafaxine (20 mg/kg)	3.17 [®] ±0.91	3.33 [®] ±0.21
Ranitidine (50 mg/kg)	2.17 [®] ±0.28	2.33 [®] ±0.21

Induction of depression was done by i.p. administration of clonidine (0.8 mg/kg) for 10 successive days. Treatment with test agents started following induction of depression. Gastric ulcer was induced by oral administration of indomethacin (20 mg/kg) after the last dose of test agents. Values are means ± SE of 8 rats. Statistical analysis was done by Kruskal-Wallis non-parametric one way ANOVA followed by Mann Whitney multiple comparisons test. *Significantly different from normal control group at *p* < 0.05. [®]Significantly different from control indomethacin group at *p* < 0.05.

surfaces of untreated rats receiving indomethacin (control indomethacin and control depressed). Similarly, hyperemia was more evident in either groups when compared to the groups treated with ranitidine or any of the antidepressants used (Table 2). The severity of hyperemia paralleled with an increase in ulcer numbers. As seen in Table 2, treatment with mirtazapine (10 mg/kg), escitalopram (10 mg/kg), venlafaxine (20 mg/kg) and ranitidine (50 mg/kg) decreased ulcer number by 72, 60, 74.64, and 82.64%, respectively as compared to control indomethacin group.

Effects of mirtazapine, escitalopram, venlafaxine and ranitidine on stomach contents of malondialdehyde, reduced glutathione and total nitrate/nitrite in depressed rats with indomethacin-induced gastric ulcer

Indomethacin administration significantly decreased stomach contents of GSH and NO_x by 30.2 and 84.25%, respectively parallel to an increase in MDA content by 65.65% when compared to the normal group. Similarly, administration of indomethacin in depressed rats decreased stomach contents of GSH and NO_x by 31.5 and 68%, respectively parallel to an increase in MDA content by 62.51%. Treatment of depressed rats with mirtazapine, venlafaxine, escitalopram and ranitidine protected against indomethacin-induced depletion of

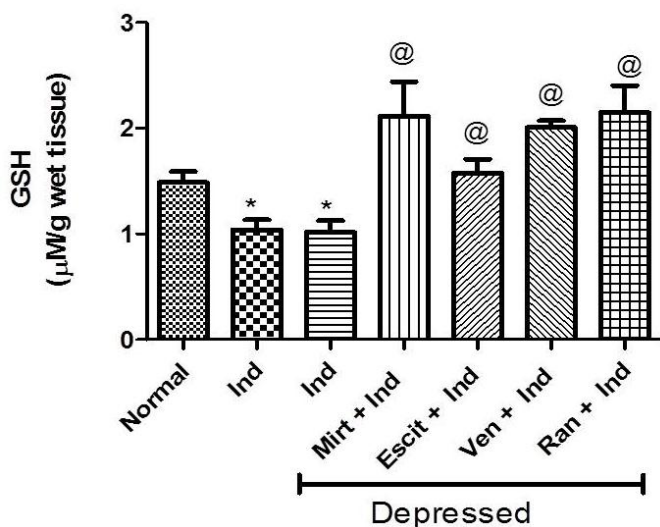


Figure 1. Effects of 30 days administration of mirtazapine (10 mg/kg), escitalopram (10 mg/kg), venlafaxine (20 mg/kg) and ranitidine (50 mg/kg) on stomach reduced glutathione (GSH) content of depressed rats with indomethacin-induced ulcer. Induction of depression was done by i.p. administration of clonidine (0.8 mg/kg) for 10 successive days. Treatment with test agents started following induction of depression. Gastric ulcer was induced by oral administration of indomethacin (20 mg/kg) after the last dose of test agents. Ind: indomethacin; Mirt: mirtazapine; Escit: escitalopram; Ven: Venlafaxine; Ran: ranitidine. Values are means \pm SE of 8 rats. Statistical analysis was done by one way ANOVA followed by Tukey Kramer multiple comparisons test. *Significantly different from normal control group at $p < 0.05$. @Significantly different from control indomethacin group at $p < 0.05$.

stomach GSH content (Figure 1). Similarly, treatment with venlafaxine and ranitidine prevented the decrease in NO_x stomach content induced by indomethacin (Figure 2). In addition, both mirtazapine and ranitidine prevented indomethacin-induced lipid peroxidation in stomach tissues (Figure 3).

Effects of mirtazapine, escitalopram, venlafaxine and ranitidine on stomach contents of tumor necrosis factor-alpha and interleukin-10 in depressed rats with indomethacin-induced gastric ulcer

Indomethacin administration in normal and depressed rats significantly increased stomach TNF- α contents by 44.45 and 42.51%, respectively when compared to the normal control group (Figures 4 and 5). Meanwhile, IL-10 content decreased in both groups by 28.11 and 36%, respectively when compared to the normal group. Treatment of depressed rats with any of the test agents prevented indomethacin-induced increase in stomach TNF- α content. Similarly, all treatments except escitalo-

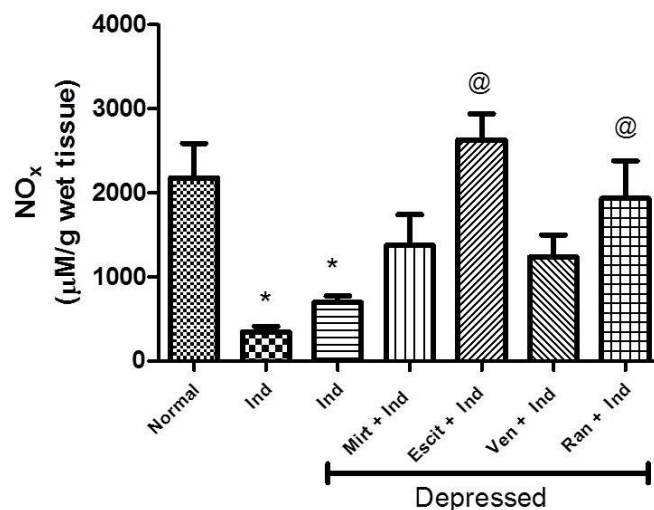


Figure 2. Effects of 30 days administration of mirtazapine (10 mg/kg), escitalopram (10 mg/kg), venlafaxine (20 mg/kg) and ranitidine (50 mg/kg) on stomach total nitrate/nitrite (NO_x) content of depressed rats with indomethacin-induced ulcer. Induction of depression was done by i.p. administration of clonidine (0.8 mg/kg) for 10 successive days. Treatment with test agents started following induction of depression. Gastric ulcer was induced by oral administration of indomethacin (20 mg/kg) after the last dose of test agents. Ind: indomethacin; Mirt: mirtazapine; Escit: escitalopram; Ven: Venlafaxine; Ran: ranitidine. Values are means \pm SE of 8 rats. Statistical analysis was done by one way ANOVA followed by Tukey Kramer multiple comparisons test. *Significantly different from normal control group at $p < 0.05$. @Significantly different from control indomethacin group at $p < 0.05$.

pram prevented the decrease in IL-10 content induced by indomethacin.

Effects of mirtazapine, escitalopram, venlafaxine and ranitidine on histopathologic changes in stomach of depressed rats with indomethacin-induced gastric ulcer

Administration of indomethacin in normal or depressed untreated rats caused marked necrosis and hemorrhage in mucosal layer coupled with edema of sub-mucosal layer. Treatment of depressed rats with ranitidine or any of the used antidepressants ameliorated indomethacin-induced histologic changes (Figure 6).

DISCUSSION

FST remains one of the most used tools for assessing pharmacological antidepressant activity (Petit-Demouliere et al., 2005). Antidepressant treatments reduce immobility time of rats in this test. Indeed in the current

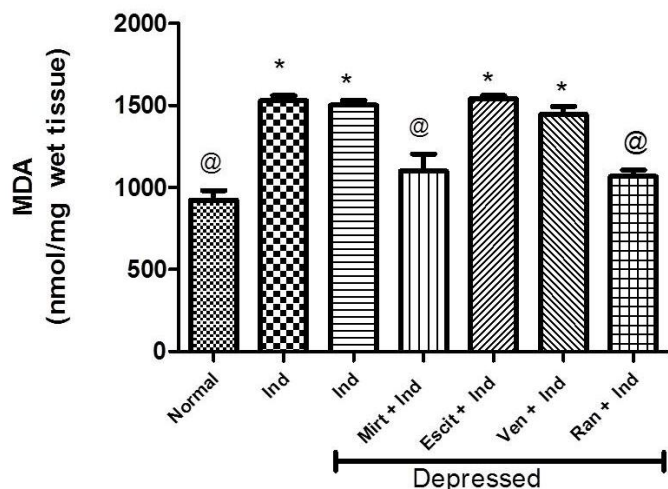


Figure 3. Effects of 30 days administration of mirtazapine (10 mg/kg), escitalopram (10 mg/kg), venlafaxine (20 mg/kg) and ranitidine (50 mg/kg) on stomach malondialdehyde (MDA) content of depressed rats with indomethacin-induced ulcer. Induction of depression was done by i.p. administration of clonidine (0.8 mg/kg) for 10 successive days. Treatment with test agents started following induction of depression. Gastric ulcer was induced by oral administration of indomethacin (20 mg/kg) after the last dose of test agents. Ind: indomethacin; Mirt: mirtazapine; Escit: escitalopram; Ven: Venlafaxine; Ran: ranitidine. Values are means \pm SE of 8 rats. Statistical analysis was done by one way ANOVA followed by Tukey Kramer multiple comparisons test. *Significantly different from normal control group at $p < 0.05$. @Significantly different from control indomethacin group at $p < 0.05$.

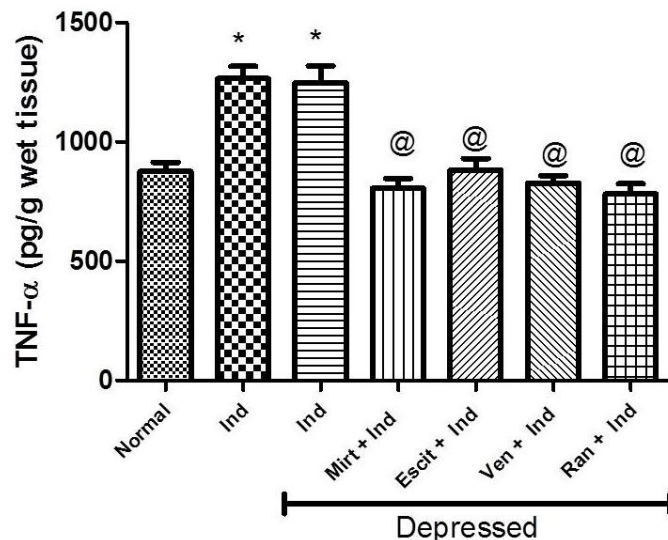


Figure 4. Effects of 30 days administration of mirtazapine (10 mg/kg), escitalopram (10 mg/kg), venlafaxine (20 mg/kg) and ranitidine (50 mg/kg) on stomach tumor necrosis factor-alpha (TNF- α) content of depressed rats with indomethacin-induced ulcer. Induction of depression was done by i.p. administration of clonidine (0.8 mg/kg) for 10 successive days. Treatment with test agents started following induction of depression. Gastric ulcer was induced by oral administration of indomethacin (20 mg/kg) after the last dose of test agents. Ind: indomethacin; Mirt: mirtazapine; Escit: escitalopram; Ven: Venlafaxine; Ran: ranitidine. Values are means \pm SE of 8 rats. Statistical analysis was done by one way ANOVA followed by Tukey Kramer multiple comparisons test. *Significantly different from normal control group at $p < 0.05$. @Significantly different from control indomethacin group at $p < 0.05$.

experiments, treatment of depressed rats for 30 days with mirtazapine, escitalopram or venlafaxine reduced immobility time of rats in FST. The present results are in accordance with other studies that revealed the effectiveness of escitalopram and venlafaxine in FST (Zomkowski et al., 2010).

The present results demonstrated that mirtazapine, escitalopram and venlafaxine displayed a significant reduction of the mucosal damage induced by indomethacin. The three antidepressants reduced ulcer numbers and severity as well as indomethacin-induced histopathologic injuries and their results were comparable to ranitidine, a well-known H₂ blocker used in treatment of gastric ulcers. Similar results were reported by Bilici et al. (2009), using mirtazapine in doses 15, 30 and 60 mg/kg. Similarly, Ji et al. (2012) reported anti-ulcer effects of mirtazapine (10 and 20 mg/kg) in gastric ulcer models induced by water-immersion plus restraint stress or reserpine. The gastroprotective effect of citalopram, an enantiomer of escitalopram, was also reported in stress and pyloric ligation mediated ulcers (Saxena and Singh, 2011).

Antidepressant drugs have been shown to produce antiulcer effects by reducing histamine secretion from

mast cells, inhibiting gastric acid secretion, and blocking leukotriene receptors (Hano et al., 1978). Moreover, Saxena and Singh (2011) mentioned that the protective effects of citalopram was related to increasing -SH groups, NO production and PGs.

In the current experiments, indomethacin administration resulted in increased lipid peroxidation manifested by increased stomach content of MDA, an end product of the process of lipid peroxidation parallel to reduced GSH content. The important primary factor in indomethacin-induced gastric damage is ROS mediated lipid peroxidation (Naito et al., 1998) coupled with reduced antioxidant defenses (Hassan et al., 1998). We investigated effects of mirtazapine (10 mg/kg), escitalopram (10 mg/kg) and venlafaxine (20 mg/kg) on stomach contents of GSH, MDA, and NO in indomethacin-induced ulcer in rats. Similarly, the effects of the chosen antidepressants on stomach content of TNF- α as a pro-inflammatory cytokine and IL-10, as an anti-inflammatory cytokine were assessed as an approach to investigate the mechanism behind their antiulcer effects. Treatment of depressed rats with mirtazapine or ranitidine prevented indomethacin-

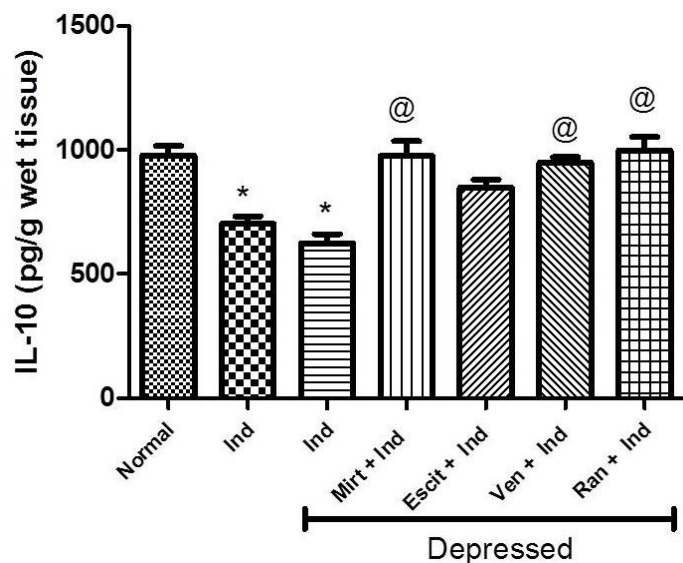


Figure 5. Effects of 30 days administration of mirtazapine (10 mg/kg), escitalopram (10 mg/kg), venlafaxine (20 mg/kg) and ranitidine (50 mg/kg) on stomach interleukin-10 (IL-10) content of depressed rats with indomethacin-induced ulcer. Induction of depression was done by i.p. administration of clonidine (0.8 mg/kg) for 10 successive days. Treatment with test agents started following induction of depression. Gastric ulcer was induced by oral administration of indomethacin (20 mg/kg) after the last dose of test agents. Ind: indomethacin; Mirt: mirtazapine; Escit: escitalopram; Ven: Venlafaxine; Ran: ranitidine. Values are means \pm SE of 8 rats. Statistical analysis was done by one way ANOVA followed by Tukey Kramer multiple comparisons test. *Significantly different from normal control group at $p < 0.05$. @Significantly different from control indomethacin group at $p < 0.05$.

induced lipid peroxidation and depletion in stomach GSH stores. Similarly, venlafaxine and escitalopram protected against indomethacin-induced GSH depletion, although stomach MDA contents were still elevated in both groups. In a study performed by Bilici et al. (2009), using mirtazapine was associated with similar protection against indomethacin-induced lipid peroxidation. Mirtazapine restored stomach content of GSH and activities of superoxide dismutase and catalase. Similarly, venlafaxine in doses of 5, 10 and 20 mg/kg/day for 21 days protected against stress-induced DNA oxidative damage in hippocampus of mice and reduced associated lipid peroxidation while increasing brain GSH and total antioxidant stores (Abdel-Wahab and Salama, 2011). Moreover, the protective effects of escitalopram were reported against depression-induced oxidative stress in rat brains (Eren et al., 2007).

The present findings indicate the important relationship between gastric GSH contents and ulcer severity. GSH detoxifies hydrogen peroxide and/or organic acids chemically; thus hydrogen peroxide accumulates in the

absence of GSH and in the presence of transition metals such as Fe and Cu, it reacts with superoxide anion to form hydroxyl radical, the most reactive and cytotoxic form of ROS (Dalle-Donne et al., 2003).

In the current study, gastric NO content was reduced by indomethacin administration. The present findings confirm the positive correlation between the decrease in NO content and the severity of gastric damage as previously reported (Lanas et al., 2000; Cadirci et al., 2007). NO, as a vasodilator, maintains gastric epithelium integrity by accelerating ulcer healing (Li et al., 2000) and modulating acid levels as well as gastric mucus secretion (Martin et al., 2001). Moreover, NO has also been reported to prevent membrane lipid peroxidation (Hogg and Kalyanaraman, 1999). Treatment with escitalopram or ranitidine, in the current study, increased gastric NO levels significantly when compared to control indomethacin group. The ability of ranitidine to increase stomach NO content in indomethacin-induced ulcer was previously reported and explained by its ability to increase constitutive nitric oxide synthase (Bayir et al., 2006). The noted effect of escitalopram on stomach NO content could be one of the factors responsible for its observed decrease of ulcer-index and ulcer severity induced by indomethacin. The effects of escitalopram on NO content could be mediated via increased synthesis of NO through nitric oxide synthases (NOS). Indeed, Saglam et al. (2008) reported increased NOS activity in brain of rats treated with escitalopram in doses of 2.5, 5 and 10 mg/kg.

Induction of indomethacin ulcer in normal or depressed rats was associated by increased stomach contents of TNF- α , a pro-inflammatory cytokine, parallel to decreased IL-10, an anti-inflammatory cytokine. This observation is consistent with previous observations showing the importance of TNF- α in the process of ulcer healing (Konturek et al., 2000). Indeed, TNF- α was shown to delay ulcer healing by inhibition of cell proliferation, angiogenesis and gastric microcirculation (Shimizu et al., 2000). Treatment with any of the three used antidepressants or ranitidine attenuated indomethacin-induced changes in stomach TNF- α and IL-10 contents except for escitalopram which did not significantly affect IL-10 content when compared to indomethacin control group.

The present findings find support in previous published literature. Ranitidine inhibited the production of TNF- α in monocytes stimulated with lipopolysaccharide *in vitro* (Okajima et al., 2002) and in stomach of rats subjected to pyloric ligation (Sood and Muthuraman, 2009). Mirtazapine was shown to reduce TNF- α expression in tumor-bearing mice (Fang et al., 2012) and to reduce TNF- α in brain of rats parallel to IL-10 up-regulation (Zhu et al., 2008). Venlafaxine was also shown to suppress TNF- α up-regulation and up-regulate IL-10 level in patients and experimental animals (Kubera et al., 2001;

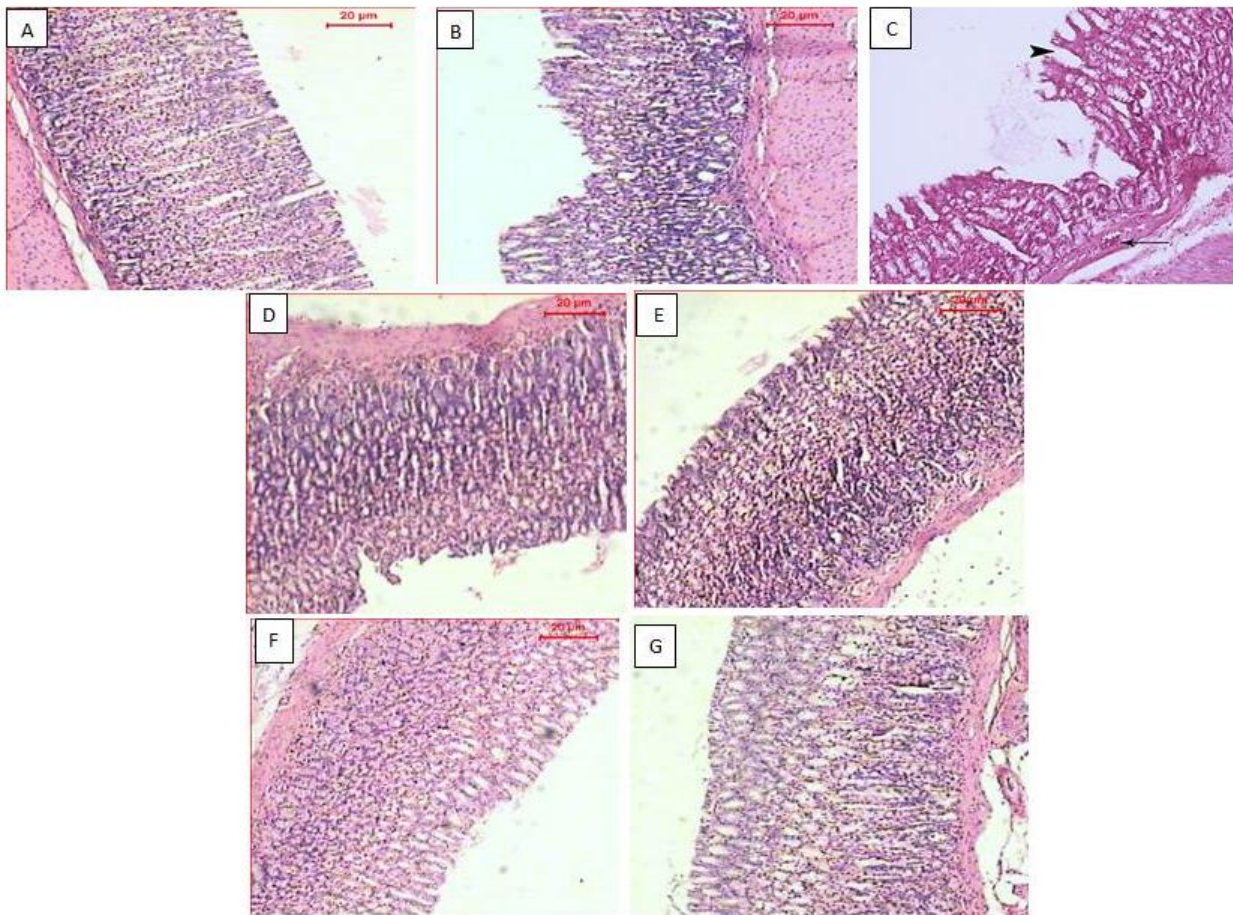


Figure 6. Effects of 30 days administration of mirtazapine (10 mg/kg), escitalopram (10 mg/kg), venlafaxine (20 mg/kg) and ranitidine (50 mg/kg) on stomach histopathologic changes of depressed rats with indomethacin-induced ulcer. (A): Stomach of normal control rat showing normal structure of stomach tissue; (B): Stomach of rat treated with indomethacin showing necrosis of the surface mucous cells and fundus gland, hemorrhage in mucosal layer and edema of submucosal layer; (C): Stomach of control depressed rat treated with indomethacin showing major injuries in mucosal layer, as well as necrosis of the surface mucous cells; (D): Stomach of depressed rats treated with indomethacin and mirtazapine showing necrosis of the surface mucous cells and fundus gland, hemorrhage in mucosal layer; (E): Stomach of depressed rat treated with indomethacin and escitalopram showing no obvious injuries in mucosal layer; (F): Stomach of depressed rats treated with indomethacin and venlafaxine showing no obvious injuries in the most of the mucosal layer. (G): Stomach of depressed rats treated with ranitidine showing regular and intact structure. (H & E; $\times 100$).

Li et al., 2013). Moreover, suppression of TNF- α was recognized as one of the antidepressant mechanisms of escitalopram (Bah et al., 2011; Powell et al., 2012). The current data indicate the important role played by TNF- α and IL-10 in the observed gastroprotective effects of mirtazapine, escitalopram and venlafaxine.

Conclusion

We report that mirtazapine, escitalopram and venlafaxine have antiulcer effects in depressed rats receiving indomethacin. The chosen antidepressants appear to

exert their antiulcer effects by activation of antioxidant mechanisms, inhibition of toxic oxidant mechanisms in stomach tissues in addition to their anti-inflammatory effects revealed by reducing TNF- α and increasing IL-10 contents. Histologic examination of stomach tissues confirmed the present biochemical findings.

ACKNOWLEDGMENT

The authors are very grateful to Dr. Abdul Razek Farrag, Professor of Pathology, National Research Center, for examining and interpreting histopathologic aspects of this

study.

REFERENCES

- Abdel-Wahab BA, Salama RH (2011). Venlafaxine protects against stress-induced oxidative DNA damage in hippocampus during antidepressant testing in mice. *Pharmacol. Biochem. Behav.* 100:59-65.
- Adelman LC, Adelman JU, Von Seggern R, Mannix LK (2000). Venlafaxine extended release (XR) for the prophylaxis of migraine and tension-type headache: A retrospective study in a clinical setting. *Headache.* 40(7):572-580.
- Bah TM, Benderdour M, Kaloustian S, Karam R, Rousseau G, Godbout R (2011). Escitalopram reduces circulating pro-inflammatory cytokines and improves depressive behavior without affecting sleep in a rat model of post-cardiac infarct depression. *Behav. Brain Res.* 225:243-251.
- Bayir Y, Odabasoglu F, Cakir A, Aslan A, Suleyman H, Halici M, Kazaz C (2006). The inhibition of gastric mucosal lesion, oxidative stress and neutrophil-infiltration in rats by the lichen constituent diffracta acid. *Phytomedicine.* 13: 584-590.
- Berk M, Kapczinski F, Andreatza AC, Dean OM, Giorlando F, Maes M, Yücel M, Gama CS, Dodd S, Dean B, Magalhães PV, Amminger P, McGorry P, Malhi GS (2011). Pathways underlying neuroprogression in bipolar disorder: focus on inflammation, oxidative stress and neurotrophic factors. *Neurosci. Biobehav. Rev.* 35:804-817.
- Beutler E, Duron O, Kelly BM (1963). Improved method for the determination of blood glutathione. *J. Lab. Clin. Med.* 61: 882-888.
- Bilici M, Ozturk C, Dursun H, Albayrak F, Saglam MB, Uyanik A, Gulaboglu M, Tekin SB (2009). Protective effect of mirtazapine on indomethacin-induced ulcer in rats and its relationship with oxidant and antioxidant parameters. *Dig Dis Sci.* 54: 1868-1875.
- Cadirci E, Suleyman H, Aksoy H, Halici Z, Ozgen U, Koc A, Ozturk N (2007). Effects of *Onosma armeniacum* root extract on ethanol-induced oxidative stress in stomach tissue of rats. *Chem. Biol. Interact.* 170:40-48.
- Cayci MK, Dayioglu H (2009). *Hypericum perforatum* extracts healed gastric lesions induced by hypothermic restraint stress in Wistar rats. *Saudi Med. J.* 30(6):750-754.
- Cryan JF, Dalvi A, Jin SH, Hirsch BR, Lucki I, Thomas SA (2001). Use of dopamine-beta-hydroxylase-deficient mice to determine the role of norepinephrine in the mechanism of action of antidepressant drugs. *J Pharmacol Exp Ther.* 298: 651-657.
- Cryan JF, Markou A, Lucki I (2002). Assessing antidepressant activity in rodents: recent developments and future needs. *Trends Pharmacol. Sci.* 23:238-245.
- Dajani EZ, Shahwan TG, Dajani NE (2003). Prostaglandins and brain-gut axis. *J. Physiol. Pharmacol.* 54:155-164.
- Dalle-Donne I, Rossi R, Giustarini D, Milzani A, Colombo R (2003). Protein carbonyl groups as biomarkers of oxidative stress. *Clin. Chim. Acta.* 329:23-38.
- Dengiz GO, Cadirci E, Yurdakan G (2013). Histopathologic evaluation of anti-ulcerogenic effect of montelukast in indomethacin-induced experimental ulcermodel. *Turk. J. Gastroenterol.* 24(2):88-92.
- Enginar N, Eroglu L (1990). The long-term clonidine treatment induced behavioral depression in rats. *Pol. J. Pharmacol. Pharm.* 42:409-415.
- Eren I, Naziroglu M, Demirdas A (2007). Protective effects of lamotrigine, aripiprazole and escitalopram on depression-induced oxidative stress in rat brain. *Neurochem. Res.* 32:1188-1195.
- Fang CK, Chen HW, Chiang IT, Chen CC, Liao JF, Su TP, Chieh-Yin T, Yosuke U, Jeng-Jong H (2012). Mirtazapine inhibits tumor growth via immune response and serotonergic system. *PLoS One.* 7: e38886.
- Goodwin RD, Talley NJ, Hotopf M, Cowles RA, Galea S, Jacobi F (2013). A link between physician-diagnosed ulcer and anxiety disorders among adults. *Ann. Epidemiol.* 23(4):189-192.
- Haddjeri N, Blier P, de Montigny C (1996). Effect of the alpha-2 adrenoceptor antagonist mirtazapine on the 5-hydroxytryptamine system in the rat brain. *J. Pharmacol. Exp. Ther.* 277(2):861-871.
- Hano J, Bugajski J, Wantuch C (1978). The effect of drugs interfering with biogenic amines metabolism on gastric secretion and resection-ulcers development in rats. *Pol. J. Pharmacol. Pharm.* 30:501-511.
- Hassan A, Martin E, Puig-Parellada P (1998). Role of antioxidants in gastric mucosal damage induced by indomethacin in rats. *Methods Find Exp. Clin. Pharmacol.* 20:849-854.
- Hogg N, Kalyanaraman B (1999). Nitric oxide and lipid peroxidation. *Biochim. Biophys. Acta.* 1411:378-384.
- Ji CX, Fan DS, Li W, Guo L, Liang ZL, Xu RM, Zhang JJ (2012). Evaluation of the anti-ulcerogenic activity of the antidepressants duloxetine, amitriptyline, fluoxetine and mirtazapine in different models of experimental gastric ulcer in rats. *Eur. J. Pharmacol.* 691:46-51.
- Konturek PC, Duda A, Brzozowski T, Konturek SJ, Kwiecien S, Drozdowicz D, Pajdo R, Meixner H, Hahn EG. (2000). Activation of genes for superoxide dismutase, interleukin-1beta, tumor necrosis factor-alpha, and intercellular adhesion molecule-1 during healing of ischemia-reperfusion-induced gastric injury, *Scand J. Gastroenterol.* 35:452-463.
- Kubera M, Lin AH, Kenis G, Bosmans E, van Bockstaele D, Maes M (2001). Anti-inflammatory effects of antidepressants through suppression of the interferon-gamma/interleukin-10 production ratio. *J. Clin. Psychopharmacol.* 21:199-206.
- Kwiecien S, Ptak-Belowska A, Krzysiek-Maczka G, Targosz A, Jasnos K, Magierowski M, Szczyrk U, Brzozowski B, Konturek SJ, Konturek PC, Brzozowski T (2012). Asymmetric dimethylarginine, an endogenous inhibitor of nitric oxide synthase, interacts with gastric oxidativemetabolism and enhances stress-induced gastric lesions. *J. Physiol Pharmacol.* 63(5):515-524.
- Lanas A, Bajador E, Serrano P, Fuentes J, Carreno S, Guardia J, Sanz M, Montoro M, Sáinz R (2000). Nitrovasodilators, low-dose aspirin, other nonsteroidal antiinflammatory drugs, and the risk of upper gastrointestinal bleeding. *N Engl J. Med.* 343:834-839.
- Li Y, Wang WP, Wang HY, Cho CH (2000). Intra-gastric administration of heparin enhances gastric ulcer healing through a nitric oxide-dependent mechanism in rats. *Eur. J. Pharmacol.* 399:205-214.
- Li Z, Qi D, Chen J, Zhang C, Yi Z, Yuan C, Wang Z, Hong W, Yu S, Cui D, Fang Y (2013). Venlafaxine inhibits the upregulation of plasma tumor necrosis factor-alpha (TNF-alpha) in the Chinese patients with major depressive disorder: a prospective longitudinal study. *Psychoneuroendocrinology* 38:107-114.
- Maes M (1999). Major depression and activation of the inflammatory response system. *Adv Exp Med Biol.* 461:25-46.
- Martin MJ, Jimenez MD, Motilva V (2001). New issues about nitric oxide and its effects on the gastrointestinal tract. *Curr Pharm. Des.* 7:881-908.
- Mihara M, Uchiyama M (1978). Determination of malonaldehyde precursor in tissues by thiobarbituric acid test. *Anal Biochem.* 86: 271-278.
- Miranda KM, Espey MG, Yamada K, Krishna M, Ludwick N, Kim S, Jourdeuil D, Grisham MB, Feelisch M, Fukuto JM, Wink DA et al. (2001). Unique oxidative mechanisms for the reactive nitrogen oxide species, nitroxyl anion. *J. Biol. Chem.* 276: 1720-1727.
- Mozsik G, Moron F, Javor T (1982). Cellular mechanisms of the development of gastric mucosal damage and of gastrocytoprotection induced by prostacyclin in rats. A pharmacological study. *Prostaglandins Leukot Med.* 9: 71-84.
- Naito Y, Yoshikawa T, Yoshida N, Kondo M (1998). Role of oxygen radical and lipid peroxidation in indomethacin-induced gastric mucosal injury. *Dig. Dis. Sci.* 43:30S-34S.
- Okajima K, Harada N, Uchiba M (2002). Ranitidine reduces ischemia/reperfusion-induced liver injury in rats by inhibiting neutrophil activation. *J. Pharmacol. Exp. Ther.* 301:1157-1165.
- Olden KW (2005). The use of antidepressants in functional gastrointestinal disorders: new uses for old drugs. *CNS Spectr.* 10:891-896.

- Pare WP (1989). Stress ulcer susceptibility and depression in Wistar Kyoto (WKY) rats. *Physiol Behav.* 46:993-998.
- Petit-Demouliere B, Chenu F, Bourin M (2005). Forced swimming test in mice: a review of antidepressant activity. *Psychopharmacology (Berl)* 177:245-255.
- Powell TR, Schalkwyk LC, Heffernan AL, Breen G, Lawrence T, Price T, Farmer AE, Aitchison KJ, Craig IW, Danese A, Lewis C, McGuffin P, Uher R, Tansey KE, D'Souza UM (2012). Tumor necrosis factor and its targets in the inflammatory cytokine pathway are identified as putative transcriptomic biomarkers for escitalopram response. *Eur Neuropsychopharmacol.* 12:273-278.
- Saglam E, Ates LE, Kayir H, Celik T, Terzioglu B, Uzbay T (2008). Escitalopram increases cortical nitric oxide synthase (NOS) in rat brain during ethanol withdrawal. *Nitric Oxide.* 19:284-288.
- Sanchez C, Bergqvist PB, Brennum LT, Gupta S, Hogg S, Larsen A, Wiborg O (2003). Escitalopram, the S-(+)-enantiomer of citalopram, is a selective serotonin reuptake inhibitor with potent effects in animal models predictive of antidepressant and anxiolytic activities. *Psychopharmacology (Berl)*. 167(4):353-362.
- Saxena B, Singh S (2011). Investigations on gastroprotective effect of citalopram, an antidepressant drug against stress and pyloric ligation induced ulcers. *Pharmacol. Rep.* 63:1413-1426.
- Shimizu N, Watanabe T, Arakawa T, Fujiwara Y, Higuchi K, Kuroki T (2000). Pentoxifylline accelerates gastric ulcer healing in rats: roles of tumor necrosis factor alpha and neutrophils during the early phase of ulcer healing. *Digestion* 61: 157-164.
- Sjodin I, Svedlund J, Dotevall G, Gillberg R (1985). Symptom profiles in chronic peptic ulcer disease. A detailed study of abdominal and mental symptoms. *Scand J Gastroenterol.* 20: 419-427.
- Sood S, Muthuraman A (2009). Activity of tacrolimus: an immunosuppressant, in pyloric ligation-induced peptic ulcer in the rat. *Yakugaku Zasshi.* 129: 1523-1528.
- Takeuchi K, Tanaka A, Hayashi Y, Yokota A (2005). COX inhibition and NSAID-induced gastric damage--roles in various pathogenic events. *Curr. Top. Med. Chem.* 5:475-486.
- Zhu J, Wei X, Feng X, Song J, Hu Y, Xu J (2008). Repeated administration of mirtazapine inhibits development of hyperalgesia/allodynia and activation of NF-kappaB in a rat model of neuropathic pain. *Neurosci Lett.* 433:33-37.
- Zomkowski AD, Engel D, Gabilan NH, Rodrigues AL (2010). Involvement of NMDA receptors and L-arginine-nitric oxide-cyclic guanosine monophosphate pathway in the antidepressant-like effects of escitalopram in the forced swimming test. *Eur Neuropsychopharmacol.* 20:793-801.