

*Full Length Research Paper*

# Effect of atorvastatin on aldosterone induced myocardial fibrosis in a rat model and its potential mechanism

Li-kun Ma\*, Li-feng He, Bing-yu Zhang and Jing-sheng Hua

Anhui Provincial Hospital, Hefei 230001, China.

Accepted 28 February, 2011

In this study, we investigated the effects of atorvastatin on aldosterone induced myocardial fibrosis in rat model and its potential mechanism. Forty male rats underwent right nephrectomy, and then, were given free access to 1% NaCl for 4 weeks. During this period, rats were randomly divided into 4 groups; vehicle group (CON group: Subcutaneous injection of saline); aldosterone treated group (ALD group: Aldosterone 18  $\mu\text{g}\cdot\text{d}^{-1}$  subcutaneously); spironolactone plus aldosterone treated group (SPI+ALD group: Aldosterone 18  $\mu\text{g}\cdot\text{d}^{-1}$  subcutaneously plus spironolactone 20  $\text{mg}\cdot\text{kg}^{-1}\cdot\text{d}^{-1}$  intravenously); atorvastatin plus aldosterone treated group (ATO+ALD group: Aldosterone 18  $\mu\text{g}\cdot\text{d}^{-1}$  subcutaneously plus Atorvastatin 50  $\text{mg}\cdot\text{kg}^{-1}\cdot\text{d}^{-1}$  intravenously). Blood pressure was measured through catheterization. Myocardial collagen volume fraction (CVF) and perivascular collagen area (PVCA) were analyzed by Sirius-Red staining. The expressions of platelet-derived growth factor (PDGF-A, PDGF-B), platelet-derived growth factor receptor (PDGFR- $\alpha$ , PDGFR- $\beta$ ), ectodermal dysplasia-1 (ED-1) and myocardial osteopontin were determined. Mean arterial blood pressure in rats receiving drug treatment was markedly elevated compared with the CON group ( $P < 0.01$  or  $P < 0.05$ ). Rats in ALD group had pronounced myocardial fibrosis and dramatically increased CVF and PVCA when compared with the other three groups. There were no significant differences between SPI+ALD group and ATO+ALD group in the CVF and PVCA. The expressions of PDGF-A, PDGF-B, PDGFR- $\alpha$ , ED-1 and OPN in the ALD group were markedly higher than in the other three groups ( $P < 0.01$  or  $P < 0.05$ ), and no significant difference was observed between SPI+ALD group and ATO+ALD group in the expressions of PDGF-A, PDGF-B, PDGFR- $\alpha$  and OPN. But the ATO+ALD group had lower ED-1 expression than SPI+ALD ( $P < 0.05$ ). Furthermore, there was no significant difference in the PDGFR- $\beta$  expression among four groups. Atorvastatin may attenuate myocardial fibrosis, induced by aldosterone, in which the reduced macrophage infiltration and alleviated expressions of inflammatory cytokines, and platelet-derived growth factors and their receptors play critical roles.

**Key words:** Atorvastatin, aldosterone, myocardial fibrosis, platelet-derived growth factor.

## INTRODUCTION

Myocardial fibrosis is an important pathological feature of several heart diseases at the end stage. To prevent and reverse myocardial fibrosis has been a critical step in the treatment and prevention of arrhythmia, heart failure, sudden cardiac death and other serious cardiovascular

events. It is evidenced that atorvastatin (ATO) can exert anti-inflammatory effect and reverse myocardial remodeling (Kang et al., 2007), but its role in aldosterone (ALD) induced myocardial fibrosis remains still poorly understood. In the present study, an ALD induced myocardial fibrosis was established, and the anti-fibrotic effect of ATO was investigated. We detected the infiltration of monocytes and macrophages, and expressions of osteopontin, platelet-derived growth factor (PDGF) and their receptors in myocardial fibrosis rats

\*Corresponding author. E-mail: [docma96@sina.com](mailto:docma96@sina.com). Tel: +86-551-2283114. Fax: +86-551-2283409.

after ATO treatment.

## MATERIALS AND METHODS

### Grouping and modeling

A total of 40 male Sprague Dawley (SD) rats weighing 150 to 200 g were purchased from the Animal Center of the Affiliated Provincial Hospital of Anhui Medical University and housed in a clean-grade environment. These rats were intraperitoneally anesthetized with 10% chloral hydrate and underwent right nephrectomy. One week after surgery, these rats were given free access to 1% sodium chloride orally and randomly divided into 4 groups: 1) control group (CON); rats received subcutaneous injection of normal saline (n = 10); 2) ALD group; rats subcutaneously received ALD (18 µg/d) (n = 10); 3) spironolactone plus ALD group (SPI+ALD); rats received ALD (18 µg/d) subcutaneously and SPI (20 mg/kg/d) intragastrically (n = 10); 4) ATO+ALD group; rats received ALD (18 µg/d) subcutaneously and ATO (50 mg/kg/d) intragastrically (n = 10). In addition, rats in the CON group and ALD group also intragastrically received normal saline with the volume similar to that in the other two groups. The treatment was performed for 4 weeks. All experimental procedures were approved by the Institutional Animal Care and Use Committee of Anhui Medical University.

### Main reagents

Sirius red (F3BA; Beijing Hedebio, China), PDGF-A/B, PDGF receptors (PDGFR-α/β), ectodermal dysplasia-1 (ED-1) (Beijing Bios, China), osteopontin (OPN), β-actin (Santa Cruz, USA), immunohistochemistry kit, horseradish peroxidase conjugated anti-mouse IgG (Beijing Zhongshan Bios., China) and ECL western blotting kit (Pierce, USA) were used in the present study.

### Measurement of blood pressure and sample collection

Animals were intraperitoneally anesthetized with 10% chloral hydrate (400 mg/kg) and central venous catheterization was performed through right carotid artery. Mean arterial blood pressure (MABP) was measured with a multi-channel polygraph. Immediately, the heart was obtained and the atria, main vessels and connective tissues were removed. Then, the left ventricle was split into halves. One was fixed in 4% paraformaldehyde and the other stored in -40°C for use.

### Histopathology and detection of myocardial fibrosis

The heart tissues were paraffin-embedded and cut into sections followed by H and E staining for examination of myocardial lesions. In addition, the collagen in the heart was specifically stained by Sirius red and the myocardial collagen volume fraction (CVF) and perivascular collagen area (PVCA) were determined. In brief, the sections were captured and analyzed with the Image-Pro plus 6.0 image analysis system. Eight fields were randomly selected and the CVF was calculated as collagen area / total area followed by averaging. But the area of collagens surrounding the vessels was not included in the CVF. PVC was calculated as area of collagens surrounding the arterioles in the ventricular wall / lumen area followed by averaging. Four arterioles in the ventricular wall were selected and the cross-section area was measured.

### Immunohistochemistry

Immunohistochemistry was used to detect the expressions of

PDGF-A, PDGF-B, PDGFR-α, PDGFR-β and ED-1 according to the manufacturer's instructions. The primary antibody was replaced with PBS serving as negative control. The brown granules or yellow plasma membrane was defined as positive. Ten fields without overlapping were randomly selected in the positive area at a high magnification (× 400) and the number of positive cells or optical density (OD) was determined with the image analysis system (Image-Pro plus 6.0) followed by averaging.

### Western blot assay

Total protein was extracted with lysis buffer and Lowry method was employed to determine the protein concentration. Then, the same concentration was prepared through dilution among samples, and 75 µg of proteins were subjected to sodium dodecyl sulfate polyacrylamide gel electrophoresis (SDS-PAGE) and transferred onto polyvinylidene fluoride (PVDF) membranes. After conventional washing and blocking overnight, the membranes were treated with mouse anti-rat OPN polyclonal antibody (1:1000) at room temperature for 2 h under continuous shaking. After washing, the membranes were incubated with horseradish peroxidase conjugated anti-mouse IgG (1:40000) at room temperature for 1 h under continuous shaking. Development was performed with ECL kit and photograph was captured and scanned into Bio-Rad image system. The OD of each band was determined with the Quantity-one analysis software. The OPN expression was normalized by that of β-actin.

### Statistical analysis

Statistical analysis was performed with SPSS version 13.0 statistics software package and data were expressed as Means ± standard deviation (SD). Comparisons of Means between multiple groups were carried out with one way analysis of variance. Comparisons of rates were done with chi square test. A value of P < 0.05 was considered statistically significant.

## RESULTS

### MABP levels

The MABP level in the ALD group, SPI+ALD group and ATO+ALD group was significantly higher than that in the CON group (P < 0.05). Furthermore, the MABP in the ATO+ALD group was lower than in the ALD group and SPI+ALD group but without pronounced difference (P > 0.05). There was no difference between ALD group and SPI+ALD group in MABP (P > 0.05) (Table 1).

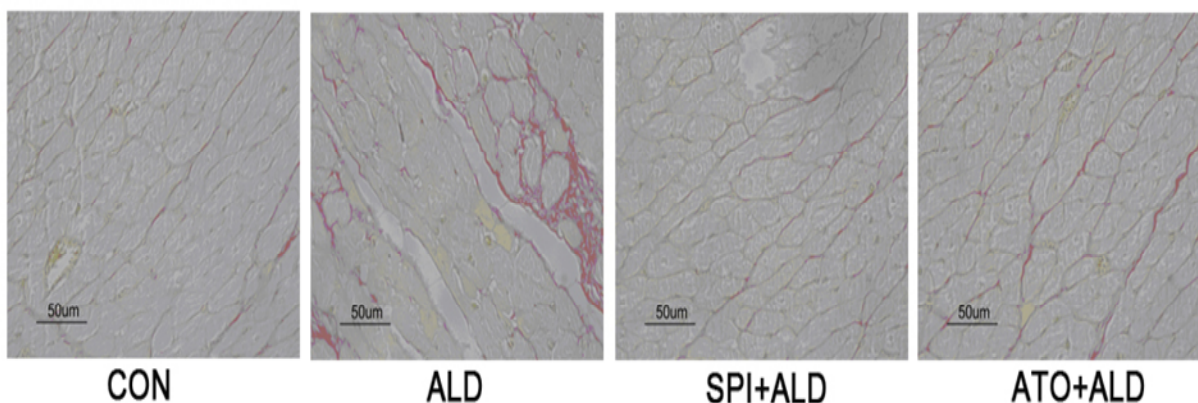
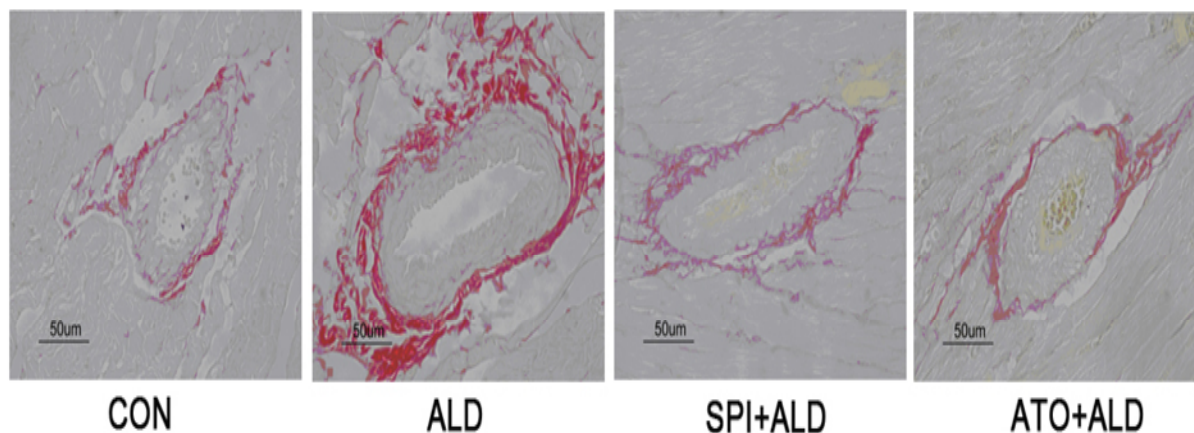
### Histopathological changes, CVF and PVCA

No lesions were found in the hearts of rats in the CON group. A small amount of inflammatory cells were found in the rats of ALD group accompanied by obvious myocardial fibrosis which was significantly alleviated in the ATO+ALD group and SPI+ALD group. Sirius red staining showed the collagen was scarlet and non-collagen was yellow. When compared with CON group, the CVF and PVCA were markedly increased in the ALD group (P < 0.01) but significantly reduced in the

**Table 1.** MABP and parameters in immunohistochemistry (n=10,  $\bar{X} \pm s$ ).

Group	CON group	ALD group	SPI+ALD group	ATO+ALD group
MABP	122±5	178±7*	169±6*	174±6*
CVF	5.5±1.7	12.9±3.0**	8.8±1.6 <sup>#</sup>	9.5±1.5** <sup>#</sup>
PVCA	18.2±2.4	29.4±4.4**	17.9±1.9 <sup>##</sup>	20.6±3.0 <sup>##</sup>
PDGF-A <sup>#</sup>	0.37±0.09	0.87±0.18*	0.38±0.10	0.39±0.57 <sup>#</sup>
PDGF-B	0.30±0.06	0.56±0.09*	0.32±0.05 <sup>#</sup>	0.33±0.13 <sup>#</sup>
PDGFR-α	0.22±0.02	0.55±0.11*	0.22±0.02 <sup>#</sup>	0.24±0.06 <sup>#</sup>
PDGFR-β	0.21±0.02	0.21±0.02	0.21±0.02	0.21±0.02
ED-1	6.9±1.1	12.1±1.5**	9.0±1.1** <sup>##</sup>	4.8±2.8** <sup>##+</sup>

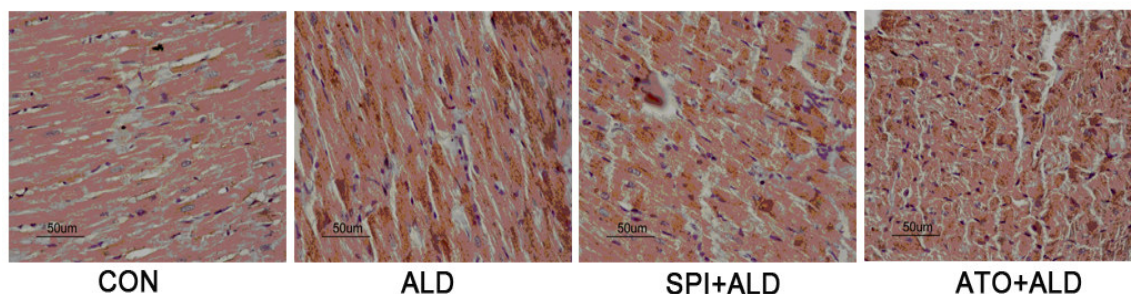
Note: \*P<0.05, \*\*P<0.01 vs ALD group; <sup>#</sup>P<0.05, <sup>##</sup>P<0.01 vs SPI+ALD group; <sup>+</sup>P<0.05.

**Figure 1.** Collagen in different groups (Sirius-red staining) (× 400).**Figure 2.** Collagen surrounding the vessels in the myocardium of different groups (Sirius-red staining) (× 400).

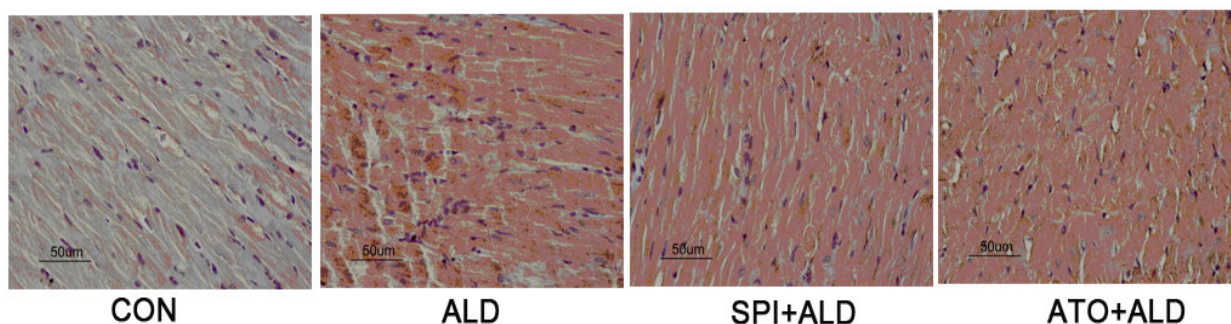
ATO+ALD group and SPI+ALD group ( $P < 0.05$  and  $P < 0.01$ , respectively). Moreover, there were no dramatic differences in the CVF and PVCA between ATO+ALD group and SPI+ALD group ( $P > 0.05$ ) (Table 1, Figures 1 and 2).

#### Immunohistochemistry for PDGF-A/B, PDGFR-α/β and ED-1 and macrophage infiltration

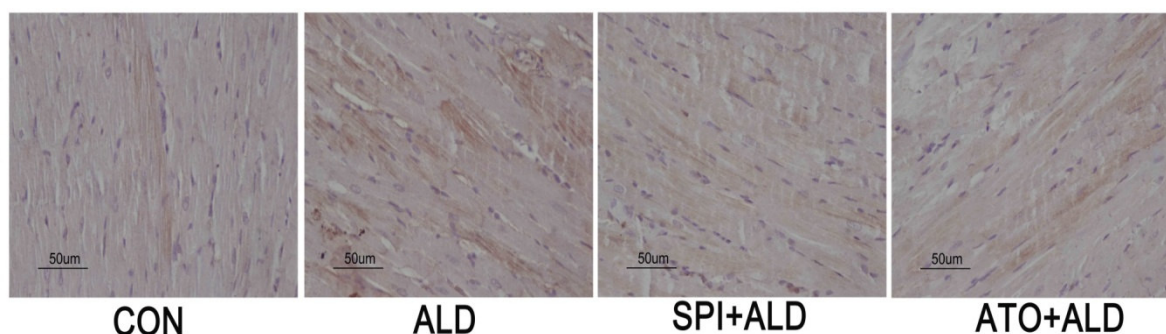
The expressions of PDGF-A/B and PDGFR-α in the ALD group were markedly higher than in the CON group



**Figure 3.** PDGF-A expression in the myocardium of different groups ( $\times 400$ ).



**Figure 4.** PDGF-B expression in the myocardium of different groups ( $\times 400$ ).



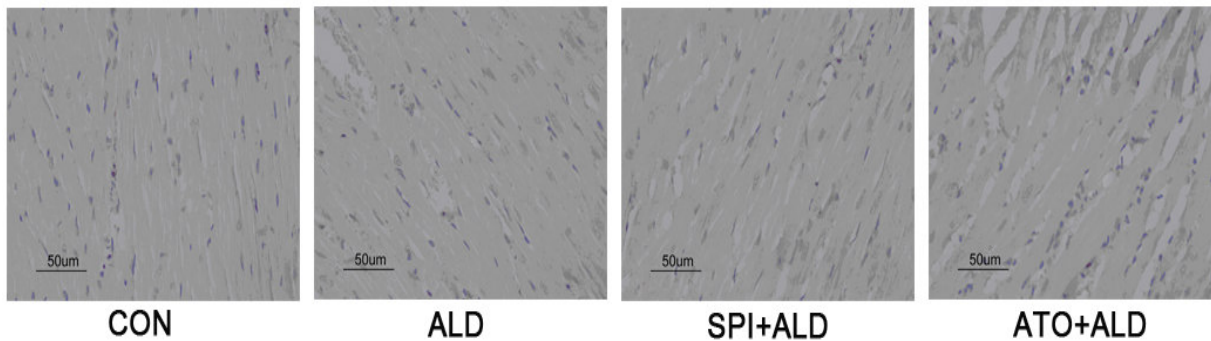
**Figure 5.** PDGFR- $\alpha$  expression in the myocardium of different groups ( $\times 400$ ).

( $P < 0.05$ ). Although the expressions of PDGF-A/B and PDGFR- $\alpha$  in the ATO+ALD group and SPI+ALD group were lower than in the ALD group ( $P < 0.05$ ), there was no significant difference between ATO+ALD group and SPI+ALD group ( $P > 0.05$ ). The PDGFR- $\beta$  was weakly expressed in the hearts of all four groups and there was no pronounced difference between these groups ( $P > 0.05$ ). The ED-1 expression was lower in the CON group than in the ALD group ( $P < 0.01$ ). In addition, the ED-1 expression in the ATO+ALD group and SPI+ALD group was markedly decreased when compared with ALD group ( $P < 0.01$ ) and that in the ATO+ALD was significantly

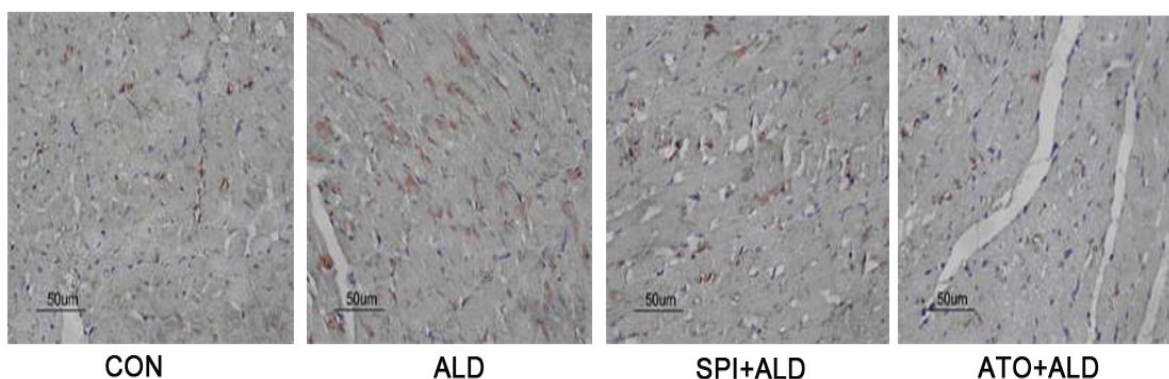
lower than in the SPI+ALD group ( $P < 0.01$ ) (Table 1, Figures 3 to 7).

#### Western blot assay for OPN expression

Western blot assay showed the OPN was weakly expressed in the CON group but its expression was markedly increased in the ALD group when compared with CON group ( $P < 0.01$ ). The OPN expression in the ATO+ALD group and SPI+ALD group was lower than in the ALD group ( $P < 0.05$ ) but still significantly higher than



**Figure 6.** PDGFR- $\beta$  expression in the myocardium of different groups ( $\times 400$ ).



**Figure 7.** ED-1 expression in the myocardium of different groups ( $\times 400$ ).

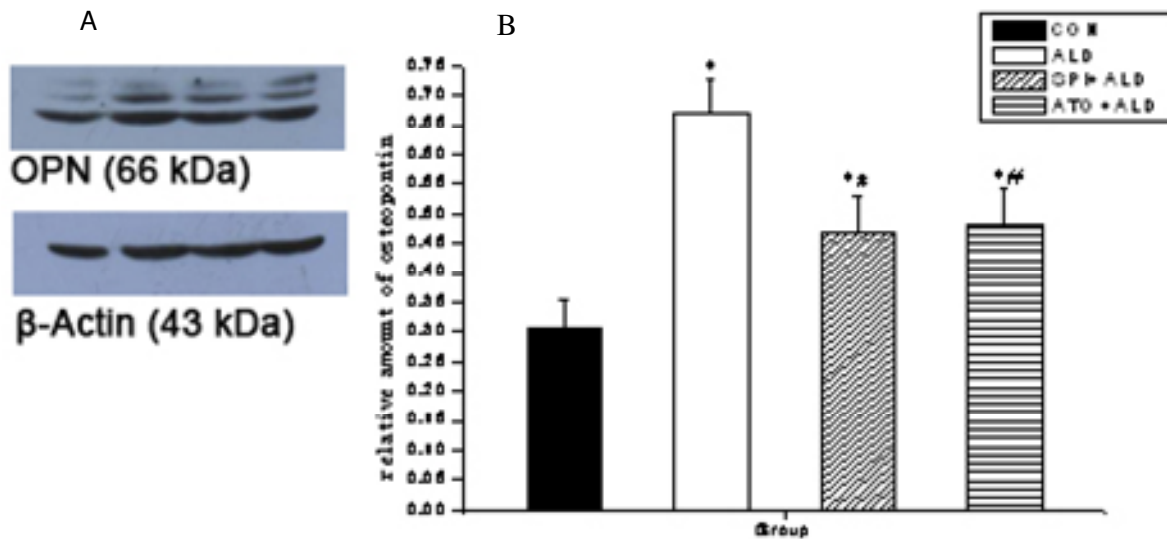
in the CON group ( $P < 0.05$ ). Moreover, there was no difference in the OPN expression between the ATO+ALD group and SPI+ALD group ( $P > 0.05$ ) (Figure 8).

## DISCUSSION

Myocardial fibrosis is a result of excessive proliferation of fibroblasts and collagen deposition in the myocardial interstitium which results in dramatically increased content, concentration or volume fraction per unit weight of myocardium. These pathological changes harden the myocardium and lead to abnormalities in the myocardial systolic and diastolic functions. Myocardial fibrosis has been considered a key step in the occurrence and development of numerous cardiovascular diseases including hypertension, heart failure, arrhythmia, cardiac sudden death, etc. Therefore, to prevent and reverse myocardial fibrosis has been an important goal in the treatment of cardiovascular diseases. ATO not only can protect endothelial cells and stabilize atheromatous plaques, but also has anti-inflammatory, anti-oxidative and anti-fibrotic properties (Kang et al., 2007; Chen et al., 2008; Tang et al., 2006). However, little is known about the role of ATO in the ALD induced myocardial fibrosis. In

the present study, unilateral nephrectomy was performed in rats which were subsequently given 1% sodium chloride. ALD was continuously administered subcutaneously to establish a myocardial fibrosis animal model. We then investigated the anti-fibrotic effect of ATO. Our results showed ATO could significantly alleviate the ALD induced myocardial fibrosis and had similar efficacy to SPI.

Studies have shown that inflammation before fibrosis development plays a crucial role in the ALD induced myocardial fibrosis (Kagiyama et al., 2007; Gaddam et al., 2009; Wynn, 2008). Infiltration of monocytes and macrophages and excessive expressions of inflammatory cytokines including cyclo-oxygenase-2 (COX-2), monocyte chemoattractant protein-1 (MCP-1), intracellular adhesion molecule-1 (ICAM-1) and osteopontin (OPN) are the characteristics of inflammation (Sun et al., 2004). Evidence also shows mineralocorticoid receptor antagonists can inhibit inflammation and fibrosis. The highly expressed inflammatory cytokines can promote the occurrence and development of fibrosis, and study work also reveals significantly reduced collagen deposition in the heart of OPN knock out animals when compared with normal animals (Okamoto, 2007). Thus, OPN is speculated to be related to the inflammation induced



**Figure 8.** OPN protein expression in the myocardium of different groups. A; Western blot assay of OPN expression; B; \* $P < 0.05$  vs ALD group; \*\* $P < 0.05$ .

myocardial fibrosis. PDGFs have the potentials to promote the mitosis and migration of fibroblasts and vascular endothelial cells and have been confirmed to be involved in the pathogenesis of a variety of fibrotic diseases. Therefore, inhibition of the expression or activity of PDGFs may be a favorable strategy to alleviate or block the development of fibrosis. A lot of fibrotic diseases have common pathophysiological processes. For example, inflammatory cells including macrophages secrete PDGFs and other inflammatory cytokines which then stimulate the expression of PDGFRs on the interstitial cells. These processes result in excessive proliferation of fibroblasts and collagen accumulation and subsequent occurrence of fibrotic lesions (Andrae et al., 2008). In angiotensin-II induced myocardial fibrosis model, there is close relationship between PDGFs and their receptors and myocardial fibrosis. In the present study, our results showed, the more the macrophages infiltrated, the more serious the myocardial fibrosis, and confirmed that, infiltration of inflammatory cells was involved in the occurrence and development of myocardial fibrosis (Nishioka et al., 2007). In addition, the infiltration of inflammatory cells and fibrosis were markedly alleviated after ATO treatment which suggests ATO can impede the development of fibrosis through inhibiting macrophage infiltration. Our results indicated the OPN expression was temporally consistent with the fibrosis, and could be significantly affected by ATO and SPI ( $P < 0.05$ ). These findings imply that the anti-fibrotic effect of ATO is associated with the suppressed OPN expression. Our study showed the expressions of PDGF -A, PDGF-B and PDGFR- $\alpha$  were increased in the fibrosis and could be inhibited by ATO or SPI. However, there was no difference in the PDGFR- $\beta$  expression between these groups. Therefore, we postulate that ATO can

confer anti-fibrotic effect through suppressing the expressions of PDGF -A, PDGF-B and PDGFR- $\alpha$ . Our results were consistent with those reported by Nishioka et al. (2007) who demonstrated that eplerenone could also combat with the angiotensin II and ALD induced myocardial fibrosis. According to the findings mentioned above, ATO can attenuate infiltration of inflammatory cells and expressions of inflammatory cytokines including OPN leading to reduction of expressions and secretion of PDGF -A, PDGF-B and PDGFR- $\alpha$  in the inflammatory cells and interstitial cells. These processes finally inhibit the proliferation of fibroblasts and collagen accumulation and significantly improve the subsequent myocardial fibrosis.

Taken together, ATO can exert anti-fibrotic effect in an ALD induced myocardial fibrosis model through inhibiting macrophage infiltration and OPN expression and suppressing expressions of PDGFs and their receptors.

## REFERENCES

- Andrae J, Gallini R, Betsholtz C (2008). Role of platelet-derived growth factors in physiology and medicine. *Genes Dev.*, 22(10): 1276-1312.
- Chen HJ, Chen JZ, Wang XX (2008). Effects of atorvastatin on myocardium expression of peroxisome proliferator-activated receptors in spontaneously hypertensive rats. *Chin J. Pathophysiol.*, 24(6): 1069-1073.
- Gaddam KK, Pimenta E, Husain S, Calhoun DA(2009). Aldosterone and cardiovascular disease. *Curr. Probl. Cardiol.*, 34(2): 51-84.
- Kagiyama S, Matsumura K, Fukuhara M, Sakagami K, Fujii K, Iida M (2007). Aldosterone-and-salt-induced cardiac fibrosis is independent from angiotensin II type 1a receptor signaling in mice. *Hypertens. Res.*, 30(10): 979-989.
- Kang L, Ge CJ, Hu SJ (2007). Beneficial effect of atorvastatin on left ventricular remodeling in spontaneously hypertensive rats. *Pharmacol.*, 80(2-3): 120-126.
- Nishioka T, Suzuki M, Onishi K, Takakura N, Inada H, Yoshida T, Hiroe M, Imanaka-Yoshida K (2007). Eplerenone attenuates myocardial

- fibrosis in the angiotensinII-induced hypertensive mouse: Involvement of tenascin-C induced by aldosterone-mediated inflammation. *J. Cardiovasc. Pharmacol.*, 49(5): 261-268.
- Okamoto H (2007) Osteopontin and cardiovascular system. *Mol. Cell. Biochem.*, 300(1-2): 1-7.
- Sun Y, Zhang J, Lu L, Bedigian MP, Robinson AD, Weber KT(2004). Tissue angiotensin II in the regulation of inflammatory and fibrogenic components of repair in the rat heart. *J. Lab. Clin. Med.*, 143(1): 41–51.
- Tang SX, Qi SS, Zhou SH (2006). Effect of atorvastatin on ventricular remodeling in spontaneous hypertension rats. *Chin J. Pathophysiol.* 22(8): 1535-1539.
- Wynn TA (2008). Cellular and molecular mechanisms of fibrosis. *J. Pathol.*, 214(2): 199-210.