

Case report

A case of Behcet's disease with abdominal aortic aneurysm

Mansoor Karimifar*, Mansour Salesi, Mozhgan Karimifar and Peyman Mottaghi

Department of Rheumatology, Isfahan University of Medical Sciences, Alzahra Hospital, Softe Avenue, Isfahan, Iran.

Accepted 14 October, 2009

Behcet's disease is a multisystem disease that is mainly classified as vasculitis and may involve many organs like skin, mucosa, eyes, joints, vessels, nervous system, gastrointestinal tract, testis, heart and lungs. This case depicts a rare presentation of Behcet's disease with multiple saccular aneurysms in a 33 year old man. A patient with a persistent pain in the back and flanks with radiation to the testis without a relationship with position and feeding, was admitted in Al-Zahra Hospital, Isfahan. Abdominal and pelvic ultrasonographic evaluation revealed an abdominal aneurysm with thick wall borders, 37 mm in total diameter and 15 mm in open lumen diameter. Spiral computed tomography (CT) of the abdomen and pelvis with contrast revealed aneurysm of the abdominal aorta (4 × 4.5 cm in diameter) beginning below the renal arteries and extending downwardly near the aortic bifurcation. Finally, magnetic resonance angiography (MRA) showed multiple saccular aneurysms of the abdominal aorta at the same places. After repairing the aneurysms by surgical operation, the patient was referred to a rheumatology clinic. After history and physical and laboratory examinations because of recurrent oral aphthae, erythema nodosum, positive result on pathergy test and abdominal aorta aneurysms, a diagnosis of Behcet's disease was made and the patient treated with medical drugs.

Key words: Behcet disease, abdominal aorta aneurysm, vasculitis.

INTRODUCTION

Behcet is a multisystem disease characterized clinically by recurrent oral aphthae along with two additional findings from the following list: recurrent genital aphthae, cutaneous lesions, ocular involvement, and a positive result on pathergy testing (John, 2005; Rachel, 2005; Moutsopoulos, 2008; Fessler, 2005). Behcet's disease is seen worldwide, with the highest prevalence reported in Turkey (80 to 370 patients per 100,000 inhabitants) and Japan (13.6 per 100,000) (John, 2005). Other regions with high prevalence include the Middle East and the Mediterranean (that is, the "Silk Route") (Johnson, 2005). Blood vessels with different sizes such as the vein or artery can be involved. Vasculitis is believed to play a role in the pathogenesis of these lesions (Moutsopoulos, 2008; Fessler, 2005). Arterial involvement occurs infrequently and presents with aortitis or peripheral arterial aneurysm and arterial thrombosis (Moutsopoulos, 2008). In this case report, a rare presentation of Behcet's

disease with multiple saccular aneurysms in the abdominal aorta was presented. The patient was a 33-year-old man who was referred to the emergency center, in Alzahra Hospital, Isfahan, Iran, with a chief complaint of flank and low back pain. He also was complaining of weight loss. On admission, vital signs were stable, there was no lymphadenopathy, abnormalities appreciated with chest wall motion and heart and lung sounds were normal. Auscultation for bruits in abdominal examination was positive. The pulse at the supra umbilicus was abnormal; abdomen was soft and non-tender; liver and spleen were not enlarged and; both testes and lower limbs were normal. The positive findings in laboratory data and paraclinical examination were as follows: Leukocytosis (WBC: 12000/ μ l) with predominantly polymorphonuclear leukocytes; erythrocyte sedimentation rate (ESR) was 70; C-reactive protein (CRP) was ++; ultrasonographic evaluation revealed an abdominal aneurysm with thick wall borders and 37 mm in total diameter and 15 mm in open lumen diameter; abdominal and pelvic spiral computerized tomography (CT) confirmed aneurysm (Figure 1); magnetic resonance angiography (MRA) showed multiple saccular aneurysm of the abdominal aorta between

*Corresponding author. E-mail: Mansoor_karimifar@yahoo.com.

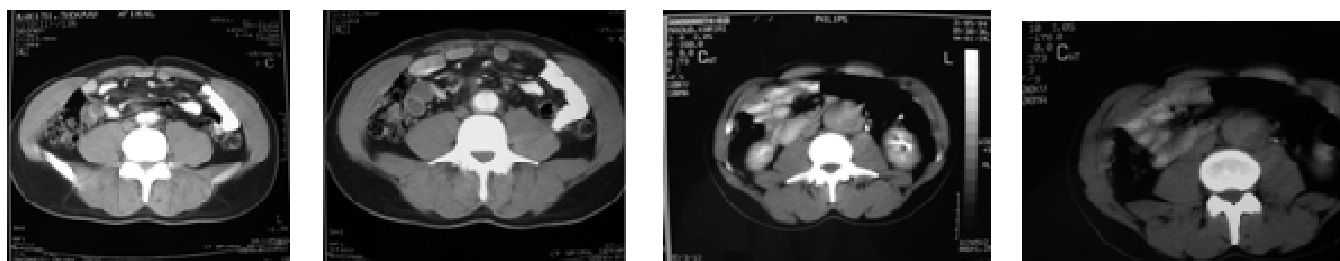


Figure 1. Abdominal and pelvic spiral computerized tomography of this case.

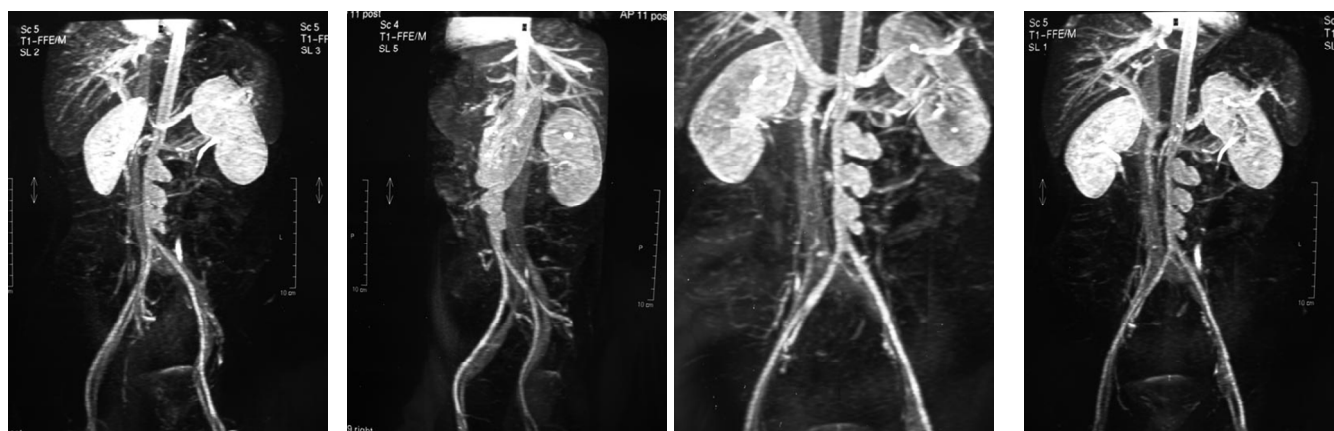


Figure 2. Magnetic resonance angiography (MRA), multiple saccular aneurysm of the abdominal aorta between renal arteries and abdominal aortic bifurcation were seen.

renal arteries and abdominal aortic bifurcation (Figure 2).

Elective repair was considered for abdominal aortic aneurysms of this patient. In histopathology evaluation of aneurysms showed two pieces of tissue ($3 \times 4 \times 4$ cm) with soft consistency and grey color, with large thickness of 0.5 cm and there was organized clot in the internal lumen. Microscopic examination of abdominal aorta aneurysms showed intima and media with neutrophilic infiltration, nuclear dust and extravasations of erythrocyte with fibrinoid necrosis.

After surgical operation, the patient was referred to the clinic of rheumatology in Alzahra Hospital Isfahan, Iran. He had a history of recurrent oral aphthae from 5 years ago, and erythema nodosum from 3 years ago in his lower limbs. He had no ocular involvement.

LABORATORY ABNORMALITIES

No diagnostic laboratory tests for Behcet's disease have been identified. Acute phase reactants (ESR and CRP at this case were 75 and +++ respectively). Other important tests were: anticardiolipin antibody (aCL), antineutrophil cytoplasmic antibodies (ANCA), HBSAg, HCVAb, VDRL,

ANA and tuberculin; all were negative. Urine analysis was normal. HLAB5 and HLAB51 were positive. Finally, because of recurrent oral ulceration at least three times in one 12-month period, erythema nodosum, positive result on pathergy testing and abdominal aortic aneurysms, the diagnosis of Behcet's disease was made. The patient was treated with prednisolone, 1 mg/kg; oral cyclophosphamide, 2 mg/kg daily and; for protection of the bladder, mesna equal with cyclophosphamide dose were prescribed. In following up the patient, constitutional symptoms and general condition was controlled. Since 2003 till now, the patient is alive and healthy.

DISCUSSION

Behcet is a chronic, complex multisystem disease characterized clinically by oral aphthae and at least two of the following: genital aphthae, cutaneous lesions, ophthalmic lesions and a positive result on pathergy testing (Rachel, 2005; Moutsopoulos, 2008; Fessler, 2005). Large vessel vascular involvement occurs in approximately one-third of patients with Behcet's disease (Kural-seyahi et al., 2003; Koc et al., 1992). In these patients, perivascular and endovascular inflammation may

may lead to hemorrhage, stenosis, aneurysm formation, thrombus formation in both arteries and veins and varices. Progression and recurrence are more likely in these patients and immunosuppressive treatment of this inflammation has been found to be beneficial, though patients may also require vascular surgery intervention (Calamia et al., 2007). Vascular involvement in Behcet disease is significantly more common in men than women, being observed in 49% of men (Kural-seyahi et al., 2003). Three types of vascular lesions are recognized: arterial occlusions, arterial aneurysms, and venous thromboses. Vasculitis is believed to play a role in the pathogenesis of all of these lesions. There is a 14-fold increased risk for venous thrombosis in patients with Behcet's disease. In the outpatient setting, 88% of vascular involvement affects the venous system (Koc et al., 1992). Thrombophlebitis is the most common manifestation of vascular involvement in Behcet's disease (Koc et al., 1992). In an autopsy study from Japan, abdominal aortic aneurysms and inferior vena cava obstruction were the most frequent arterial and venous lesions (Lakhapols et al., 1985). Arterial occlusions and aneurysms of major arteries may cause life-threatening or fatal illness from limb ischemia, stroke, renovascular hypertension, or rupture of pulmonary artery or aortic aneurysms (Lakhapols et al., 1985). In conclusion, we report a rare case of Behcet's disease in an adult man with multiple saccular aneurysms in the abdominal aorta.

Prednisolone (1 mg/kg), oral cyclophosphamide (2 mg/kg daily) and mesna equal with cyclophosphamide for bladder protection were prescribed (Stein, 2005). of bladder, mesna equal with cyclophosphamide dose were prescribed.

REFERENCES

- Fessler B (2005) Behcet's syndrome. in: koopman W, Moreland LW. Arthritis and allied conditions. 15th Edition. Lippincott William & Wilkins. 2: 1835-1844
- John H (2005) The classification and Epidemiology of Systemic Vasculitis. In: Harris G, Budd R, Genovese M (eds). Kelley's text book of rheumatology. 7th Edition. Philadelphia: Elsevier Saunders, 2: 1336-1342
- Koc Y, Gullu I, Akpek G (1992) Involvement in Behcet's disease. Rheumat. L. 19: 402-410
- Kural-seyahi E, Fresco I, seyah N (2003) The long-term mortality and morbidity of Behcet syndrome. a 2- decade outcome survey of 387 patients followed at a dedicated center. Medicine, 82: 60-76
- Lakhapols TK, Lie JT (1985) Pathogenic features of Behcet's syndrome: a review of Japanese autopsy registry data. Hum pathol, 10: 790-795
- Moutsopoulos HM (2008) Behcet's syndrome. In: Fauci As, Braunwalde E, kasper DL (eds). Harrison principle of internal medicine 17 th Edition. New York: MC graw – hill's co. 2: 2132
- Rachel A (2005) Behcet's disease. In: Harris G, Budd R, Genovese M, et al (eds). kelley' text book of rheumatology . 7 th Edition. Philadelphia: Elsevier Saunders. 2: 1396-1401
- Stein M (2005) Immunoregulatory drugs. In: Harris E, Budd R, Genovese M (Eds). Kelley'text book of rheumatology.7th Edition. Philadelphia: Elsevier Saunders.2: 920-939