

Case Report

A novel RAB-27A mutation causing Griscelli syndrome type 2 with severe central nervous system involvement: Case report and review of literature

Ali M. Alsheel^{1*}, Ayed A. Shati¹, Amer A. Alshehri² and Mansour Y. Otaif²

¹Department of Child Health, College of Medicine, King Khalid University, Abha, Kingdom of Saudi Arabia.

²Pediatric Department, Aseer Central Hospital, Abha, Kingdom of Saudi Arabia.

Accepted 8 October, 2013

Griscelli syndrome (GS) is one of the rare autosomal recessive disease characterized by hypopigmentation of the hair, hepatosplenomegally, primary immunodeficiency and neurological manifestations. It was described by Griscelli et al. (1978) in France, who reported two girls who were presented with silver gray hair, several episodes of fever, hepatosplenomegally and pancytopenia. There are three types of Griscelli syndrome based on clinical features and genetic mutations. We report a five month old girl diagnosed as Griscelli syndrome type 2 (OMIM #607624) presenting with significant central nervous system involvement. The molecular studies of the *RAB27A* gene were performed. Coding sequence revealed a novel homozygous deletion at (c.138delC). In communities with high incidence of consanguineous marriages, we should keep in mind the rare primary immunodeficiency diseases with autosomal recessive inheritance. Early diagnosis and treatment will help in improvement of the outcome.

Key words: Griscelli syndrome type 2, RAB27A, CNS involvement.

INTRODUCTION

Griscelli syndrome is one of the rare autosomal recessive disease characterized by hypopigmentation of the hair, hepatosplenomegally, primary immunodeficiency and neurological manifestations. It was described by Claude Griscelli and Michel Prunieras in 1978 in France, who reported two girls who were presented with silver gray hair, several episodes of fever, hepatosplenomegally and pancytopenia (Griscelli et al., 1978; Tomita and Suzuki, 2004; Rezaei et al., 2009).

There are three types of this syndrome published so far, Griscelli syndrome type 1 (OMIM #214450) which is characterized by neurological manifestations and *MYO5A* gene mutation. Griscelli syndrome type 2 represents patients with silvery gray hair, immunologic abnormalities and variable neurologic defects which are related to *RAB27A* gene. Finally, Griscelli syndrome type 3 presents

as hypopigmentation in the hair and skin without another findings which are related to a mutation in the 2q37.3 chromosome (Tomita and Suzuki, 2004; Rezaei et al., 2009; Klein et al., 1994; Ménasché et al., 2000). We report a 5 month old girl with seizure, silvery grey hair and hepatosplenomegally which fulfill features of Griscelli syndrome type 2 and confirmed by gene study with a novel gene mutation.

CASE REPORT

A 5-month-old Saudi female infant, the first child of consanguineous parents (first cousins). The patient's past medical history was uneventful until the age of 5 months, when she was referred to Aseer Central

*Corresponding author E-mail: alsoheel11@hotmail.com.

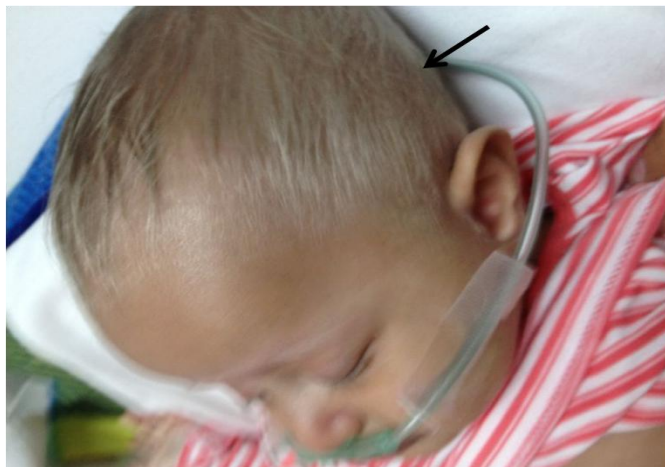

Figure 1. Oculocutaneous albinism and silvery hair.




Figure 2. Microscopy of the hair shaft reveals irregular agglomeration of pigment.

Hospital, a tertiary referral center in Aseer region, Saudi Arabia, because of fever, right focal seizure and abdominal distension. Physical examination revealed silvery grey hair, eyelashes, eyebrows (Figure 1) and hepatosplenomegaly (liver and spleen were palpable below costal margins 4 cm and 3 cm, respectively).

Laboratory data revealed white blood cell count of 6650/ μ L; (polymorphonuclear cells, 28%; lymphocytes, 60%; monocytes, 12%); hemoglobin, 11.3g/dL and platelet count, 396 \times 103/ μ L. The erythrocyte sediment rate was 15 mm/h, C-reactive protein was negative and all septic workup cultures including blood and CSF were negative upon admission. The peripheral blood smear showed no giant cytoplasmic granules in leukocytes. The results of biochemical tests were as following: alanine aminotransferase, 16 IU/L (normal range, 10-40); aspartate aminotransferase, 64 IU/L (normal range, 10-

40 IU/L); lactate dehydrogenase, 532 IU/L (normal range, up to 450 IU/L); total bilirubin, 0.2mg/dL (normal range, 0.2-1 mg/dL); direct bilirubin, 0.1mg/dL (normal range, 0-0.2 mg/dL). Triglyceride level was 253 mg/dL (normal range, 35-200 mg/dL) and ammonia level was 84ng/mL (normal range, 16-60 ng/mL). Metabolic screening was unremarkable.

The chest x-ray was normal, although abdominal ultrasound revealed hepatosplenomegaly. Brain MRI showed severe cerebral edema with multiple brain parenchymal hematomas and dural sinus thrombosis. Microscopic examination of the hair showed irregular agglomerations of pigment in the hair shafts (Figure 2). The electroencephalogram was done and it showed continuous slow activity with severe degree of encephalopathy. The patient was started on chemotherapy but she did not respond and she developed stormy hospital course with multiple medical problems including VRE (Vancomycin-resistant *Enterococcus*) meningoencephalitis/encephalopathy, seizure disorder, uncontrolled hypertension, severe pneumonia, CMV and urinary tract infections infection. The patient was seen by Neurology and Neurosurgical teams and they decided that it may not be safe to do lumbar puncture and administer intrathecal chemotherapy for her CNS illness, due to the severely raised intracranial pressure. No surgical intervention was recommended by Neurosurgeon. Unfortunately, the patient continued to deteriorate till she passed away after two weeks of admission. The patient was diagnosed with Griscelli syndrome type 2 with severe central nervous system involvement based on characteristic hair finding, neuroimaging studies and molecular genetics study (Figure 3). Her parents were referred to genetic counseling for future pregnancies.

DISCUSSION AND LITERATURE REVIEW

Griscelli syndrome is a rare and potentially fatal autosomal recessive disease. Pigment dilution of hair, skin, eyelashes and eyebrows. Immunologic and neurologic abnormalities associated with hepatosplenomegaly and recurrent infections are the general features of GS (Kurugöl et al., 2001). Three types of Griscelli syndrome have been identified. Silvery gray hair is common to all three, but immunological defects are only seen in the patients with Griscelli syndrome type 2 (Griscelli et al., 1978; Tomita and Suzuki, 2004; Rezaei et al., 2009) while the neurological manifestations are common in Griscelli GS type 1.

This syndrome is a rare inherited disorder that was originally described in 1978 (Griscelli et al., 1978). In 1997, Pastural et al. (2000) found a homozygous mutation of the gene encoding myosin VA protein (MYO5A) in a Turkish girl with Griscelli syndrome. In 2000, the same author presented evidence indicating the existence of a second locus associated with GS in the 15q21 region, which is located in less than 7.3 cm from

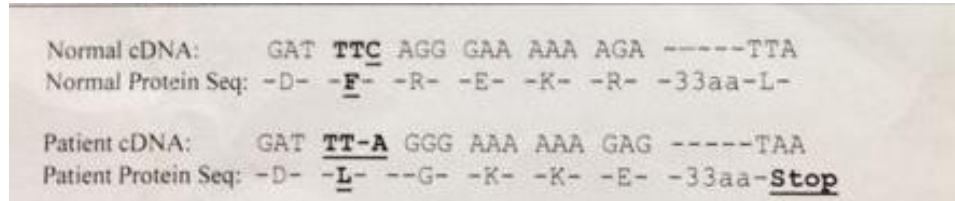


Figure 3. Molecular study result showed a novel mutation.

the MYO5A gene, the RAB27A gene⁷. Currently, GS is classified into 3 types based on the genetic and molecular features. GS 1 is described as silvery gray hair, severe psychomotor delay which are related to MYO5A gene. Griscelli syndrome types 1 and 3 are caused by mutations in the MYO5A and MLPH genes, respectively, while type 2 is caused by mutations in RAB27A (Ménasché et al., 2000; Wilson et al., 2000; Ménasché et al., 2003).

Oculocutaneous hypopigmentation may be associated with primary immunodeficiency diseases involving immune dysregulation. In addition to Griscelli syndrome, Chediak-Higashi syndrome (caused by a mutation in the LYST gene), Hermansky-Pudlak syndrome type 2 (caused by a mutation in the AP3B1 gene) and p14 deficiency (caused by a mutation in the MAP3IP gene) are other autosomal recessive immunodeficiency diseases associated with oculocutaneous hypopigmentation (Rezaei et al., 2009; Speckmann et al., 2008). Although patients with these mutations may have similar phenotypes, laboratory findings such as regular melanin granules (Chediak-Higashi syndrome), large irregular melanin granules (Griscelli syndrome) and giant neutrophilic granular inclusions in peripheral blood leukocytes (Chediak-Higashi syndrome) can help to confirm the clinical diagnosis (Rezaei et al., 2009; Speckmann et al., 2008). However, the definitive diagnosis can only be made after molecular analysis, once the mutation has been identified.

Our patient had the typical clinical features of Griscelli syndrome type 2. She presented with seizures, hepatosplenomegaly, pancytopenia and silvery hair. Microscopic examination of hair showed large irregular pigmentation. These features are typical for Griscelli syndrome type 2. The molecular genetics confirmed that she has a novel gene mutation that has not been reported previously, molecular study sequencing revealed a novel homozygous deletion at (c.138delC). The prognosis of Griscelli syndrome type 2 is poor and patients usually die in early childhood with complications such as hemophagocytic lymphohistiocytosis, unless they undergo hematopoietic stem cell transplantation (Klein et al., 1994). Although this is the only curative treatment for patients with Griscelli syndrome type 1 and type 2 (Klein et al., 1994), hemophagocytic lymphohistiocytosis should be treated first to induce remission before transplantation (Henter et al., 2010; Janka, 2007).

Conclusion

In communities with high incidence of consanguineous marriages, we should keep in mind a rare primary immunodeficiency disease with autosomal recessive inheritance. Early diagnosis and treatment will improve the outcome. The rate of autosomal recessive diseases in consanguineous families is much higher than in the general population, and primary immunodeficiency diseases do not seem to be as rare as originally thought. The high rate of consanguinity in our region (Rezaei et al., 2006) could explain the higher rate of a rare primary immunodeficiency. Genetic counseling and educational programs are essential in these regions. We recommend the general practitioners to refer any pediatric patient with striking presentation like grey hair color to pediatrician as early as possible for early supportive treatment and pre symptomatic bone marrow transplantation.

CONFLICTS OF INTEREST

There are no conflicts of interest.

ACKNOWLEDGEMENTS

We thank the patient’s family for participation and we are grateful to King Faisal Specialist Hospital staff in Riyadh for their expertise.

REFERENCES

Griscelli C, Durandy A, Guy-Grand D, Daguillard F, Herzog C, Prunieras M (1978). A syndrome associating partial albinism and immunodeficiency. *Am. J. Med.* 65:691-702.
 Henter JI, Horne A, Aricó M, Egeler RM, Filipovich AH, Imashuku J (2010). *Investig. Allergol. Clin. Immunol.* 20(7):612-615.
 EsmonPublicidad615 BS Shamsian, et al S, Ladisch S, McClain K, Webb D, Winiarski J, Janka G (2007). HLH-2004: Diagnostic and therapeutic guidelines for hemophagocytic lymphohistiocytosis. *Pediatr. Blood Cancer* 48:124-31.
 Janka GE (2007). Familial and acquired hemophagocytic lymphohistiocytosis. *Eur. J. Pediatr.* 166:95-109.
 Klein C, Philippe N, Le Deist F, Fraitag S, Prost C, Durandy A, Fischer A, Griscelli C (1994). Partial albinism with immunodeficiency (Griscelli syndrome). *J. Pediatr.* 125:886-95.
 Kurugöl Z, Ozkinay F, Varadar F, Karaçali S, Kutukçuler N, Devenci R (2001). Griscelli syndrome: report a case and review of the literature. *Pediatr. Int.* 43:298-301.

- Mamishi S, Modarressi MH, Pourakbari B, Tamizifar B, Mahjoub F, Fahimzad A, Alyasin S, Bemanian MH, Hamidiyeh AA, Fazlollahi MR, Ashrafi MR, Isaeian A, Khotaei G, Yeganeh M, Parvaneh N (2008). Analysis of RAB27A gene in Griscelli syndrometype 2: novel mutations including a deletion hotspot. *J. Clin. Immunol.* 28:384-9.
- Ménasché G, Ho CH, Sanal O, Feldmann J, Tezcan I, Ersoy F, Houdusse A, Fischer A, de Saint Basile G (2003). Griscelli syndrome restricted to hypopigmentation results from a melanophilin defect (GS3) or a MYO5A F-exon deletion (GS1). *J. Clin. Invest.* 112:450-6.
- Ménasché G, Pastural E, Feldmann J, Certain S, Ersoy F, Dupuis S, Wulffraat N, Bianchi D, Fischer A, Le Deist F, de Saint BG (2000). Mutations in RAB27A cause Griscelli syndrome associated with haemophagocytic syndrome. *Nat. Genet.* 25:173-6.
- Pastural E, Ersoy F, Yalman N, Wulffraat N, Grillo E, Ozkinay F, Tezcan I, Gediköglu G, Philippe N, Fischer A, de Saint Basile G (2000). Two genes are responsible for Griscelli Syndrome at the same 15q21 locus. *Genomics* 63:299-306.
- Rezaei N, Moazzami K, Aghamohammadi A, Klein C (2009). Neutropenia and primary immunodeficiency diseases. *Int. Rev. Immunol.* 28:335-66.
- Rezaei N, Pourpak Z, Aghamohammadi A, Farhoudi A, Movahedi M, Gharagozliou M, Mirsaeid Ghazi B, Atarod L, Abolmaali K, Mahmoudi M, Mansouri D, Arshi S, Tarash NJ, Sherkat R, Amin R, Kashaf S, Hosseini RF, Mohammadzadeh I, Shabestari MS, Nabavi M, Moin M (2006). Consanguinity in primary immunodeficiency disorders; the report from Iranian primary immunodeficiency registry. *Am. J. Reprod. Immunol.* 56:145-51.
- Speckmann C, Rohr J, Ehl S (2008). Genetic disorders of immune regulation. In: Rezaei N, Aghamohammadi A, Notarangelo LD (eds.), *Primary immunodeficiency diseases: definition, diagnosis and management.* 1st ed. Heidelberg: Springer-Verlag. p. 167-94.
- Tomita Y, Suzuki T (2004). Genetics of pigmentary disorders. *Am. J. Med. Genet. C. Semin. Med. Genet.* 131:75-81.
- Wilson SM, Yip R, Swing DA, O'Sullivan TN, Zhang Y, Novak EK, Swank RT, Russell LB, Copeland NG, Jenkins NA (2000). A mutation in Rab27a causes the vesicle transport defects observed in ashen mice. *Proc. Natl. Acad. Sci. USA.* 97:7933-8.