

*Full Length Research Paper*

# **Enterovirus outbreak among preterm infants in Singapore General Hospital: Level II nursery**

**Tan, Mary Grace S. and Yeo, Cheo Lian**

Singapore General Hospital, Department of Neonatal and Developmental Medicine, Singapore.

Accepted 25 October, 2011

**To describe the demographic characteristics, clinical presentations and outcome of neonatal enterovirus infection and to evaluate infection control measures effective in preventing the spread of infection. Detailed perinatal history, demography, neonatal conditions and laboratory investigations were retrieved retrospectively from 5 Enterovirus positive patients in the level II nursery of the Singapore General Hospital in October 2010. Five premature neonates tested positive for Enterovirus during the outbreak. All infected neonates presented with lethargy, 4 (80%) poor suck, 4 (80%) apnea, 2 (40%) poor perfusion and 1 (20%) had pyrexia. Enterovirus was positive on PCR analysis of the stool specimen in four infected neonates and on spinal fluid in one neonate. All infected neonates required respiratory support; 3 needed continuous positive airway pressure (CPAP), one required SIPPV and another needed HFOV. Inotropes was needed in 1(20%) infant and severe thrombocytopenia was documented in 3 infected neonates. The neonate who required High frequency oscillatory ventilation (HFOV) and inotropic support died on day 5 of illness. Four (80%) neonates recovered 5 days following the onset of illness. Neonatal enterovirus infection can lead to morbidity and even death. Pertinent history of exposure, early recognition, timely intervention and appropriate infection control measures are necessary to prevent dissemination of infection.**

**Key words:** Enterovirus, coxsackie type B5, neonatal enterovirus, ev in Singapore.

## **INTRODUCTION**

Neonates have immature immune system and are at higher risk for serious complications of bacterial and viral infections, including enteroviral diseases. Evaluating neonates with mild and nonspecific symptoms that are consistent with upper respiratory or viral processes can be challenging. Poliovirus, the prototypical Enterovirus can cause a subclinical infection or illness such as aseptic meningitis or paralytic poliomyelitis. The non-polio viruses which commonly infect infants include group A and B Coxsackieviruses, Echoviruses and Enteroviruses. Infected neonates can have symptoms ranging from self-limited disease to generalized multi-system organ failure and sepsis (Joki-Korpela et al., 2001; Kaplan et al., 1983; Krajden and Middleton, 1983). Enteroviral disease in neonatal period may be acquired antenatally, intrapartum

or postnatally. Other common mode of transmission in infancy includes fecal-oral route and oral-oral contamination; swimming pools, wading pools, and contaminated hands (Modlin, 1986, 2000). Enterovirus survives on surfaces for long periods of time, allowing for transmission by fomites such as toys, books and doorknobs.

Typically, the onset of a generalized enteroviral infection occurs at 3 to 5 days post contact, though some may present with a diphasic illness characterized by 1 to 7 days of recovery between initial presentation and disease progression. Early symptoms of an enteroviral infection may include lethargy, decreased feeding and transient respiratory complaints. Substantial mortality rates have been reported, and long-term sequelae may occur among survivors. Risk factors and clinical features associated with severe disease include absence of neutralizing antibody to the infecting serotype, maternal illness prior to or at delivery, prematurity, illness onset within the first few days of life, multi-organ disease,

---

\*Corresponding author. E-mail: [pravee.21msc@gmail.com](mailto:pravee.21msc@gmail.com).

severe hepatitis, positive serum viral cultures, and specific infecting serotype (e.g. group B Coxsackie viruses and Echovirus) (Lin et al., 2003). Viral culture and PCR are effective methods for the detection of Enterovirus. Advantages of using a PCR over a viral culture included faster results and improved sensitivity; however, the use of PCR is laboratory dependant (Ahmed et al., 1997). At this time, treatment of enteroviral disease in neonates is supportive, including addressing complications of diseases such as hepatitis and myocarditis, and initiating antibiotics such as ampicillin, gentamicin or cefotaxime along with the consideration of vancomycin in the very ill-appearing infant. Use of IVIG and Pleconaril in infected neonates as therapy remains experimental (Abzug et al., 1993, 1995, 2004).

Outbreak of enterovirus infection occurs sporadically in neonatal units. We report an enteroviral outbreak at a level II nursery in October 2010. The aim of this case report is to study the clinical presentation and morbid consequences of enterovirus infection as well as to highlight the importance of detailed history taking in early detection of the disease and the role of strict infection control measures in limiting the spread of infection.

## MATERIALS AND METHODS

Case records of the 5 infected infants were retrieved. The 2 infected infants (index cases) were in the level II nursery since birth due to prematurity and the rest of the premature neonates were in level II nursery awaiting weight gain and good suck. The demographic characteristics, clinical presentation, laboratory and radiographic tests as well as clinical progress of these infants were collated and compiled. Infection control measures over the period of the outbreak were reviewed and evaluated.

### Description of outbreak

The outbreak occurred in the level II nursery in the Neonatal Department at the Singapore General Hospital, Singapore on October 21, 2010. The Level II nursery is a step down unit which can accommodate a total of 18 neonates. The nursery comprises of 2 rooms (Appendixes 1 and 2), room A which can accommodate 10 patients and room B comprised of a foyer and 4 cubicles which can accommodate another 8 patients. A total of 6 inpatients were admitted to room A and another 6 infants were admitted to room B on the day of presentation of the first index patient.

The first index patient was a day 6 infant, 1<sup>st</sup> of twin admitted to room A. Within 12 h of presentation, the 2nd twin who was nursed beside her was also symptomatic with feeds intolerance and poor perfusion. These two index patients were approximately 15 m away from the other infected patients who were nursed in room B at the time of presentation of the index patients. The two infected patients nursed in room B presented with frequent episodes of desaturation and lethargy two days following the onset of illness in the index patients. The 3<sup>rd</sup> infected patient was a patient who was discharged from room B 5 days after the onset of enterovirus infection in the index patients. This infant developed fever 2 days after discharge and was re-admitted to another hospital for pyrexia. All infected infants were stable in room air prior to onset of signs and symptoms.

Detailed history of maternal well-being re-obtained from parents

of the index patients 2 days following the onset of illness reviewed that an older 2½ y/o sibling was diagnosed to have Hand Foot Mouth Disease a week prior to mother's delivery. Mother's stool tested on day 8 of twin's illness was negative for EV PCR, EV 71 RNA and EV Panel.

### Index case

The index cases, a set of twins located in room A, were 6 day old at presentation. These twins were delivered vaginally at 34/52 gestation with the birth weight of 2005 g (Twin 1) and 2110 g (Twin 2) respectively. They were admitted for prematurity and were stable till day 6 of life when they developed poor suck, lethargy, poor perfusion and apnea requiring NICU care. Septic screen conducted included aerobic blood and urine culture and chest radiography. Stool specimen analyzed on day 2 of illness was positive for Enterovirus on PCR. Stool culture confirmed the presence of Coxsackie virus type B5 in both twins. Coagulation profile was prolonged in both infants resulting in need for multiple blood product transfusions. Twins developed respiratory distress requiring nasal CPAP (NCPAP). Illness stabilized with supportive care and twins were eventually discharged well on day 26 of life.

### Spread of enterovirus infection

Two days following the onset of symptoms in the twins, two other patients in room B manifested with respiratory depression and were apneic and lethargic. Both infants were symptomatic within hours apart and both were transferred to the NICU for respiratory support and to evaluate for signs of sepsis. The 1<sup>st</sup> infected infant who was born at 32 weeks gestation with the birth weight of 1365 grams was 17 days old when he presented with recurrent apnea and lethargy. This infant needed Synchronized Intermittent Positive Pressure Ventilation (SIPPV) deteriorating to need High Frequency Oscillatory Ventilation (HFOV). This infant was also hypotensive needing inotropic support and had severe coagulopathy requiring multiple blood product transfusions. Stool analyzed was positive for enterovirus on PCR. Blood culture was positive for *Klebsiella* and ETT culture was positive for *Klebsiella* and *Sternophila trophomonas*. In spite of maximal support, infant continued to deteriorate and eventually died on day 5 of illness.

The 2<sup>nd</sup> infected infant was born at 31 weeks gestation with the birth weight of 1490 g. She was 21 days old when she presented with apnea and lethargy. Infant was ventilated and supported for respiratory depression and coagulopathy with positive response. Stool PCR was positive for Enterovirus and stool culture was positive for Coxsackie virus type B5. Blood culture and culture of the endotracheal aspirate were negative for bacterial growth. She progressed positively with support and was transferred out of NICU 5 days post onset of illness.

The third infected infant presented with fever 2 days following discharge from room B. This infant, an ex-preterm child born at 25 weeks gestation was discharged 5 days following the onset of illness in the index patient at the post menstrual age of 45.4 weeks. Septic screen done confirmed the presence of Enterovirus on PCR conducted on his spinal fluid confirming the diagnosis of Enterovirus meningitis. Infant remained stable with symptomatic care comprising of CPAP and antibiotic. He was discharged well 5 days later.

### Infection control measures

Both index patients and 2 infected infants were cohorted in the NICU. New admissions to NICU were restricted to a separate wing

Table 1. Patient demography.

Patient/Place admitted	Gestational age (weeks)	Birth weight (gm)	Age of onset (days)	Previous lung condition	Respiratory support prior to illness	Reasons for stay in Level II nursery
Index 1(Twin 1) Room A	34	2005	6	normal	Room air	Premature newborn
Index 2 (Twin 2) Room A	34	2110	6	normal	Room air	Premature newborn
Infected Patient 1 / Room B	32	1365	17	HMD	Room Air	Growing premature neonate Awaiting good suck
Infected Patient 2 / Room B	31	1490	21	Pneumonia	Room Air	Growing premature neonate Awaiting good suck
Infected Patient 3 / Room B	25	830	145	HMD and CLD	Room Air	Growing premature neonate Awaiting good suck

of the NICU. During this period, the nurse to patient ratio in NICU was maintained at 1:2 and 1:4 in the NICU and level II nursery respectively. Exposed infants nursed in the level II nursery were cohorted and discharged home directly from the nursery when medically fit with strict advice to observe for signs and symptoms of infection. No new admissions were allowed to the level II nursery for 3 weeks following the diagnosis of the last infected patients. During the outbreak, standard infection control policies and hand hygiene were reinforced. Strict hand hygiene practice using soap and water or alcohol hand-rub before and after handling of each patient and their surroundings was implemented and audited judiciously. The staff assigned to nursing the Enterovirus positive cases was not assigned to nurse the non-infected asymptomatic infants.

## RESULTS

The median birth weight of the 5 infected infants was 1560 g (range from 830 to 2110 g), with median gestational age of 31 weeks (range from 25 to 34 weeks) and median postnatal age of 39 days (range of 6 to 147 days) at presentation, (Table 1).

All infected neonates were lethargic at presentation with 80% having apnea, 40% with poor suck, 40% having poor perfusion and 20% with pyrexia. All infants required respiratory support; 3 of whom needed CPAP, 1 required SIPPV and 1 needed HFOV. Inotropic support was required in 1 infant. Severe thrombocytopenia and prolonged coagulation profile were documented in 60% of infected neonates, all of whom required multiple blood product transfusion, (Table 2).

Stools were positive for Enterovirus on PCR in 4 (80%) infected neonates while one (20%) infant was positive for Enterovirus on spinal tap fluid. Three infants were positive for Coxsackie virus type B5 on the stool culture. Nasopharyngeal aspirate culture for respiratory viruses was assayed from all four infants who presented with respiratory symptoms, however cultures was negative for the panel of common respiratory viruses. ETT culture performed on the ventilated infants confirmed the

presence of *Klebsiella* and *Sternotrophomonas maltophilia* in 1 infant. Aerobic blood culture was assayed on all five infants, of whom 1 infant was positive for *Klebsiella*. This same infant was also positive for *Klebsiella* in his endotracheal aspirate confirming the presence of superimposed *Klebsiella septicemia*. This infant required inotropic support and high frequency oscillatory ventilation. Antibiotic therapy instituted yielded no positive response and infant subsequently died on day 5 of illness. Antibiotics were also instituted to the other 4 symptomatic infants whilst awaiting the aerobic culture results. Illness resolved in these infants 5 days following the onset of illness, resulting in a mortality rate of 20%, (Table 2).

## DISCUSSION

This report described the pattern of transmission of enterovirus infection among neonates nursed in a level II nursery. Spread and spectrum of illness among infected neonates emphasized the potential for enterovirus infection to cause widespread illness with substantial morbidity among this highly susceptible population.

Enterovirus can be classified into polio and non-polio enterovirus infection. The latter is common in the neonatal period, manifesting with non specific signs and symptoms. Unlike older children and adults, some neonates with enterovirus infection can progress to multi-system disease and death. Multiple clinical syndromes varying from asymptomatic viral shedding, nonspecific febrile illness, aseptic meningitis, hepatic necrosis, coagulopathy and myocarditis are seen with neonatal enteroviral infection. Similar to reports by Huang et al. (2010), our patients presented with varying severity of the illness.

The mortality rate of 20% in our outbreak is similar to that reported by Kaplan et al. (1983); Krajden and Middleton

**Table 2.** Clinical presentation and progress of affected neonates.

Patient /Place admitted	Clinical features	Investigations	Respiratory support during illness	Other treatment	Duration of symptoms (days)
Index 1 /Room A	Lethargy, Poor suck, Poor perfusion, Apnea	Stool EV PCR - positive Stool c/s - positive for Coxsackie virus type B5 NPA - negative for respiratory virus Blood c/s - no growth Coagulation profile - prolonged Thrombocytopenia	Nasal CPAP	Antibiotics Multiple blood product transfusion	5
Index 2 /Room A	Lethargy, Poor suck, Poor perfusion, Apnea	Stool EV PCR - positive Stool c/s – positive for Coxsackie virus type B5 NPA - negative for respiratory virus Blood c/s - no growth Coagulation profile – prolonged Thrombocytopenia	Nasal CPAP	Antibiotic Multiple blood product transfusion	5
Infected Patient 1 /Room B	Lethargy, Apnea	Stool EV PCR – positive NPA - negative for respiratory virus ETT c/s – positive for Klebsiella and Sterno trophomonas Blood c/s – positive for Klebsiella Coagulation profile prolonged	SIPPV+VG→ HFOV	Antibiotic, Multiple blood product transfusion	Died on day 5 of illness
Infected Patient 2 /Room B	Lethargy, Apnea	Stool EV PCR - positive Stool c/s - positive for Coxsackie virus Type B5 NPA - negative for respiratory ETT c/s - no bacterial growth Thrombocytopenia	SIPPV+VG	Antibiotic, Multiple blood product transfusion	5
Infected Patient 3 /Room B	Lethargy, Pyrexia	Stool EV PCR - negative EV 71 - not detected Blood c/s - negative for bacterial growth CSF Culture - positive for EV	NCPAP	Antibiotic	5

1983). Although the majority of infections in the neonate are benign, high index of suspicion will expedite efficient management. Physicians should also recognize the clinical manifestations and risk factors for severe disease

to anticipate complications and to implement intensive management of infants at high risk of adverse outcomes. No sex predilection for enteroviral infection has been reported, however 3 of our infected patients (60%) were

females.

Enterovirus infection can result in significant morbidity in premature infants. In this outbreak, two out of 5 infants (40%) developed severe respiratory distress requiring mechanical ventilation. As seen in our patients, the spectrum of respiratory compromise can range from mild to severe. Enteroviral infections may lengthen the stay of hospitalization of infected infants. Indeed, 1 of our infant was re-admitted following exposure to the enteroviral infection outbreak. The mean duration of symptoms among our infected infants was 5 days. This is comparable with reports by Huang et al. (2010) and Nino et al. (2006).

In our nursery, the immediate identification of symptoms with a high index of suspicion and implementation of strict infection control measures controlled the spread of infection despite the fact that many infants were exposed. Strict cohorting practice implemented early and lasting for a period of 3 weeks contributed to the limitation of the disease in the nursery. However, cohorting of exposed patients may not be possible in units with limited space and overcrowding will promote transmission of an outbreak. Given that the index patients were symptomatic within the week of delivery, it is postulated that the infection was vertically transmitted from their mother who cared for an older sibling who was diagnosed clinically to have hand-foot-mouth disease a week prior to her delivery.

The 3 other infants were infected horizontally within the nursery. Enteroviruses are transmitted predominantly via the fecal-oral route, however, Coxsackie virus A21, which is spread mainly by respiratory secretions and Enterovirus 70 are known to spread via respiratory secretions and shed in tears and spread via fingers and fomites respectively. Three of our infected patients were positive for Coxsackie virus type B5. These infants possibly acquired the virus through respiratory secretions and/or tears which was spread via fingers of health care staff.

It is known that Enteroviruses upon entry into the oropharynx would replicate in submucosal tissues of the distal pharynx and alimentary tract. Viral particles are subsequently shed in the feces and in upper respiratory tract secretions for days prior to symptom onset. The average incubation period is 3-10 days, during which time the virus migrates to regional lymphoid tissue and replicates further. Minor viremia results and dissemination to target organs follows. Viral replication in target organs produces the major viremia with possible secondary seeding of the CNS. Potential target organs include the skin and the central nervous system. Infectious virus is shed from the upper respiratory tract for 1-3 weeks and from the feces for 3-8 weeks.

Among the infected patients, the potential risk factor for enterovirus infection noted was prematurity. All infected infants were born prematurely but were apparently well till onset of signs and symptoms of infection. Considering how fast the deterioration of patients with enterovirus

infection was, it is indeed important to have a high index of suspicion so that proper management strategy and control measures can be implemented.

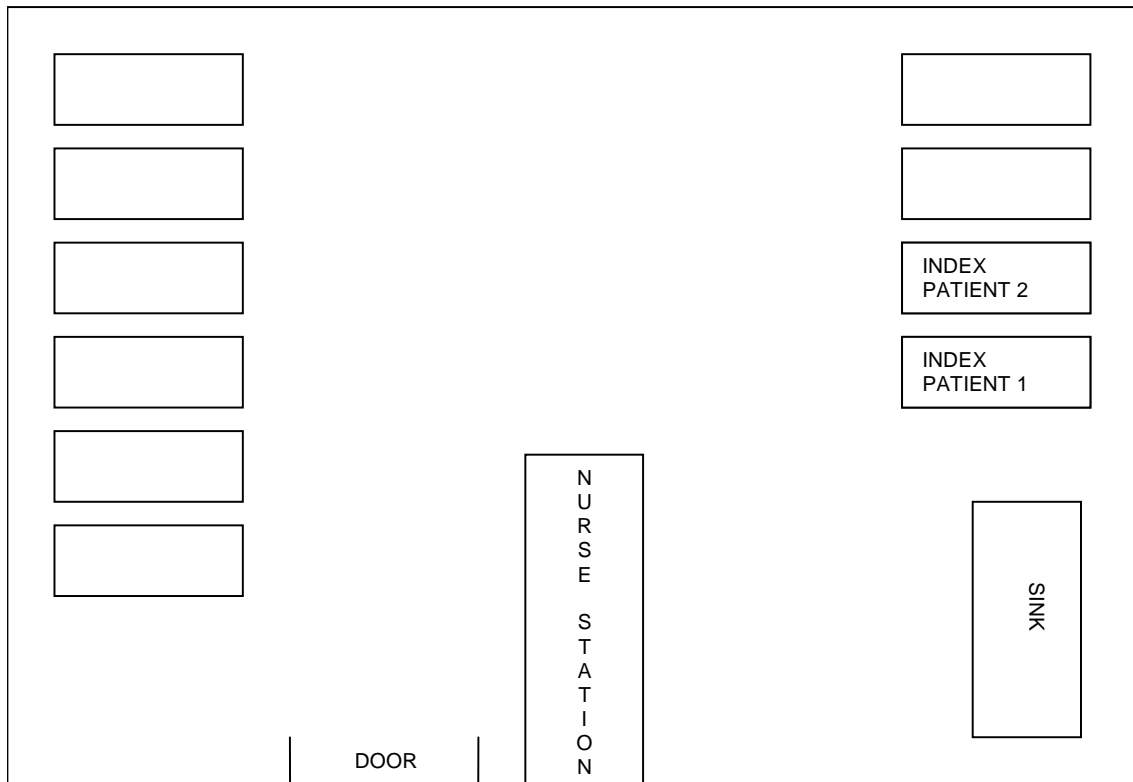
## Conclusion

Enterovirus infection is a life threatening viral infection if not detected early. It can present with non specific signs and symptoms in infants, hence high index of suspicion and early diagnosis is necessary to prevent an outbreak. Proper and complete history taking is necessary to be able to elicit information that can be overlooked by a non medical practitioner like parents. This outbreak reinforced the benefits of strict contact precaution and hand hygiene technique among all involved in care of vulnerable patients. It also enlightened the understanding of physicians that enteroviral infections should be taken seriously and that rapid deterioration leading to death can happen in neonates.

## REFERENCES

- Abzug MJ (2004). Presentation, diagnosis and management of enterovirus infections in neonates. *Paediatr. Drugs*, 6(1):1-10.
- Abzug MJ, Keyserling HL, Lee ML, Levin MJ, Rotbart HA (1995). Neonatal enterovirus infection: virology, serology and effects of intravenous immune globulin. *Clin. Infect. Dis.*, 20: 1201-6.
- Abzug MJ, Levin MJ, Rotbart HA (1993). Profile of enterovirus disease in the first two weeks of life. *Pediatr. Infect. Dis. J.*; 12:820-4.
- Ahmed A, Brito F, Goto C (1997). Clinical Utility of the Polymerase Chain Reaction for Diagnosis of Enteroviral Meningitis in Infancy. *J. Pediatr.*, 131(3): 393-7.
- Huang FL, Cheng CH, Huang SK, Chen PY (2010). An Outbreak of Enterovirus 71 in a nursery. *Scand. J. Infect. Dis.*, 42(8): 609-12.
- Joki-Korpela P, Hyypia T (2001). Parechoviruses, a novel group of human picornaviruses. *Ann. Med.*, 33: 466-71.
- Kaplan MH, Klein SW, Mc Phee J, Harper RG (1983). Group B coxsackievirus infections in infants younger than three months of age: A serious childhood illness. *Rev. Infect. Dis.*, 5: 1019-32.
- Krajden S, Middleton PJ (1983). Enterovirus infections in the neonate. *Clin. Pediatr.*, 22: 87-92.
- Lin TY, Kao HT, Hsieh SH (2003). Neonatal enterovirus infections: emphasis on risk factors of severe and fatal infections. *Pediatr. Infect. Dis. J.*, 22: 889-94.
- Modlin JF (2000). Coxsackieviruses and newer enteroviruses In: Mandell GL, Bennett JE, Dolin R, Eds. *Principles and Practice of Infectious Diseases*, 5<sup>th</sup> edn. Philadelphia: Churchill Livingstone, 1904-19.
- Modlin JF (1986). Perinatal echovirus infection: insights from a literature review of 61 cases of serious infection and 16 outbreaks in nurseries. *Rev. Infect. Dis.*, 8: 918-26.
- Nino K, Ashley LM, Steven O, Mark P (2006). Neonatal Enterovirus infections reported to the national enterovirus surveillance system in the United States. *Pediatr. Infect. Dis. J.*, 25: 889-93.

**Appendix 1. Room A.**



**Appendix 2. Room B.**

