

Full Length Research Paper

Pathological, serological and virological findings in goats experimentally infected with Sudanese Peste des Petits Ruminants (PPR) virus isolates

Nussieba A. Osman^{1*}, A. S. Ali², M. E. A/Rahman³ and M. A. Fadol

¹Department of Pathology, Parasitology and Microbiology, College of Veterinary Medicine and Animal Production, Sudan /Sudan University of Science and Technology, P.O.Box 204, Khartoum North, Sudan.

²Department of Preventive Medicine and Veterinary Public Health, Faculty of Veterinary Medicine, University of Khartoum, Post code 13314, Khartoum North, Sudan.

³Department of Virology, Central Veterinary Research Laboratories, Soba, P.O.Box 8067, Khartoum, Sudan.

⁴Viral Vaccine Production Unit, Central Veterinary Research Laboratories, Soba, P.O.Box 8067, Khartoum, Sudan.

Accepted 9 June, 2009

Four Peste des Petits Ruminants virus (PPRV) Isolates were collected from clinical cases of three goats and one sheep from Khartoum State; Soba/Khartoum State and Bashaier/River Nile State. These PPR viruses were isolated in Lamb kidney cells (LKC) and Lamb testis cells (LTC) and identified by Agar Gel Precipitation Test (AGPT) and Hemagglutination (HA) tests. Four PPRV isolates were used for experimental infection in four groups (n = 4) of Sudanese goats. Goats of group A and B were inoculated with the 4th passage of two Sudanese PPRV cultured in lamb testis cells, 6×10 TCID₅₀/ml of Bashaier and 6×10 TCID₅₀/ml of Soba isolates, isolated from sheep and goat respectively. Whereas, group C and D were received 6ml of the fifth passaged 20% infected tissue suspensions of Khartoum and Soba PPR isolates propagated in goats. The inoculated goats showed typical PPR clinical signs, gross lesions and histopathological changes while control animals (group E) appeared healthy. Two goats from group A died on the 16th and 19th days post inoculation. PPR viruses were detected by HA test from lacrymal fluid and nasal swabs on the 6th and 7th dpi. Serum samples were collected and tested for PPRV antibodies by C-ELISA from the sixteen experimentally infected goats and from control animals. Traces of PPRV antibodies were shown on day 7 and they were continued to rise till the 28th day and dropped on the 30th day which is the 9th day post challenge. The observed clinical signs, post mortem lesions and the detectable antibodies indicated that the tissue culture propagated PPR viruses and the infected tissue homogenate were effective for initiation of infection.

Key words: PPRV isolates, tissue culture virus, goat adapted virus, experimental infection, immune response.

INTRODUCTION

Peste des petits ruminants virus (PPRV) is a member of genus *Morbillivirus*, closely related to rinderpest virus (RPV), causes an acute febrile disease of small ruminants with morbidity and mortality rates as high as 100 and 90% respectively (Abu-Elzein et al., 1990).

Clinically, the disease is characterized by severe pyrexia, ocular and nasal discharges, necrotizing and stomatitis, conjunctivitis, gastroenteritis, diarrhoea and pneumonia (Ismail et al., 1995 and Jones et al., 1993). The prin-

ciple host of PPR are sheep and goats, with goat being more susceptible to infection and erosive subsequent disease (Ezeokoli et al., 1986). In goats and sheep PPR and RP viruses produce clinical disease and pathology that are indistinguishable. However, for the diagnosis of rinderpest in small ruminants it is essential to differentiate it clearly from PPR. Infection rates in sheep and goats rise with age and the disease, which varies in severity, is rapidly fatal in young animals (Lefevre and Diallo, 1990 and Wosu, 1994). The disease appears with a higher incidence in the rainy season. The infection is transmitted by close contact between infected and susceptible animals (Lefevre and Diallo, 1990).

*Corresponding author. E-mail: nussieba@yahoo.com. Tel: 00249 912446180.

Experimentally, the virus has been transmitted paraterally through different routes: nasal, oral, subcutaneous, intraocular, intratracheal and intravenous or by contact (Durtneil, 1972 and Durojaiye, 1980).

The aim of this study is to determine the pathological, virological and serological findings in goats experimentally infected with tissue culture virus and infected tissue suspensions of PPRV. On the other hand, is to investigate the possibilities of identification of PPR virus from the samples of experimentally infected goats.

MATERIALS AND METHODS

Animals

Twenty one healthy goats of local breed aged between 4-5 months were purchased from the local market. These animals were grouped in 5, A, B, C, D, and E. First 4 groups contain 4 animals in each and group E contains 5 animals as control. Goats were quarantined for 7 days and kept under close observations for any signs of the disease. All animals were free from detectable PPR antibodies as judged by C-ELISA.

Collection of samples

Four Lymph nodes and spleen samples were collected from sheep and goats suspected to be infected by PPRV. The first sample originated from goats was collected from Khartoum State; the second and the third originated from goats were collected from Soba, Khartoum State and the fourth originated from sheep was collected from River Nile State.

10 - 20% (w/v) suspensions of lymph nodes and spleen samples were prepared by grinding with sterile sand using mortar and pestle in PBS pH 7.4 supplemented with antibiotics. The supernatant was used for PPRV isolation after identification by AGPT (White, 1958) and HA test (Nussieba et al., 2008).

Virus isolation and titration

10 - 20% suspension of spleen and lymph nodes from suspected animals were used for initial PPRV isolation which was carried in primary lamb kidney (LK) and lamb testis (LT) cells. The 2nd passage of LK and LT cells were used for propagation of PPR virus. For experimental inoculation of goats each PPRV isolate was adapted to LT cells with a minimum of 4 passages following the technique described previously by Plowright and Ferris (1959). The tissue culture dose end point TCID₅₀ (50% Tissue Culture Infective Dose) of a virus suspension was determined as described by Plowright and Ferris (1962). The titre was calculated by the Spearman-Kärber method (Spearman, 1908 and Karber, 1931) and expressed as log₁₀ TCID₅₀ / ml.

PPRV isolates

The 4th passage of PPRV Bashaier (LTC P4) and Soba (LKC P3, LTC P4) isolates were used for inoculation of goats as tissue culture adapted virus. These isolates originated from sheep and goat, respectively. The 3rd passage of another two PPRV isolates, Khartoum and Soba (LKC P3) originated from sheep was subjected to further two passages in goats (Goat P5). Viruses from the 5th goat passage were used as 20% infected tissue suspensions.

Virus propagation in goats

The procedure of the propagation of PPRV in goats was followed as described earlier by Durtneil (1972). Two goats were inoculated with 6 ml subcutaneously (s/c) accompanied by 1 ml intranasally (i/n) of the 3rd virus passage. On the 12th dpi goats were slaughtered and organs were collected aseptically. Spleen and lymph nodes were prepared as 20% suspension in PBS for further passage in goats. The 5th passage of PPRV (LTC. P3 Goat P5) was used for inoculation of goats.

Experimental inoculation of goats with PPRV isolates

Group A and B were treated with tissue culture isolates (TCV) while group C and D were treated with infected tissue suspensions (ITS).

Goats of group A and B were inoculated with $6 \times 10^{4.5}$ TCID₅₀ /ml of

PPRV Bashaier (LTC P4) and $6 \times 10^{4.3}$ TCID₅₀ /ml PPRV Soba (LKC P3 LTC P4) isolates, respectively. Goats of group C and D were inoculated with 20% infected spleen and lymph nodes suspensions of PPRV Khartoum (LTC P3 Goat P5) and PPRV Soba (LTC P3 Goat P5) isolates, respectively. Each goat received 5 ml subcutaneously and 1 ml intranasally following a combinations of the procedures described by Mann et al. (1974) and Bundza et al. (1988).

Challenge experiment of immunity was carried out on the 21st dpi with $10^{5.4}$ TCID₅₀ /ml of virulent PPRV Sinnar strain (72/1) at a dose of 5 ml/animal subcutaneously. Rectal temperatures were recorded at 8.30 am daily. Blood was collected from all the infected goats at peak of temperature for virus isolation. Recovered goats were slaughtered after a week of the challenged experiments and postmortem findings were recorded. Slices of mesenteric lymph nodes, spleen, lung, small and large intestine were collected for histopathological examinations following the procedure of Carleton (1967).

For determining the humoral immune response of PPRV isolates, serum samples were collected at 7, 10, 14, 18, 21, 28 and 30 days post inoculation. PPR C-ELISA (BDSL, 2000) was carried out to determine the antibody titres induced by PPRV isolates.

Detection of PPRV in samples of inoculated goats

PPR viruses were detected in nasal and lacrymal swabs using haemagglutination (HA) test as described previously by Nussieba et al. (2008). Lacrymal and nasal swabs were collected on 6 and 7 dpi, respectively in 150 µl of PBS pH 7.2 for antigen detection. The swab fluid was centrifuged 1 h after collection, at 3000 rpm for 20 - 30 min and then stored at -40 °C.

RESULTS

Clinical response to PPR viral isolates in infected goats

Inoculated goats developed clinical signs similar to those of the naturally infected animals while uninoculated (control) goats remained apparently healthy. Inoculated goats of all groups remained healthy for 3 - 4 days following inoculation passaged tissue culture and infected tissue suspensions PPR viruses. Clinical signs began with an elevated temperature up to 40 - 40.6 °C in infected goats

Table 1. Clinical observation of the goats after infection with PPRV.

Type of virus	Fever	Stomatitis	Pneumonia	Diarrhoea	Ocular involvement	Nasal involvement	Labial scabs	Death
TCV ¹	8 G	3 G	4 G	4 G	6 G	8 G	3 G	2 G
%	100%	37.5%	50%	50%	75%	100%	37.5%	25%
ITS ²	8 G	2 G	3 G	4 G	6 G	8 G	2 G	0
%	100%	25%	37.5%	50%	75%	100%	25%	0%

Table 2. Days of the onset of clinical signs in goats infected with PPRV.

Experiment No.	Type of virus	Incubation period	Days of onset of				Days killed (k) or dead (D)	
			Viraemia	Lacrymal excretion	Nasal excretion	Mouth lesions		
Exp. 1	TCV ¹	5 - 7 th	5 - 6 th	5 th	5 th	7 th	6 - 13 th	16 and 19 th
Exp. 2	ITS ²	5 - 7 th	5 - 6 th	5 th	5 th	7 th	9 - 13 th	—

Notes:

TCV¹ : Tissue culture virus.

ITS² : Infected tissue suspension.

while animals in the control group showed no thermal response. Pyrexia was detected in all experimentally infected goats on the 5 - 7th dpi. Goats developed a very slight superficial necrosis of the lips on the 7th day. On the 6th day, the fever was sustained. On the 5th day, serous nasal and lacrymal discharges appeared. Serous nasal and lacrymal discharges involved all the 16 goats (100%) on the 7th day. During this phase animals in general were dull, depressed and anorexic with congested mucous membranes. A cough was usually noticed early in the disease on the 8th and the 9th day. The respiration was usually fast and shallow. On the 9th day, conjunctivitis appeared and involved goats on the 13th day. Mucoid nasal discharges were observed in goats on the 13th day and on the 15th day.

Diarrhoea with abdominal pain was a common feature of the disease and it occurred on the 9th day following the onset of fever. Goats showed evidence of diarrhoea on the 13th day. The signs persisted for 6 days and the animals become progressively weaker.

Between the 11 and 13th days, the fever regressed and the oral and the encrusted lip lesions began to resolve. The nasal discharges and crust formation occurred while the oral lesions extended to cross the muco-cutaneous portion of the lip with scab formation at mouth commissure at the 12 and 15th day respectively. Death was usually preceded by severe emaciation, dehydration, subnormal temperature and collapse. Two goats (25%) of group (A) which were inoculated with PPRV Bashaier isolate died on day 16 and 19th post inoculation respectively. The incidence of the different clinical signs is shown in Table 1 and the onset of the disease is summarized in Table 2.

Immune response to PPR viral isolates in infected goats

Serum samples were collected from goats experimentally inoculated with PPRV at 7, 10, 14, 18, 21, 28 and 30th dpi (Figure 1) and examined using C-ELISA to detect antibodies against PPRV. 4 sera (25%) out of the 16 goats experimentally inoculated with PPRV showed detectable antibodies at 7 dpi while all the goats (100%) showed detectable antibodies at 10 dpi. The titre of antibodies induced by PPRV started from weak positive (PI 51 - 70%) at 7 dpi to moderate (PI 73 - 82%) and strong positive (PI 85-90%) at the following days till 21 dpi. Following challenge of experimental animals at 21 dpi, a rise in antibodies titre was observed at 28 dpi. In 30 dpi the antibody titres were less than in 28 dpi.

Detection of PPRV antigen in samples from inoculated goats

The HA titres of PPRV antigen detected in nasal and lacrymal swabs of experimentally infected goats ranged between 4 and 16.

Post-mortem examination of inoculated goats

Gross pathology: The most characteristic post mortem lesions were found in the gastrointestinal and respiratory tract. There was evidence of emaciation in all the inoculated goats (100%). In some goats of the two groups the rumen, reticulum, omasum and abomasum were filled with foetid watery fluid. The small intestine showed evidence of severe inflammation. The small intestine was

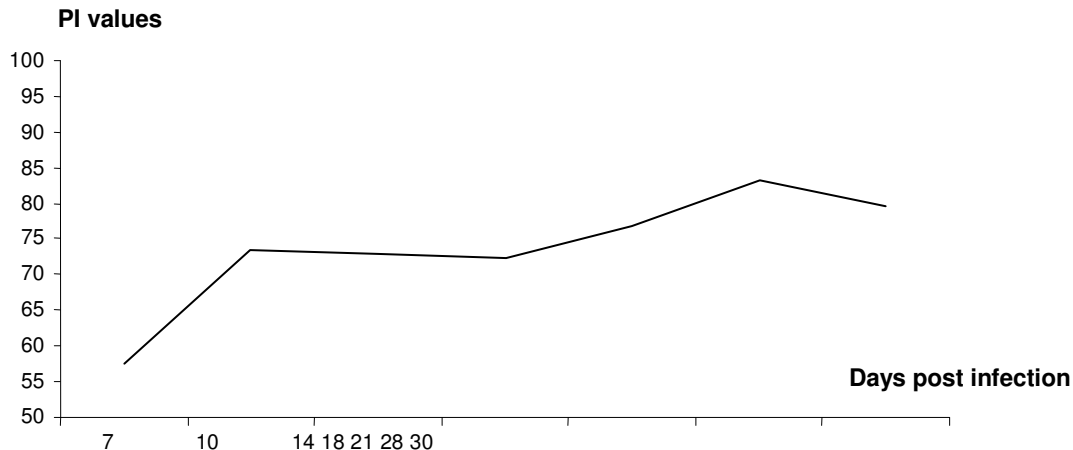


Figure 1. PI values for PPRV antibodies.

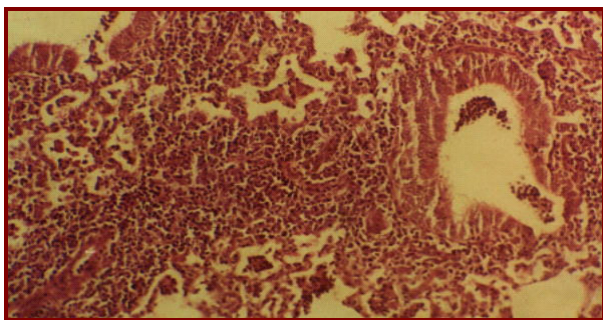


Figure 2a. Lung: note proliferation of bronchiolar epithelium, intense diffusion of mononuclear cells. H and E X10.

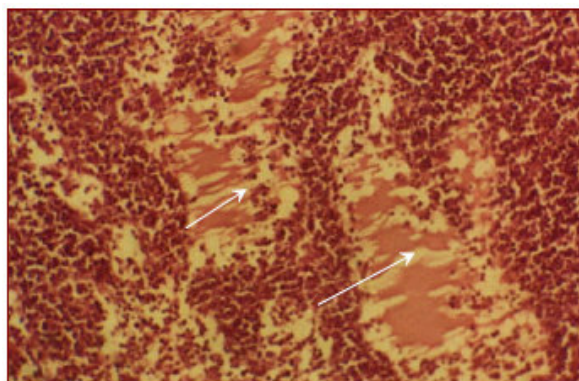


Figure 3a. Lymph node: note oedema (white arrows). H and E X10.

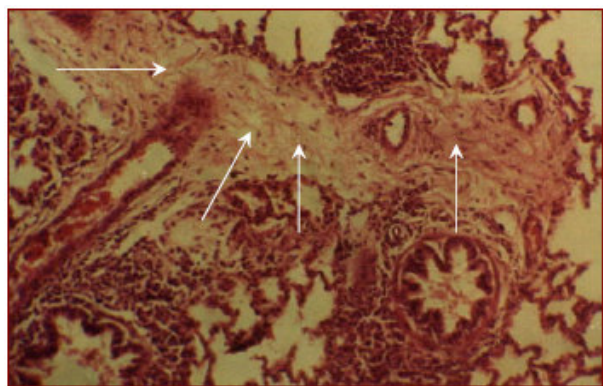


Figure 2b. Lung: note interlobular proliferation of fibrous tissue (white arrows). H&E X10.

the less involved were the intermediate and cardiac lobes. Post mortem examination showed evidence of pneumonia, congestion of the lung lobes and hydrothorax. Fatty change in kidneys was observed.

Histopathology

The lung showed bronchiointerstitial pneumonia characterized by proliferation of bronchiolar lining epithelium, intense diffusion of mononuclear cells mainly lymphoid, macrophages and plasma cells in the periductal, the interstitial tissue and alveoli lumina (Figure 2a). Areas of scarring were seen in interlobular connective tissue (Figure 2b). In lymph nodes, there was oedema in the cortical and medulla (Figure 3a) and infiltration of mononuclear cells and some giant cells in subcapsular areas and medullary sinuses (Figure 3b). The spleen showed haemorrhage and haemosidren pigment deposition (Figure 4a and 4b). The intestine showed atrophic villi with partial denudation of epithelial lining and intense diffusion of mononuclear cells in the lamina propria and submucosa (Figure 5).

filled with watery fluid as found in the abomasum. The colon and caecum showed evidence of linear haemorrhage and areas of ulcerations. Lymph nodes were engorged and oedematous. Spleen was enlarged and oedematous. In the respiratory system, the trachea showed evidence of inflammation and filled with frothy exudates. Pneumonia was usually observed in a few lung lobes. The most involved was the right apical lobe and

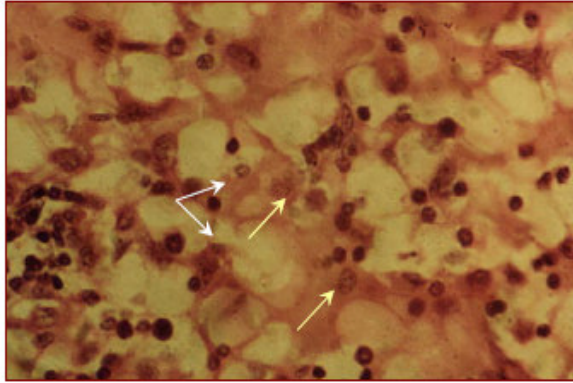


Figure 3b. Lymph node: note proliferation of mononuclear and giant cells (white and yellow arrows). H and E X40.

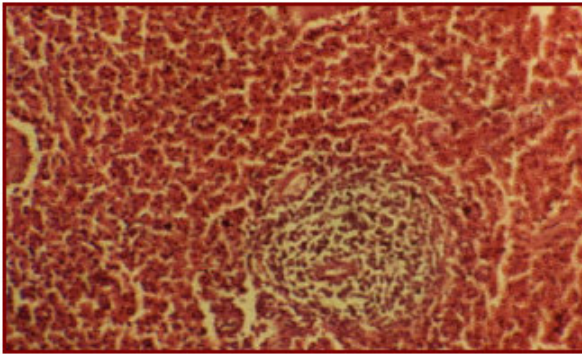


Figure 4a. Spleen: note accumulation of extravasated erythrocytes. H and E X10.

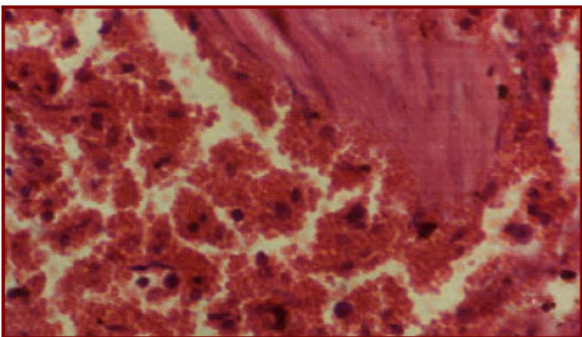


Figure 4b. Spleen: note accumulation of extravasated erythrocytes. H and E X40

DISCUSSION

The examination of nasal and lacrymal swabs from goats experimentally inoculated with PPRV by HA test resulted in agglutination of RBCs. Chicken RBCs were used for detection of PPRV in swabs depending on the highest sensitivity of the RBCs of this species upon the others. The HA test of swab samples resulted in slightly low titres ranging from 4 to 16. This result was in agree-

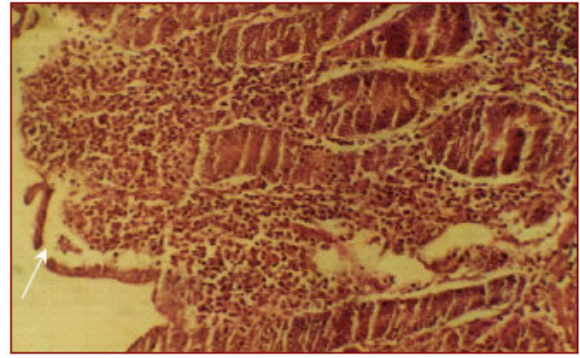


Figure 5. Small Intestine: note atrophic villi, denudation of lining epithelium and intense infiltration of mononuclear cells. H and E X10.

ment with Wosu (1991) who documented that the HA titre was not a reflection of the concentration of the virus in secretions, but rather a reflection of the degree of dilution of the virus in the secretion with the diluents. The obtained HA titres were indication of the shedding of PPR virus in nasal and lachrymal swabs. This result was similar to that mentioned earlier by Abegunde and Adu (1977) whom detected the existence of PPRV in nasal and conjunctival secretions. Virus was confirmed in ocular and nasal swabs at the onset of clinical signs which is the most important epidemiological aspect in spread of the disease.

Of the 16 infected goats, 8 were inoculated with tissue culture propagated PPRV and the other 8 were inoculated with infected tissue suspension. The experimental infection of goats with PPRV revealed observable clinical signs and postmortem lesions in inoculated animal. This infection was accompanied with morbidity and mortality rates reaching 100% and 12.5% respectively. Serological studies indicated the presence of detectable antibodies against PPRV. Following challenge of inoculated animals, with virulent PPRV which was carried out at day 21 p.i., goats did not show rise in body temperature or any signs of the disease. From this result it was obvious that experimental infection with PPRV resulted in high percentage of morbidity but low percentage of mortality in contrast to natural PPRV infection. This is in agreement with Elhag Ali (1973) and Mann et al. (1974) whom found that animals experimentally infected with PPRV develop mild form of the disease. Although they demonstrated the appearance of the disease in experimentally infected animals, Mann et al. (1974) suggested that the successful transmission of the acute disease may require more than one challenge. Moreover some authors suggested that a more severe disease results from mixed infection of bacteria and viruses than a single infection. This substantiated the result of Onoviran et al. (1984) who reported that a combined infection of *Mycoplasma capri* and PPR was found to be much more severe in goats than infection by a single agent. Nutritional and environmental factors have an important effect on the appearance of the

disease in a flock of animals. On the other hand, Saliki (1998) previously reported that poor nutrition status, stress of movement and concurrent parasitic and bacterial infections enhance the severity of clinical signs.

Examination of serum samples from goats infected with PPRV showed detectable antibodies at the 7th day and the 10th day p.i. with increase in the antibody titre at the following days. The detectable PPR antibodies were indicative of the humoral immune response due to the exposure of animals to the virus. This observation was in concordance with those reported by Taylor (1979).

Conclusion

The observed clinical signs, post mortem lesions and the detectable antibodies indicated that PPRV in the form of tissue culture propagated viruses or infected tissue homogenate were proved effective for initiation of infection.

REFERENCES

- Abegunde AA, Adu FD (1977). Excretion of the virus of peste des petits ruminants by goats. *Bull. Anim. Health Prod. Afr.* 25(3): 307-311.
- Abu-Elzein EME, Hassanien MM, Al-Afaleq AI, Abd-Elhadi MA, Housain FMI (1990). Isolation of peste des petits ruminants virus from goats in Saudi Arabia. *Vet. Rec.* 127: 309-310.
- Biological Diagnostic Supplies LTD (BDSL). Flow Laboratories and Institute for Animal Health, Pirbright, Surrey, England (2000). PPR competitive ELISA Kit. Competitive ELISA for detection of antibodies to P.P.R. virus. Developed in Collaboration with: The Animal Production and Health Section joint FAO/IAEA Division, IAEA, and the FAO/IAEA Central Laboratory for ELISA and molecular techniques in diagnosis of animal diseases, Vienna, Austria.
- Bundza A, Afshar A, Dukes TW, Myers DJ, Dulac GC, Becker SAWE (1988). Experimental peste des petits ruminants (Goat Plague) in goats and sheep. *Can. J. Vet. Res.* 52: 46-52.
- Carleton HM (1967). *Histological Technique*, 4th edition. New York, London and Toronto. Oxford University Press. pp. 48-58.
- Durojaiye OA (1980). Brief notes on history, epizootiology and the economic importance of PPR in Nigeria. In: *Proceedings of the International Workshop on Peste des Petits Ruminants*, IITA, Ibadan, Nigeria, 24-26 September, pp. 24-27.
- Durnell DR (1972). A disease of sokoto goats resembling "peste des petits ruminants". *Trop. Anim. Health Prod.* 4: 162-164.
- Elhag Ali B (1973). A natural outbreak of rinderpest involving sheep, goats and cattle in Sudan. *Bull. Epizoot. Dis. Afr.* 21: 421-428.
- Ezeokoli CD, Taylor WP, Diallo A (1986). Clinical and epidemiological features of Peste des petits ruminants in Sokoto red goats. *Rev. Elev. Med. Vet. Pays Trop.* 39(3-4): 219-273.
- Ismail TM, Yamanaka MK, Saliki JT, EL-Kholy A, Mebus C, Yilma T (1995). Cloning and expression of the nucleoprotein of peste des petits ruminants virus in baculovirus for use in serological diagnosis. *Virology.* 20: 776-778
- Jones L, Giavedoni L, Saliki JT, Brown C, Mebus C, Yilma T (1993). Protection of goats against peste des petits ruminants with a vaccinia virus double recombinant expressing the F and H genes of rinderpest virus. *Vaccine.* 11: 961-964.
- Karber G (1931). Beitrag zur kollektiven behandlung pharmakologischer reihenversuche. *Arch. Exp. Pathol. Pharmacol.* 162: 480-483.
- Lefevre PC, Diallo A (1990). Peste des petits ruminants. *Rev. Sci. et Tech. de l'Office Intl des Epiz.* 9:951-965.
- Mann E, Isoun TT, Fabiyi A, Odegbo-Olukoya OO (1974). Experimental transmission of the stomatitis peumoenteritis complex to sheep and goats. *Bull. Epizoot. Dis. Afr.* 22(2): 99-102.
- Nussieba AO, Mahasin EA, Ali AS, Fadol MA (2008). Rapid Detection of Peste des Petits Ruminants (PPR) Virus Antigen in Sudan by Agar Gel Precipitation (AGPT) and Haemagglutination (HA) Tests. *Trop. Anim. Health Prod.* 40(5): 363-368.
- Onoviran O, Majiyagbe KA, Molokwu JU, Chima JC, Adegboye DS (1984). Experimental infection of goats with *Mycoplasma capri* and "peste des petits ruminants" virus. *Rev. Elev. Med. Vet. Pays Trop.* 37(1): 16-18.
- Plowright W, Ferris RD (1959). Studies with rinderpest virus in tissue culture. I. Growth and cytopathogenicity. *J. Comp. Pathol.* 69(2): 152-172.
- Plowright W, Ferris RD (1962). Studies with rinderpest virus in tissue culture. A technique for the detection and titration of virulent virus in cattle. *Res. Vet. Sci.* 3: 94-103.
- Saliki JT (1998). Peste des petits ruminants. In: *Foreign Animal Diseases: The Gray Book*. 6th edition. Part IV. Richmond, VA: US Animal Health Association, Committee on Foreign Animal Diseases. pp. 344-352.
- Spearman C (1908). The method of right and wrong cases (constant stimuli) without Gauss's formulae. *Brit. J. Psychol.*, 2: 227-242.
- Taylor WP (1979). Serological studies with the virus of peste des petits ruminants in Nigeria. *Res. Vet. Sci.* 26,: 236-242.
- White G (1958). A specific diffusible antigen of rinderpest virus demonstrated by the agar double-diffusion precipitation reaction. *Nature, London*, 181: 1409.
- Wosu LO (1991). Haemagglutination test for diagnosis of peste des petits ruminants disease in goats with samples from live animals. *Small. Rumin. Res.* 5: 169-172.
- Wosu LO (1994). Current status of peste des petits ruminants (PPR) disease in small ruminants-a review article. *Stud. Res. Vet. Med.* 2:83-90.