

*Full Length Research Paper*

# Parry-Romberg syndrome: A possible association with Lyme borreliosis

Filipa Ventura<sup>1\*</sup>, Joana Gomes<sup>1</sup>, Catarina Vilarinho<sup>1</sup>, Ana Paula Vieira<sup>1</sup>, José Carlos Fernandes<sup>1</sup>, Fernando Mota Garcia<sup>2</sup> and Celeste Brito<sup>1</sup>

<sup>1</sup>Dermatology and Venereology Department, Hospital de Braga, Braga, Portugal.

<sup>2</sup>Pathology Department, Hospital de Braga, Braga, Portugal.

Accepted February 9, 2011

**Parry-Romberg syndrome or progressive facial hemiatrophy is a rare entity of unknown etiology characterized by unilateral atrophy of the skin, subcutaneous tissue and the underlying bony structures. A case of a 4-year-old girl with Parry-Romberg syndrome and borreliosis is reported. No sure link is established between these two entities but their coincident occurrence in our patient is noted.**

**Key words:** Parry-Romberg syndrome, morphea, Lyme borreliosis.

## INTRODUCTION

Parry-Romberg syndrome (PRS) or progressive facial hemiatrophy is a rare disorder, characterized by a unilateral atrophy of the skin, subcutaneous tissue and the underlying bony structures (Sahin et al., 2004). This entity is a process of unknown etiology that evolves with invalidating lesions that may be associated with different neurological, cutaneous, ocular, autoimmune or analytical abnormalities (Sahin et al., 2004; Fernandez et al., 1998). There are few reports showing the association between PRS and borreliosis. We describe the case of a child with PRS and positive findings for serological tests for *Borrelia* infection.

## CLINICAL CASE

A 4-year-old girl presented a 3-month history of an atrophic, shiny, brownish-yellow plaque of 4 cm in size on the left side of the mandible and chin. In this area, a remarkable atrophy and sclerosis of skin and underlying tissues and an ipsilateral atrophy of the tongue were present (Figure 1). The lesion was asymptomatic and not

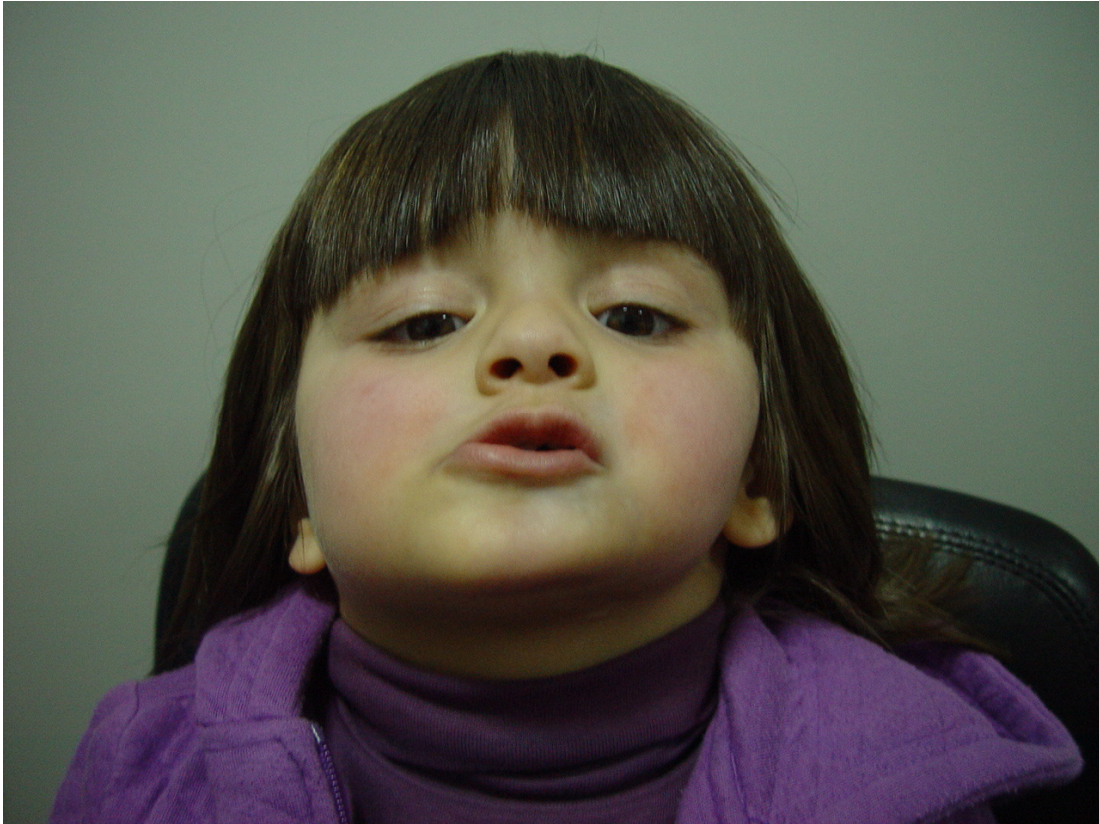preceded by trauma or tick bite. Histopathology examination was consistent with the diagnosis of morphea (Figure 2). Serum contained high-titer *Borrelia*-specific antibodies detected by ELISA and confirmed by Western blot analysis. The result showed the presence of IgG antibodies reactive against the antigens VlsE, p39, p31, p21 and p41 and IgM antibodies reactive against VlsE, OspC, p30, p21 and p41. High-titer of antinuclear antibodies was also detected (1:640, coarse speckled pattern). Neurological examination was otherwise normal as it was a brain magnetic resonance imaging. Six months after the treatment with intravenous ceftriaxone (2 g daily for 21 days) "*Borrelia*-specific serum antibodies had strongly declined, with only one distinct reactivity left in ELISA against *Borrelia afzelii* IgG". Treatment with methotrexate 7.5 mg per week was started "without improvement" of the lesions. The reconstructive surgery was postponed considering the patient's age, the location and instability of the lesions.

## DISCUSSION AND CONCLUSION

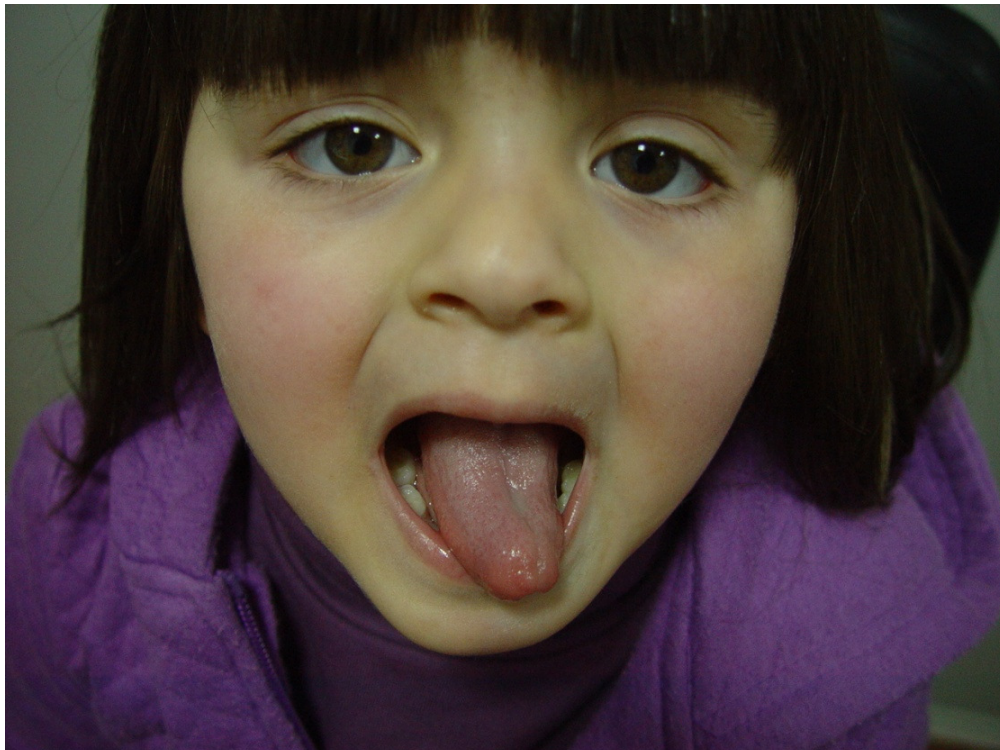PRS is considered a severe variant of linear morphea. The involvement of *Borrelia burgdorferi* as a causative agent of morphea was first proposed by Aberer et al. (1985), but this association remains controversial (Sahin et al., 2004; Fernandez et al., 1998; Pereira and Franca,

---

\*Corresponding author. E-mail: [filipmanuelventura@hotmail.com](mailto:filipmanuelventura@hotmail.com). Tel: 00351 919450375. Fax: 00351 253613334.

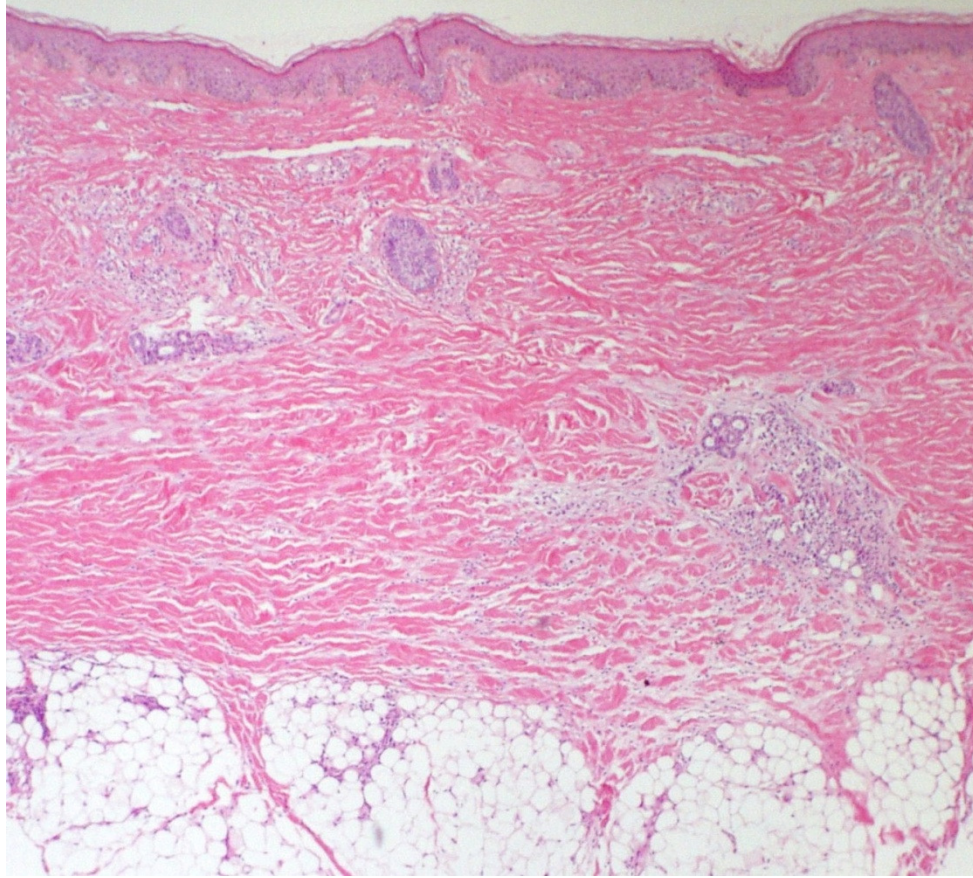


**Figure 1a.** Facial asymmetry from atrophy and sclerosis of skin and underlying tissues on the left side of the mandible and chin.



**Figure 1b.** Ipsilateral atrophy of the tongue.





**Figure 2.** Marked thickening and flattening of the bundles of collagen and perivascular inflammatory infiltrates in the dermis and accentuation of the dermal-subcutaneous junction (H and E 40 $\times$ ).

2000; Prinz et al., 2009; Zollinger et al., 2010; Buechner et al., 1993). Molecular mimicry has been proposed as a possible mechanism in the pathogenesis of auto-immune and inflammatory skin diseases. Some authors reported that a T-cell epitope of *B. burgdorferi* outer surface protein A (OspA) has significant homology with a fragment of human LFA-1 $\alpha$  and hypothesized that this could lead to an appropriately prolonged production of inflammatory mediators even after complete elimination of the spirochete (Salpietro et al., 2004). Moreover, other authors showed that expression of LFA-1 $\alpha$  and ICAM-1 is increased in the course of morphea, strengthening the idea that cross-reactivity between OspA and LFA-1 $\alpha$  could play a role in perpetuating the chronic inflammatory process, contributing to the pathogenesis of fibrosclerotic lesions (Salpietro et al., 2004).

We present the case of a 4-year-old girl with the diagnosis of PRS and serological findings compatible with a *Borrelia* infection. The coexistence of these two entities might be a coincidence but we can not ignore this association, adding the fact that PRS has devastating effects. These patients should be always evaluated for borreliosis.

Recently an aggressive variant of morphea was proposed, "*Borrelia*-associated early-onset morphea", which is characterized by the combination of disease onset at younger age, infection with *B. burgdorferi* and an auto-immune phenomena as reflected by high-titer antinuclear antibodies (Prinz et al., 2009), just like in our patient. *B. burgdorferi* infection may be relevant for the induction of a distinct autoimmune type of scleroderma. It might take a particularly severe course and require treatment of both infection and skin inflammation.

#### REFERENCES

- Buechner SA, Winkelmann RK, Lautenschlager S, Gilli L, Ruffli T (1993). Localized scleroderma associated with *Borrelia burgdorferi* infection. Clinical, histologic, and immunohistochemical observations. *J. Am. Acad. Dermatol.*, 29: 190-196.
- Fernandez O, Romero F, Salazar JA, Rodriguez-Barrionuevo C (1998). Parry-Romberg syndrome: a form of focal vasculitis. *Neurologia*, 13: 54-57.
- Prinz JC, Kutasi Z, Weisenseel P, Poto L, Battyani Z, Ruzicka T (2009). "*Borrelia*-associated early-onset morphea": A particular type of scleroderma in childhood and adolescence with high titer antinuclear antibodies? *J. Am. Acad. Dermatol.*, 60: 248-255.
- Sahin MT, Baris S, Karaman A (2004). Parry-Romberg syndrome: a

possible association with borreliosis. *J. Eur. Acad. Dermatol. Venereol.*, 1128: 204-207.

Salpietro DC, Merlino MV, Bruglia S, Guarneri F, Vaccaro M (2004). Linear scleroderma "en coup de sabre" associated with facial atrophy in a patient seropositive for *Borrelia burgdorferi*: a true case of molecular mimicry? *Pediatr. Allergy Immunol.*, 15: 570-572.

Zollinger T, Mertz KD, Schmid M, Schmitt A, Pfaltz M, Kempf W (2010). *Borrelia* in granuloma annulare, morphea and lichen sclerosus: a PCR-based study and review of the literature. *J. Cutan. Pathol.*, 37: 571-577.

