

Case Report

Legionella disease complicated by complete heart block

Jonathan G. Stine^{1*}, Omar Ragab² and Chalapathy Venkatesan²

¹Department of Internal Medicine, Georgetown University Hospital, 3800 Reservoir Rd NW Washington D.C. 20007, USA.

²Department of Medicine, INOVA Fairfax Hospital, 3300 Gallows Rd Falls Church VA 22042, USA.

Accepted 22 July, 2011

Legionella disease is a systemic infection with rare cardiac manifestations. Known cardiac presentations include myocarditis, pericarditis, endocarditis and pericardial effusion. Only two cases of conduction disturbance have been reported in adults, one in the setting of verapamil use. A 56 year-old African American woman with a history of active tobacco abuse and diabetes presented with fevers, fatigue and altered mental status and was subsequently found to have community acquired pneumonia (CAP). Initial electrocardiogram (EKG) showed 2:1 atrioventricular (AV) block in the absence of baseline conduction system disease or electrolyte abnormalities. The patient had a positive urinary Legionella antigen and was started on intravenous levofloxacin. The patient's hospital course was complicated by hypoxemic respiratory failure requiring intubation, acute renal failure, hyponatremia, elevated liver associated enzymes and progression to third degree AV block, requiring both transcutaneous and transvenous pacing. Legionella should be considered for patients who present with new onset cardiac conduction disturbance in the setting of community acquired pneumonia. Early detection and prompt treatment with intravenous antibiotics is crucial to ensure full recovery from this form of reversible, infectious heart block.

Key words: *Legionella*, heart block, pneumonia, respiratory failure.

INTRODUCTION

In adults, legionellosis is responsible for approximately 2 to 15% (Sopena et al., 1998) of all cases of community-acquired pneumonia (CAP) that require hospitalization and 8,000 to 18,000 persons are hospitalized with *Legionella* disease (LD) each year (Centers for Disease Control and Prevention, 2007). LD is a systemic infection involving both pneumonia and multiple well-known extrapulmonary manifestations including cardiac, renal, gastrointestinal and electrolyte disturbances (Cunha, 2010). While many infectious processes (Lyme disease and rheumatic fever) (Dlesk et al., 1990) are known to cause associated conduction deficits with varying degrees of atrioventricular (AV) block, cardiac involvement in LD is typically limited to myocarditis or

pericarditis and is a rare occurrence typically observed in the setting of active pneumonia (Armengol et al., 1992; Castellani et al., 1985). When reported, *Legionella* carditis itself occurs as an isolated pericarditis with effusion. However, Buke et al. (2009) published a case report of *Legionella* carditis in the absence of active pneumonia. Other rare cardiac manifestations include culture negative endocarditis of both native and prosthetic valves (Cunha, 2010). This paper details a report of third degree heart block and cardiogenic shock requiring ionotropes and both transvenous and transcutaneous pacing in the setting of multi-system LD.

Case presentation

A 56-year-old woman with a history of tobacco abuse and non-insulin dependent diabetes mellitus presented to the emergency room with a chief complaint of respiratory

*Corresponding author. E-mail: jonathan.stine@gmail.com. Tel: (202) 444-8168. Fax: (866) 303-1460.

distress associated with altered mental status for several days prior to admission. The family denied any recent travel or sick contacts. The patient had no exposure to hot tubs but was living in an inner city apartment complex. Her admission medications included phenobarbital, phenytoin, lantus, humibid, folate, albuterol, atrovent, aspirin and zovirax cream. The patient was allergic to penicillin with unknown reaction. Family history was negative for premature coronary artery disease. She denied alcohol or drug use. The patient was single but with 4 children. Admission vital signs were notable for a temperature of 102°F, blood pressure (BP) 105/72 mmHg, heart rate 52 bpm, respirations 26 per min and oxygen saturation 88% on room air. On exam, the patient was a well-nourished, well-developed African American female in mild respiratory distress alert and oriented to person only. Her sclera were anicteric, her oropharynx was clear. Her lung exam was notable for decreased breath sounds at the base with poor air movement. Her heart was bradycardic. Her abdomen was soft, nontender, mildly distended with hypoactive bowel sounds. Her extremities had 2+ peripheral edema. Neurological exam was unable to be fully completed. Initial laboratory studies included sodium 131 meq/L, potassium 3.7 meq/L, chloride 95 meq/L, bicarbonate 22 meq/L, blood urea nitrogen (BUN) 55 mg/dl, creatinine of 3.8 mg/dl, aspartate aminotransferase (AST) 182 units/L, alanine aminotransferase (ALT) 28 units/L, alkaline phosphatase 70 units/L and total bilirubin 1.5 mg/dl. Arterial blood gas showed pH 7.47, pCO₂ 24.8 meq/L, paO₂ 52.5 meq/L. Creatine phosphokinase (CPK) on admission was 22,159 units/L; Troponin was 0.61 ng/mL. Electrocardiogram (EKG) showed 2:1 heart block (Figure 1). Baseline EKG was without significant abnormality.

The patient was started on intravenous ceftriaxone and azithromycin for community acquired pneumonia (CAP) and was intubated for subsequent hypoxemic respiratory failure. On hospital day 2, her urinary *Legionella* antigen returned positive and the patient was started on intravenous (IV) levofloxacin. Blood, urine and respiratory cultures were all negative. Initial transthoracic echocardiogram showed ejection fraction 55%, hypokinesis of the posterior and inferior wall. The patient's renal function continued to decline and on hospital day 6, she was started on hemodialysis. The patient was extubated on hospital day 8. For the first week of hospitalization, the patient was intermittently in 2:1 AV and first degree AV block; however, on hospital day 9, the patient developed symptomatic bradycardia with heart rate 47 and cardiogenic shock requiring atropine and dopamine. EKG revealed complete heart block with a junctional escape rhythm, QTc 481 ms and right bundle branch block in the setting of potassium 5.7 meq/L (Figure 2). A transvenous pacemaker was placed due to her continued heart block after the normalization of potassium. Repeat echocardiogram after transvenous pacing revealed new elevations in the right ventricular

end-systolic pressure to 60 mmHg. The patient completed a 10 day course of IV levofloxacin, however, by hospital day 13 her heart block had not improved and she was transitioned to a 14 day course of Azithromycin. By hospital day 16 her intrinsic rhythm became sinus and the pacemaker was discontinued.

DISCUSSION

To our knowledge, this case demonstrates the first published report of high grade AV block associated with Legionnaire's disease. This continued despite correction of the patient's hyperkalemia. The first case of *Legionella*-induced conduction disturbance was reported in 2002 by Karim et al. (2002) and to date only one additional case has been published (Sposato et al., 2003). While the clinical spectrum of perimyocarditis has been well described by multiple case reports (Burke et al., 2009), expanding the cardiac differential diagnosis to include dysrhythmias, specifically bradyarrhythmias including sinus pauses (Karim et al., 2002), seems warranted. Conduction disturbance appears to be more common in the pediatric population (Castellani et al., 1985). In fact, conduction disturbance is not included in the Winthrop-University Hospital weighted point-scoring system for Legionnaire's disease, which instead incorporates relative bradycardia, which is defined as a significant discrepancy between the pulse rate and the temperature from what would be expected for any degree of temperature elevation (Cunha, 2008). However, QTc prolongation must also be considered given both the concurrent electrolyte abnormalities present with LD, as well as the predisposition to invoking fatal torsades de Pointes, particularly if intravenous erythromycin therapy is to be prescribed (Devriendt et al., 1990; Howden et al., 2003).

While transmission of *Legionella* is known to occur through aerosolization of contaminated water, including hot-tub use, (Sopena et al., 1998) our patient did not have this exposure. In the absence of travel, predisposing risk factors included a history of diabetes, active smoking and resultant chronic lung disease, likely COPD by chest x-ray hyperinflation; however, no formal pulmonary function testing was performed (Centers for Disease Control and Prevention, 2007). Urinary *Legionella* antigen testing should be performed as recommended by the Centers for Disease Control and Prevention (CDC) in those at risk for CAP from *Legionella* to confirm *Legionella*-induced heart block. Urinary *Legionella* antigen is the preferred test (other than sputum culture which has a notoriously low yield) for confirming a diagnosis of pulmonary or extra-pulmonary *Legionella* given the 70% sensitivity and 100% specificity of diagnostic testing (Centers for Disease Control and Prevention, 2007). The prognosis of *Legionella*-induced cardiac conduction disease remains unknown, although

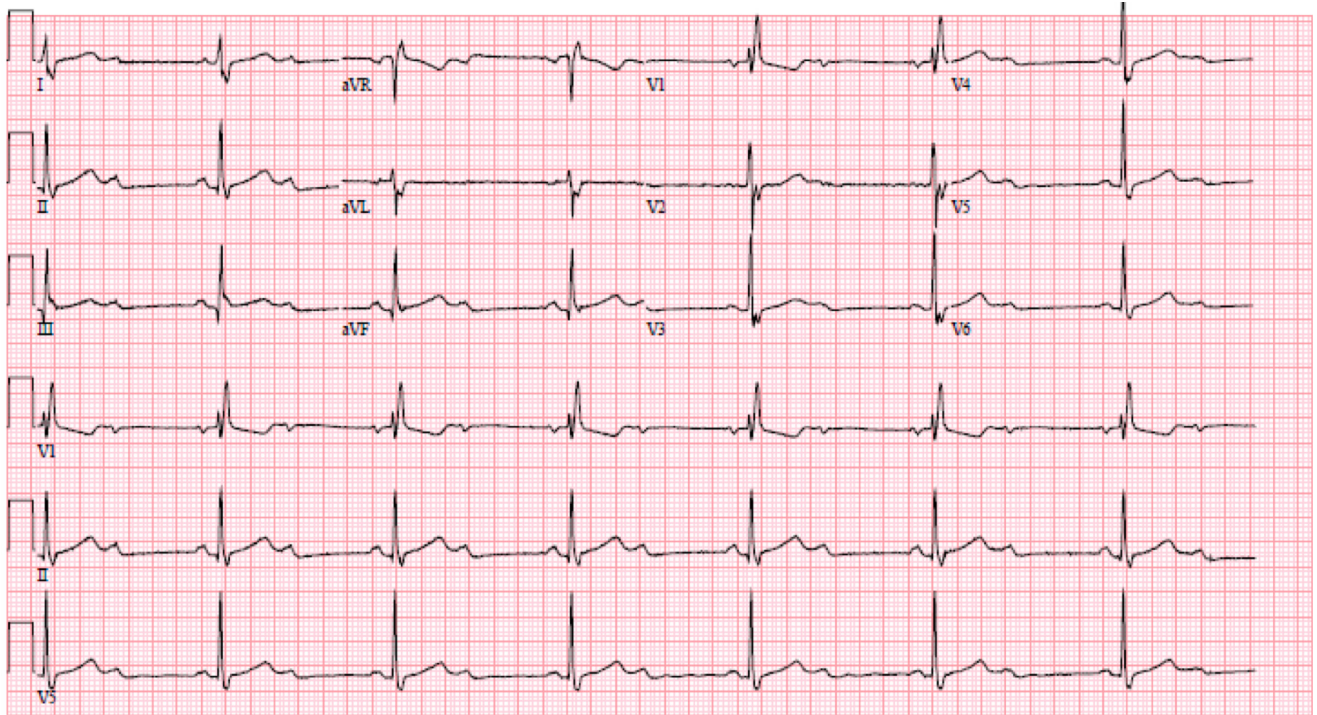


Figure 1. Admission EKG with 2:1 AV block.

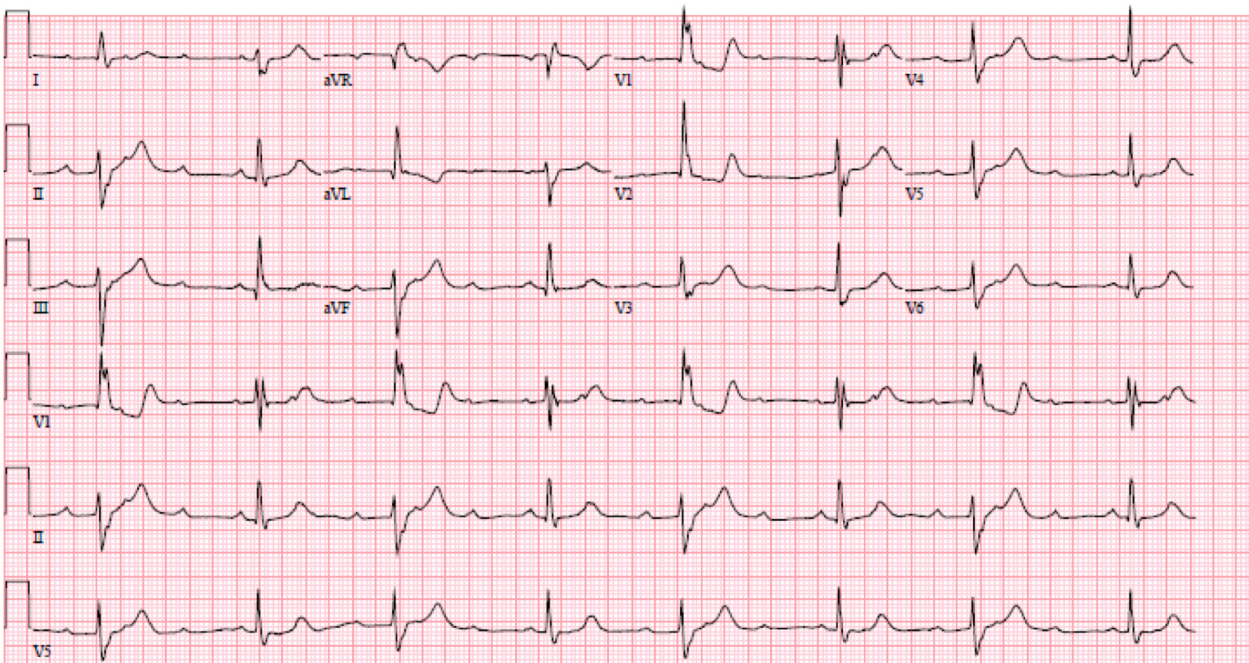


Figure 2. EKG with 3rd degree AV block.

based on previous reports as well as our case report, it appears to be reversible if promptly diagnosed and appropriate antibiotic therapy is introduced. Aggressive

supportive care with transcutaneous and transvenous pacing may be necessary, as was the case with our patient in order to allow the antibiotics time to fight the

infection and restore normal conduction.

CONCLUSION

Legionella should be considered in the differential diagnosis for patients who present with new onset cardiac conduction disturbance in the setting of community acquired pneumonia, especially if they have multiple risk factors. Early detection and prompt treatment with intravenous antibiotics is crucial to ensure full recovery from this form of reversible infectious heart block.

REFERENCES

- Sopena N, Sabria-Leal M, Pedro-Botet ML, Padilla E, Dominguez J, Morera J, Tudela P (1998). Comparative study of the clinical presentation of legionella pneumonia and other community-acquired pneumonias. *Chest.*, 113(5): 1195-200.
- Centers for Disease Control and Prevention (CDC) (2007). Surveillance for travel-associated legionnaires disease--United States, 2005-2006. *MMWR Morb Mortal Wkly Rep.*, 7; 56(48):1261-3.
- Cunha BA (2010). Legionnaires' disease: Clinical differentiation from typical and other atypical pneumonias. *Infect. Dis. Clin. North Am.*, 24(1): 73-105.
- Dlesk A, Balian AA, Sullivan BJ, Mitchell PD, Marx JJ, Jr (1991). Diagnostic dilemma for the 1990s: Lyme disease versus rheumatic fever. *Wis. Med. J.*, 90(11): 632-634.
- Armengol S, Domingo C, Mesalles E (1992). Myocarditis: A rare complication during legionella infection. *Int. J. Cardiol.*, 37(3): 418-420.
- Castellani PM, Nigro G, Midulla M (1985). Arrhythmia or myocarditis: a novel clinical form of Legionella pneumophila infection in children without pneumonia. *Eur. J. Pediatr.*, 144(2): 157-159.
- Burke PT, Shah R, Thabalingam R, Saba S (2009). Suspected legionella-induced perimyocarditis in an adult in the absence of pneumonia: A rare clinical entity. *Tex Heart Inst. J.*, 36(6): 601-603.
- Karim A, Ahmed S, Rossoff LJ (2002). Legionnaire's disease associated with acute encephalitis and arrhythmia. *Crit Care Med.*, 30(5):1028-9.
- Sposato B, Mariotta S, Ricci A, Lucantoni G, Schmid G (2003). [Legionnaire's pneumonia with rhabdomyolysis and acute renal failure. A case report]. *Recenti Prog. Med.*, 94(9): 391-394.
- Cunha BA (2008). Severe legionella pneumonia: Rapid presumptive clinical diagnosis with winthrop-university hospital's weighted point score system (modified). *Heart Lung*, 37(4):311-20.
- Devriendt J, Staroukine M, Schils E, Sivaciyan B, Van Beers D (1990). Legionellosis and "torsades de pointes". *Acta Cardiol.*, 45(4): 329-333.
- Howden BP, Stuart RL, Tallis G, Bailey M, Johnson PD (2003). Treatment and outcome of 104 hospitalized patients with legionnaires' disease. *Intern. Med. J.*, 33(11): 484-488.