

## Full Length Research Paper

# Possible therapeutic mechanisms of turmeric against colorectal cancer induced by N-methylnitrosourea in experimental models

Amal H. Hamza<sup>1,4\*</sup>, Wagdy K. B. Khalil<sup>2</sup> and Hanaa H. Ahmad<sup>3</sup>

<sup>1</sup>Biochemistry Department, Faculty of Science for Girls, King Abdulaziz University, Jeddah, KSA.

<sup>2</sup>Cell Biology Department, National Research Center, Dokki, Egypt.

<sup>3</sup>Hormones Department, National Research Center, Dokki, Egypt.

<sup>4</sup>Biochemistry and Nutrition Department, Faculty of Women, Ain Shams University, Cairo, Egypt.

Accepted 13 May, 2013

The goal of this study was to investigate some possible therapeutic mechanisms of turmeric in the treatment of colorectal cancer induced by N-methylnitrosourea. The experimental animals were divided into five groups, healthy control group, colon cancer induced group, fluorouracil (FU) treated group; the two other groups set as colon cancer induced group treated with low and high dose of successive methanolic fraction of turmeric, respectively. Biochemical results revealed significant elevation of plasma transforming growth factor- $\beta$  (TGF- $\beta$ ), serum carcinoembryonic antigen (CEA) levels, matrix metalloproteinase-7 (MMP-7) activity and colon cancer specific antigen-4 (CCSA-4) level in cancer group as compared to control group. Treatment of cancer induced rats with fluorouracil or turmeric fractions showed significant decrease in plasma TGF- $\beta$ , serum CEA levels, MMP-7 activity and CCSA-4 as compared to cancer induced group. Also, the results showed significant higher expression level of  $\beta$ -catenin, K-ras and c-myc genes in colon cancer-induced rats as compared to control group. However,  $\beta$ -catenin, K-ras and c-myc genes were down-regulated in the colon tissues of control rats and rats treated with fluorouracil and/or the turmeric extracts. Moreover, immunohistochemical results revealed significant elevation in cell count of cyclooxygenase-2 (COX-2), Cyc-D1 and survivin in cancer group as compared to healthy control group. Treatment of cancer induced rats with fluorouracil and/or turmeric fractions showed significant decrease in immunohistochemical cell count of COX-2, Cyc-D1 and survivin as compared to cancer group. These results represented good therapeutic approaches of turmeric for intervention against progressive colon cancer with special reference to the inflammation, proliferation and apoptosis.

**Key words:** Colon cancer, turmeric fractions, therapeutic mechanisms, *in vivo* study.

## INTRODUCTION

Colorectal cancer (CRC) is a malignant tumor recognized as the third most common cancer worldwide with high morbidity and mortality and the second-leading cause of cancer death in the United States (Haggard and Boushey, 2009). CRC has been postulated as a complex and multi-

stage process well established in both humans and experimental models. Development of rodent and human colon cancer includes a series of pathological alterations ranging from discrete microscopic mucosal lesions like aberrant crypt foci (ACF) to malignant tumors (Tanaka,

2009). CRC appears to be most commonly initiated by alterations that affect the Wingless/Wnt signaling pathway. The initiated colon cancer then progresses as the result of the accumulation of sequential genetic or epigenetic events that either activate oncogenes or deactivate tumor suppressor genes that are involved in other signaling pathways, such as the RAS-RAF-MAPK pathway, transforming growth factor- $\beta$  (TGF- $\beta$ ) pathway, and the phosphatidylinositol 3 kinase (PI3K)-AKT pathway (Parsons et al., 2005). The role of genetic alterations in colon cancer formation was initially suggested by the colon cancer family syndrome, familial adenomatous polyposis (FAP). One of the central tumor promoting effects of these mutations is to lead inappropriate activation of the Wingless/Wnt signaling pathway with the subsequent expression of genes that favor cell growth. The disruption of the association of APC with  $\beta$ -catenin leads to over-activation of the Wnt signaling pathway, which leads to the transcription of genes that favor tumor formation, such as c-myc or matrixin (Chung, 2000). Turmeric (the common name for *Curcuma longa*) is an Indian spice derived from the rhizomes of the plant and has a long history of use in Ayurvedic medicine as a treatment for inflammatory conditions. *C. longa* is a perennial member of the Zingiberaceae family. The primary active constituent of turmeric and the one responsible for its vibrant yellow color is curcumin, first identified in 1910 by Lampe and Milobedzka (Jurenka, 2009).

Curcumin, a popular Indian food spice derived from the rhizome of the plant *Curcuma longa* Linn. (Zingiberaceae), has been recognized as a promising anti-cancer drug due to its multiple properties including anti-inflammatory, anti-oxidant and anti-carcinogenic activities. Among the possibilities, regulation of an array of cellular biochemical processes such as inhibition of nitric oxide synthase, receptor tyrosine kinase and protein kinase C activities and the alteration of transcriptional factors cjun/AP-1 and nuclear factor  $\kappa$ B, p53 by curcumin have been suggested (Choudhuri et al., 2002). Various suggested pathways of curcumin activity include the inhibition of arachidonic acid metabolism, lipoxygenase and cyclooxygenase activity (Squires et al., 2003). Moreover, curcumin is known to modulate the activities of certain enzymes involved in the bioactivation and disposition of chemical carcinogens (Iqbal et al., 2003). Based on these observations, curcumin may be a potential cancer chemopreventive agent. Curcumin may be responsible for the lower incidence of urothelial malignancies and the lower rate of colorectal cancer in the regions where curcumin is a staple part of the diet (Kamat et al., 2007). It was reported that curcumin induced apoptosis of MBT-2 cells and G2/M arrest of T24 cells (Park et al., 2006). Moreover, curcumin effectively inhibited tumor implantation and growth in a mouse intravesical tumor implantation model and prevented OH-BBN-induced bladder carcinogenesis in the rodent model carcinogenesis systems (Zafar et al., 2003). Thus, the

aim of the current study was to elucidate the possible mechanisms by which turmeric might show antitumorogenic properties against colorectal cancer.

## MATERIALS AND METHODS

### Preparation of turmeric successive methanolic fraction (TSMF)

The successive methanol fraction of turmeric was prepared by adding 300 ml of methanol (70%) to 50 g of turmeric after applying petroleum ether (250 ml for 50 g powdered turmeric for 6 h) and left for 10 to 12 h. The fraction was filtered using filter paper and the solvent was evaporated using rotary evaporator. The resultant extract was dehydrated in an oven at 50°C for 24 h (Sasaki et al., 2003).

### Experimental design

Sixty adult male Sprague-Dawley rats weighting 150 to 170 g were obtained from the Animal House Colony of the National Research Centre, Cairo, Egypt and were acclimated for one week in a specific pathogen free (SPF) barrier area, temperature ( $25 \pm 1^\circ\text{C}$ ) and humidity (55%). The rats were controlled constantly with a 12 h light/dark cycle at National Research Centre Animal Facility Breeding Colony. The rats were housed with *ad libitum* access standard laboratory diet consisting of casein 10%, salts mixture 4%, vitamins mixture 1%, corn oil 10% and cellulose 5% completed to 100 g with corn starch (A.O.A.C., 1995). Animal cared for according to the guidelines for animal experiments which were approved by the Ethical Committee of Medical Research of the National Research Centre, Cairo, Egypt.

After the acclimatization period, the rats in the current study were classified into 5 groups (12 rats/group). The first group: set as healthy control group received orally 1 ml of vehicle (Dimethyl sulfoxide (DMSO) 5% in saline) for 21 weeks. The second group: set as colon cancer induced group (cancer) in which the rats were intrarectally injected with N-methylnitrosourea in a dose of 2 mg dissolved in 0.5 ml water/rat three times weekly for 5 weeks (Nariswa and Fukaura, 2003). Then, they received vehicle (DMSO, 5% in saline) orally for 16 weeks. The third group: set as fluorouracil-treated group (fluorouracil) in which the rats were intrarectally injected with N-methylnitrosourea for 5 weeks and then intraperitoneally treated with 5-fluorouracil in a dose of 12.5 mg/kg on days 1, 3 and 5 with the cycle being repeated every 4 weeks over the duration of the study period (4 months) (Asao et al., 1992). The fourth group: assigned as successive turmeric methanolic fraction-treated group (TSMF low) in which the rats were intrarectally injected with N-methylnitrosourea for 5 weeks and then orally treated with low dose (333.3 mg/kg) of TSMF daily for 4 months. The fifth group: set as successive turmeric methanolic fraction-treated group (TSMF high) in which the rats were intrarectally injected with N-methylnitrosourea for 5 weeks and orally treated with high dose (666.6 mg/kg) of TSMF daily for 4 months. The selected doses of the turmeric fractions were calculated according to the chronic toxicity study in the current work (data are not shown).

At the end of the experimental period, the rats were fasted overnight and subjected to diethyl ether anesthesia. The blood samples were immediately collected from the retro orbital venous plexus and divided into two tubes, the first tube contains anticoagulant agent for separation of plasma samples and the second tube is free from any anticoagulant agent for separation of serum samples for biochemical analysis. Then, the rats were sacrificed by cervical dislocation and the colon was dissected and divided into two portions, the first portion was preserved in formalin saline (10%) for histological investigation and immunohistochemical

analysis and the second portion was collected in liquid nitrogen and was stored at  $-80^{\circ}\text{C}$  for molecular genetics analysis.

### Biochemical analysis

Plasma TGF- $\beta$  level was determined by enzyme linked immunosorbent assay (ELISA) technique using TGF- $\beta$  assay kit purchased from WKEA MED SUPPLIES Co., New York, USA according to the instructions provided with TGF- $\beta$  assay kit. Serum carcinoembryonic antigen (CEA) level was detected by ELISA technique using CEA assay kit according to the method of Schwartz (1987). Serum matrix metalloproteinase-7 (MMP-7) activity was assayed using MMP-7 assay kit according to the method of Nagase et al. (1999). Serum colon cancer specific antigen-4 (CCSA-4) level was estimated by ELISA technique using CCSA-4 assay kit according to the manufacture instructions.

### Molecular genetic analysis (expression of $\beta$ -catenin, K-ras and c-myc genes): Isolation of total RNA

Total RNA was isolated from colon tissues by the standard TRIzol® Reagent extraction method (cat#15596-026, Invitrogen, Germany). The complete Poly(A)<sup>+</sup> RNA isolated from male rat colon tissues was reverse transcribed into cDNA in a total volume of 20  $\mu\text{l}$  using RevertAid™ First Strand cDNA Synthesis Kit (MBI Fermentas, Germany). An amount of total RNA (5  $\mu\text{g}$ ) was used with a reaction mixture, termed as master mix (MM). The MM consists of 50 mM MgCl<sub>2</sub>, 5x reverse transcription (RT) buffer (50 mM KCl; 10 mM Tris-HCl; pH 8.3; 10 mM of each dNTP, 50  $\mu\text{M}$  oligo-dT primer, 20 U ribonuclease inhibitor (50 kDa recombinant enzyme to inhibit RNase activity) and 50 U $\mu$ -MuLV reverse transcriptase. The mixture of each sample was centrifuged for 30 s at 1000 g and transferred to the thermocycler (Biometra GmbH, Göttingen, Germany). The RT reaction was carried out at  $25^{\circ}\text{C}$  for 10 min, followed by 1 h at  $42^{\circ}\text{C}$ , and the reaction was stopped by heating for 5 min at  $99^{\circ}\text{C}$ . Afterwards, the reaction tubes containing RT preparations were flash-cooled in an ice chamber until being used for DNA amplification through semi-quantitative real time-polymerase chain reaction (sqRT-PCR).

### sqRT-PCR

An iQ5-BIO-RAD Cyclor (Cepheid, USA) was used to determine the rats cDNA copy number. PCR reactions were set up in 25  $\mu\text{l}$  reaction mixtures containing 12.5  $\mu\text{l}$  1x SYBR® Premix Ex Taq™ (TaKaRa, Biotech. Co. Ltd.), 0.5  $\mu\text{l}$  0.2  $\mu\text{M}$  sense primer, 0.5  $\mu\text{l}$ , 0.2  $\mu\text{M}$  antisense primer, 6.5  $\mu\text{l}$  distilled water, and 5  $\mu\text{l}$  of cDNA template. Each experiment included a distilled water control.

Primer sequences for  $\beta$ -catenin: 5'-CAAT GGG TCA TAT CAC AGA TTC TT-3', 5'-TCT CTT TTC TTC ACC ACA ACA TTT-3' (Austinat et al., 2008). sqRT-PCR of the previous gene were normalized on the expression values of  $\beta$ -actin gene ( $\beta$ -actin-F: 5'-CCC CAT CGA GCA CGG TAT TG -3',  $\beta$ -actin-R ATG GCG GGG GTG TTG AAG GTC) (Eshak et al., 2010), for K-ras, 5'- AGT ACG ACC CTA CGA TAG AGG ACT CCT-3' (92 to 118) and 5' - CAA TCT GTA CTG TCG GAT CTC TCT CAC C - 3' (Fuentes-Calvo et al., 2010), and for c-myc (GenBank accession number Z38066) were upstream: 5'-TGA CGA GAC CTT CGT GAA GA-3' (453–472 bp) and downstream: 5'-ATT GAT GTT ATT TAC ACT TAA GGG T-3' (821–845 bp) (Tao et al., 2002). At the end of each sqRT-PCR a melting curve analysis was performed at  $95.0^{\circ}\text{C}$  to check the quality of the used primers.

### Immunohistochemical analysis

The second portion of fixed colon cancer tissue of rats in the

different studied groups was washed in tap water, and then serial dilutions of alcohol (methyl, ethyl and absolute ethyl) were used for dehydration. Specimens were cleared in xylene and embedded in paraffin at  $56^{\circ}$  in hot air oven for 24 h. Paraffin bees wax tissue blocks were prepared for sectioning transversely at 4  $\mu\text{m}$  by sledge microtome. Sections were fixed in a  $65^{\circ}\text{C}$  oven for 1 h.

Rabbit polyclonal primary antibody (Cyclooxygenase-2 (COX-2) Cat# RB-9072-R7, Thermoscientific, CA-USA, cyclin D1 Cat# RB-9041-R7, Thermoscientific, CA-USA, and survivin Cat# RB-9245-R7, Thermoscientific, CA-USA) were used in immunohistochemical assay. Henceforward, poly horseradish peroxidase (HRP) enzyme conjugate was applied to each slide for 20 min. 3,3' Diaminobenzidine (DAB) chromogen was prepared and 2 to 3 drops were applied on each slide for 2 min. DAB was rinsed, after which counterstaining with Mayer hematoxylin and cover slipping were performed as the final steps before slides were examined under the light microscope. Image J software (NIH, version v1.45e, USA) was calibrated and the image is opened on the computer screen for image analysis.

### Histopathological methods for colon tissues investigations

After fixation of colon tissues in formalin saline (10%) for 24 h, one portion of colon tissues of rats in the different studied groups was washed in tap water, then serial dilutions of alcohol (methyl, ethyl and absolute ethyl) were used for dehydration. Specimens were cleared in xylene and embedded in paraffin at  $56^{\circ}$  in hot air oven for 24 h. Paraffin bees wax tissue blocks were prepared for sectioning transversely at 4  $\mu\text{m}$  by sledge microtome. The obtained tissue sections were collected on glass slides, deparaffinized and stained by hematoxylin and eosin stain and examined through the electric light microscope (Banchroft et al., 1996).

### Statistical analysis

The results of the study were expressed as mean + standard error (SE) of the mean. Data were analyzed by one way analysis of variance (ANOVA) using the Statistical Package for the Social Sciences (SPSS) program, version 11. Difference was considered significant when P value was  $< 0.05$ .

## RESULTS

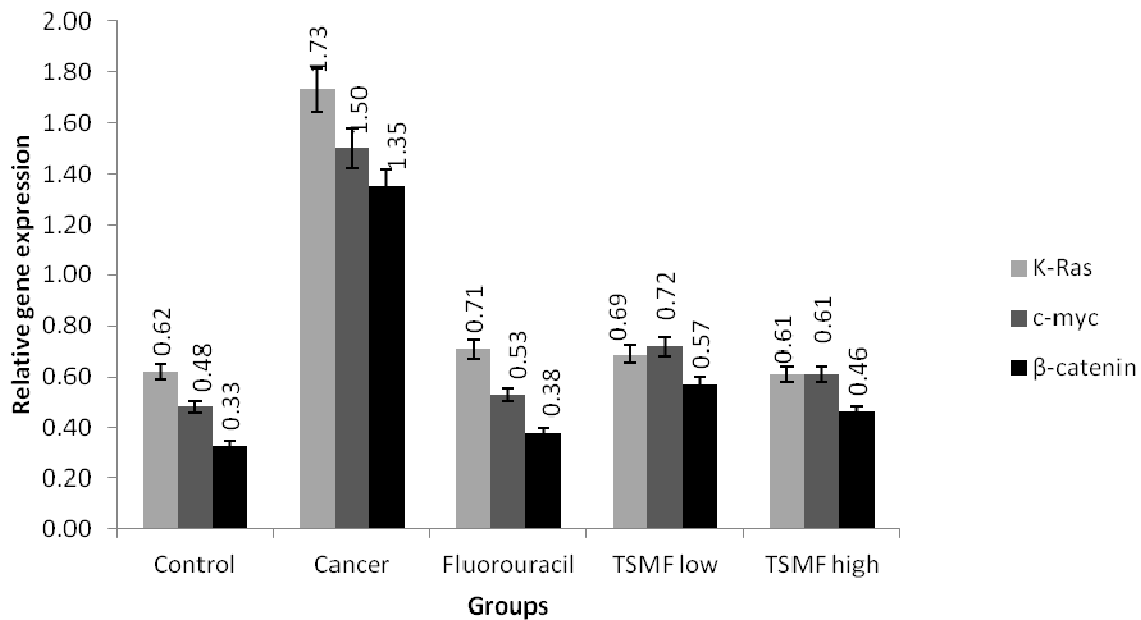
The biochemical results of the present study revealed significant elevation in the level of plasma TGF- $\beta$ , serum CEA, MMP-7 and CCSA-4 in cancer induced group as compared to healthy control group ( $P < 0.05$ ). While cancer induced rats treated with turmeric fractions (TSMF) or fluorouracil showed significant reduction in these parameters as compared to untreated cancer induced group as shown in Table 1.

It is clear from the molecular genetic analysis that the gene expression of  $\beta$ -catenin, K-ras and c-myc were significantly up-regulated in the colon tissues of untreated cancer induced rats. However, the expression level of  $\beta$ -catenin, K-ras and c-myc genes were significantly down regulated in rats treated with turmeric fractions (TSME) and fluorouracil as compared to untreated cancer induced group as shown in Figure 1. The effect of TSME in modulating genetic alteration was not dose dependent, but both doses were safe as were concluded from our

**Table 1.** Effect of turmeric fractions on biochemical parameters (TGF- $\beta$ - CEA, MMP-7 and CCSA) levels in experimental group.

Group	TGF- $\beta$ (pg/ml)	CEA (ng/ml)	MMP-7 (ng/ml)	CCSA (ng/ml)
Control	29.33 $\pm$ 1.68	2.59 $\pm$ 0.065	0.18 $\pm$ 0.015	69.46 $\pm$ 3.43
Cancer	42.52 $\pm$ 2.13 <sup>a</sup> (45.42%)	4.32 $\pm$ 0.14 <sup>a</sup> (66.67%)	0.27 $\pm$ 0.024 <sup>a</sup> (47.85%)	98.98 $\pm$ 2.24 <sup>a</sup> (42.49%)
Fluorouracil	30.63 $\pm$ 3.61 <sup>b</sup> (-28.2%)	2.89 $\pm$ 0.12 <sup>b</sup> (-32.93%)	0.18 $\pm$ 0.013 <sup>b</sup> (-33.02%)	70.83 $\pm$ 1.51 <sup>b</sup> (-28.43%)
TSMF (low dose)	33.81 $\pm$ 3.37 (-20.74%)	2.98 $\pm$ 0.06 <sup>b</sup> (-30.88%)	0.19 $\pm$ 0.018 <sup>b</sup> (-28.75%)	78.34 $\pm$ 2.19 <sup>bc</sup> (-20.85%)
TSMF (high dose)	33.46 $\pm$ 3.5 (-21.56%)	2.98 $\pm$ 0.086 <sup>b</sup> (-31.02%)	0.19 $\pm$ 0.015 <sup>b</sup> (-28.88%)	76.83 $\pm$ 2.13 <sup>b</sup> (-22.37%)

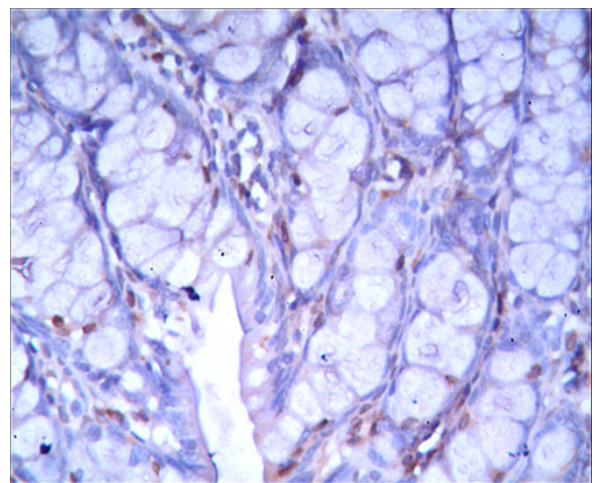
Data are expressed as means  $\pm$  standard error (SE). <sup>a</sup>Significance change at  $p < 0.05$  in comparison with -ve control group. <sup>b</sup>Significance change at  $p < 0.05$  in comparison with cancer group. <sup>c</sup>Significance change at  $p < 0.05$  in comparison with Fluorouracil group. %: Percent of difference with respect to the corresponding control value.

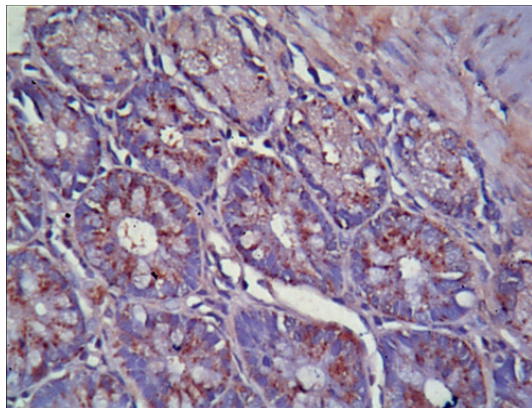
**Figure 1.** Effect of turmeric fractions on gene expression of k-ras, c-myc and beta-catenin in all experimental groups.

previous toxicological studies (data are not shown).

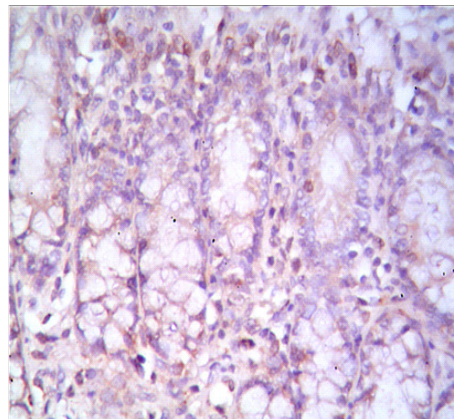
Immunohistochemical results of the current study were illustrated as shown in Figures 2 to 16. The results revealed significant elevation ( $P < 0.05$ ) in immunohistochemical cell count of COX-2, Cyc D1 and survivin in cancer induced group as compared with healthy control group. While cancer induced rats treated with turmeric fractions or fluorouracil showed significant reduction ( $P < 0.05$ ) in immunohistochemical cell count of COX-2, Cyc D1 and survivin as compared to cancer induced group.

Histological investigation of colon sections of healthy control group showed normal histological structure of the mucosa, submucosa and muscularis layers (Figure 17). While sections in colon cancer-induced group showed dysplasia and anaplasia associated with pleomorphism and hyperchromachia in the lining epithelial cells of the glandular structure (Figure 18). Moreover, colon cancer-induced rats treated with 5-fluorouracil showed few

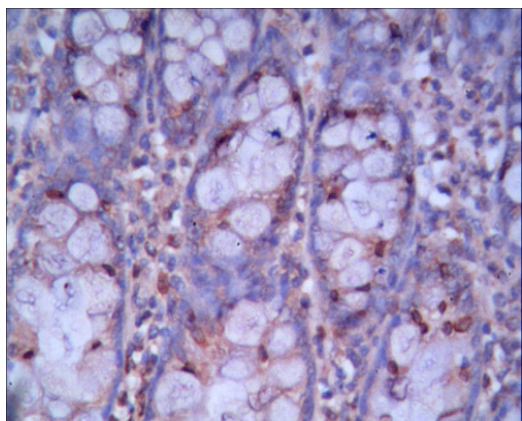
**Figure 2.** Photograph for immunohistochemical staining of negative control colon tissue using antibody against cox-2 showed mild positive reaction in interstitial stromal cells (160x).



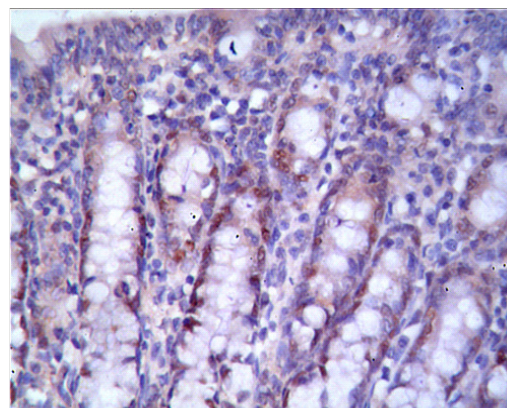
**Figure 3.** Photograph for immunohistochemical staining of colon cancer tissue using antibody against cox-2 showed very severe positive reaction in cytoplasm of the glandular lining epithelium (160x).



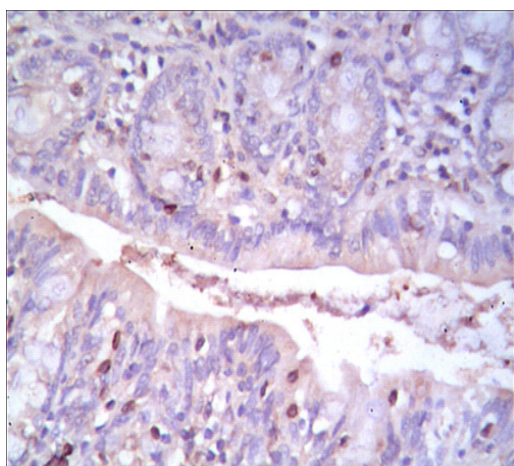
**Figure 6.** Photograph for immunohistochemical staining of colon cancer- induced rats treated with high dose of TSMF using antibody against cox-2 showed moderate positive reaction in the stromal interstitial cells in a ratio of 20% (80x).



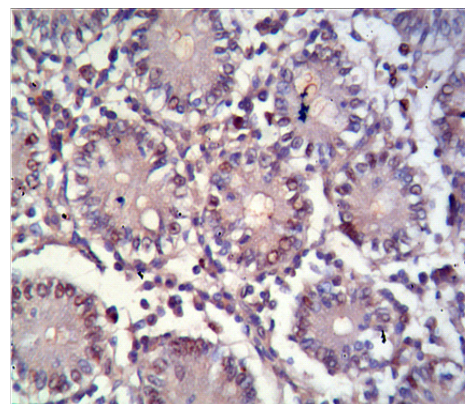
**Figure 4.** Photograph for immunohistochemical staining of colon cancer- induced group treated with 5-fluorouracil using antibody against cox-2 showed moderate positive reaction in the nuclei of the glandular lining epithelium (160x).



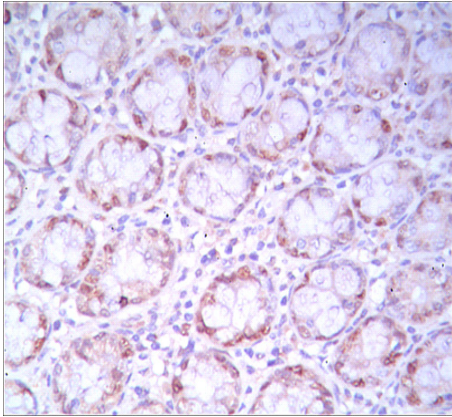
**Figure 7.** Photograph for immunohistochemical staining of negative control colon tissue using antibody against using antibody against cyclin D1 showed positive reaction in the nuclei of the glandular lining.



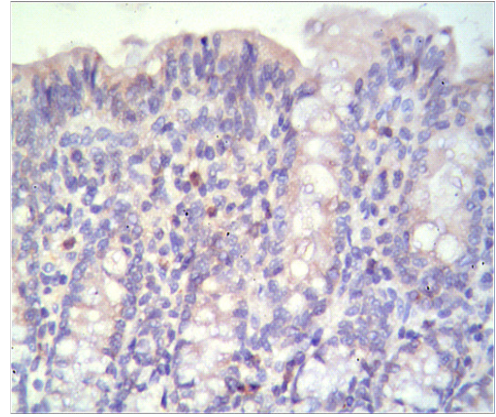
**Figure 5.** Photograph for immunohistochemical staining of colon cancer- induced rats treated with low dose of TSMF using antibody against cox-2 showed moderate positive reaction in the nuclei of stromal interstitial cells and few in glandular epithelium (160x).



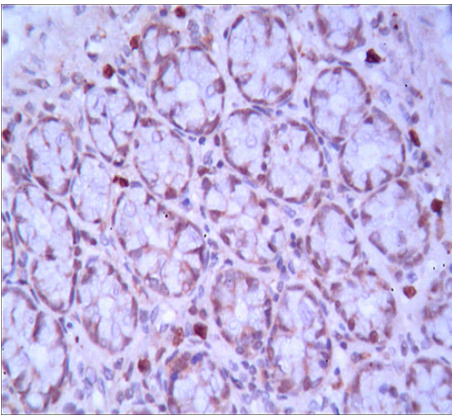
**Figure 8.** Photograph for immunohistochemical staining of colon cancer tissue using antibody against cyclin D1 showed very severe positive reaction in the nuclei of the glandular lining epithelial cells as well as the interstitial stromal cells (160x).



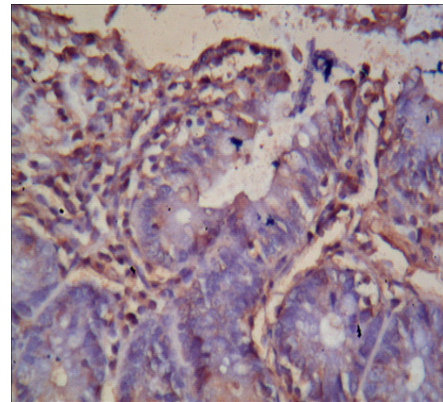
**Figure 9.** Photograph for immunohistochemical staining of colon cancer- induced group treated with 5-fluorouracil using antibody against cyclin D1 showed moderate positive reaction in the nuclei of the glandular lining epithelial (80x).



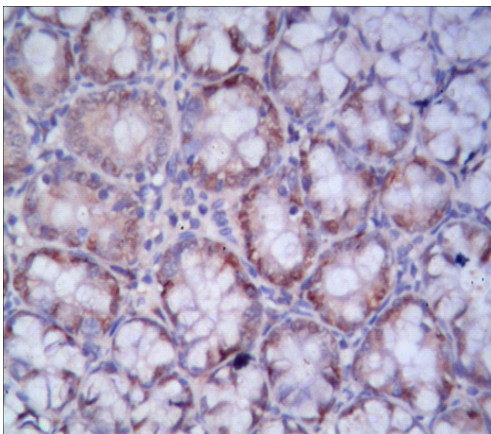
**Figure 12.** Photograph for immunohistochemical staining of negative control colon tissue using antibody against survivin showed mild negative reaction except some few interstitial stromal cell especially in their nuclei (80x).



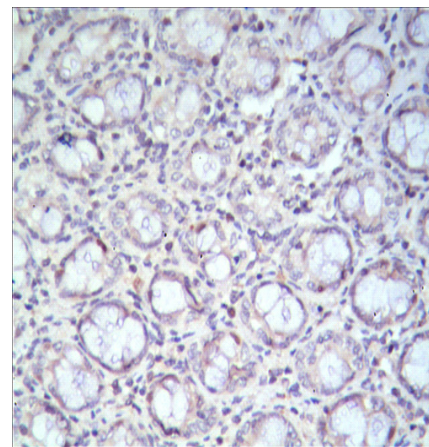
**Figure 10.** Photograph for immunohistochemical staining of colon cancer- induced rats treated with low dose of TSMF using antibody against cyclin D1 showed moderate positive reaction in the nuclei of the glandular lining epithelial as well as interstitial stromal cell (80x).



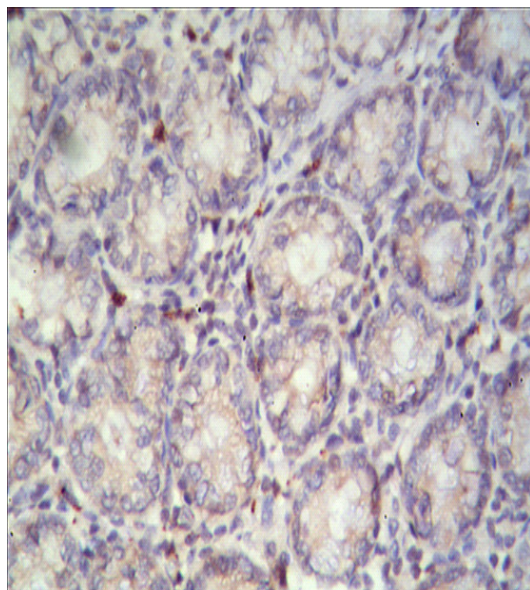
**Figure 13.** Photograph for immunohistochemical staining of colon cancer tissue using antibody against survivin showed very severe positive reaction in the nuclei of interstitial stromal cell as well as some nuclei of lining glandular epithelial cells (160x).



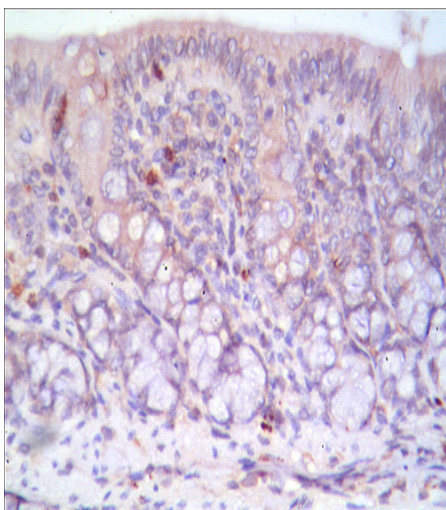
**Figure 11.** Photograph for immunohistochemical staining of colon cancer- induced rats treated with high dose of TSMF using antibody against cyclin D1 showed moderate positive reaction in the nuclei of the glandular lining epithelial.



**Figure 14.** Photograph for immunohistochemical staining of colon cancer- induced group treated with 5-fluorouracil using antibody against survivin showed mild positive reaction in the nuclei of the glandular lining epithelial cells as well as stromal interstitial cells (80x).



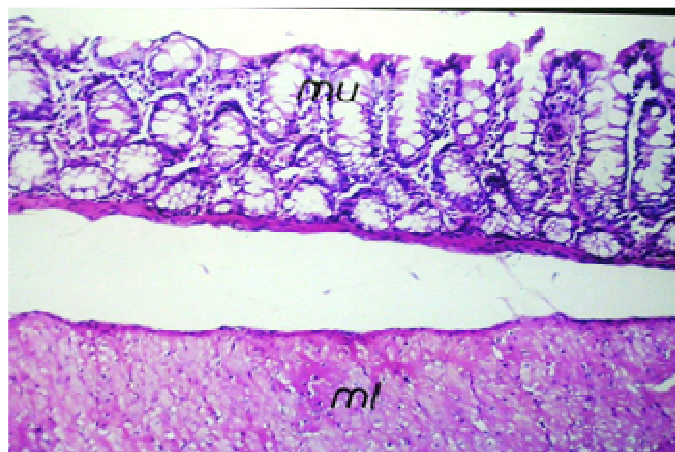
**Figure 15.** Photograph for immunohistochemical staining of colon cancer- induced rats treated with low dose of TSMF using antibody against survivin showed mild positive reaction in interstitial stromal cells (160x).



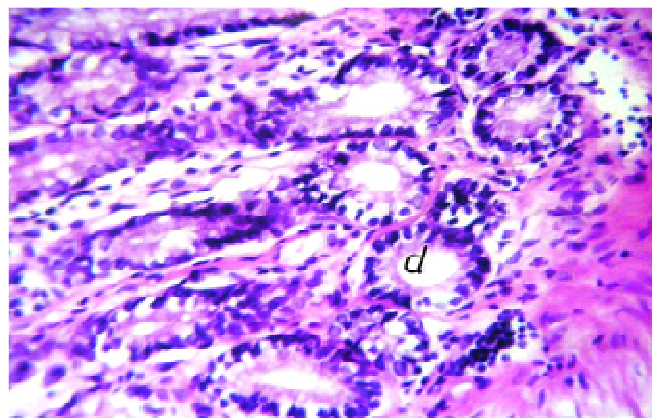
**Figure 16.** Photograph for immunohistochemical staining of colon cancer- induced rats treated with high dose of TSMF using antibody against survivin showed mild positive reaction in interstitial stromal cells (160x).

inflammatory cells infiltration in the lamina propria of the mucosa with oedema in muscularis (Figures 19 and 20).

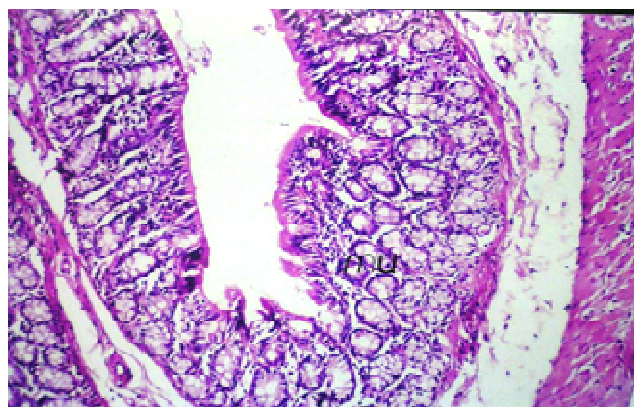
On the other hand microscopic investigation of colon section of cancer-induced rats treated with low dose of TSME showed normal histological structure of the mucosa with mild oedema in muscularis (Figure 21). Also, colon section of cancer-induced rats treated with high dose of TSME showed mild edema in muscularis and serosa (Figure 22).



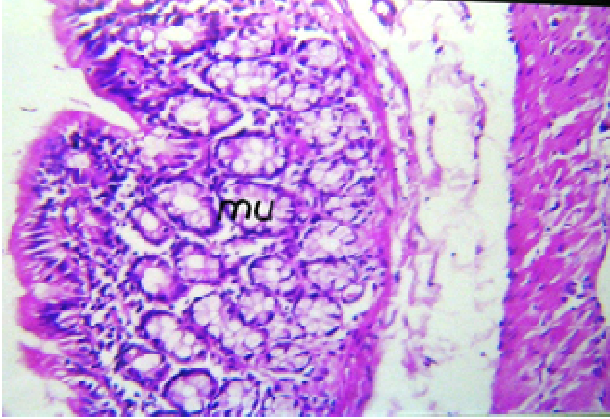
**Figure 17.** A photomicrograph of colon section of male control rat showed normal histological structure of the mucosa (mu), submucosa (s) and muscularis (ml) layers. (H&E X40).



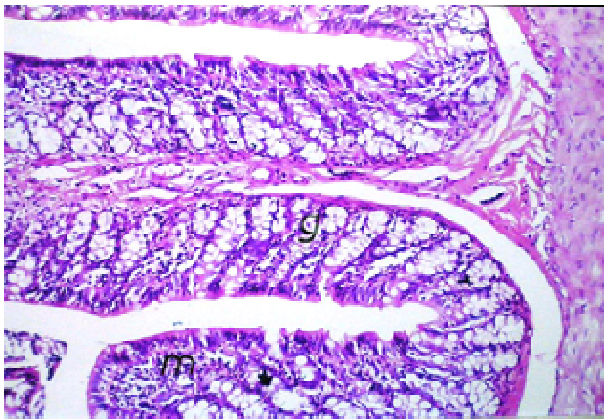
**Figure 18.** A photomicrograph of colon section of colon cancer-induced rats showed dysplasia and anaplasia associated with pleomorphism and hyperchromachia in the lining epithelial cells of the glandular structure (d) (H&E X64).



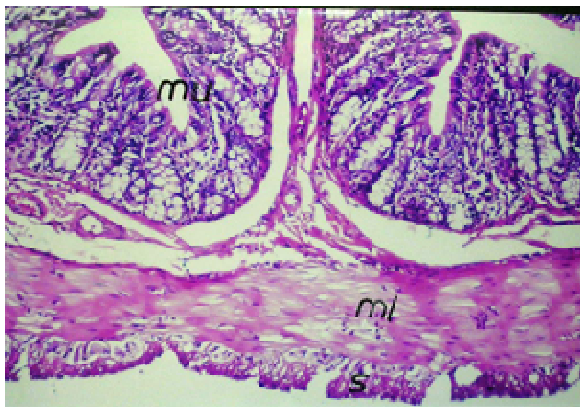
**Figure 19.** A photomicrograph of colon section of colon cancer-induced rats treated with 5-fluorouracil showed few inflammatory cells infiltration in the lamina propria of the mucosa (mu) with oedema in muscularis (ml) (H&E X40).



**Figure 20.** A photomicrograph of colon section fluorouracil group showed the magnification of Figure 19 to identify few inflammatory cells infiltration in the lamina propria of the mucosa (mu) (H&E X64).



**Figure 21.** A photomicrograph of colon section of colon cancer-induced rats treated with low dose of TSMF showed no histopathological alteration (H&E X40).



**Figure 22.** A photomicrograph of colon section of colon cancer-induced rats treated with high dose of TSMF showed mild inflammatory cells infiltration in the lamina propria of the mucosa (mu) with oedema in muscularis (ml) (H & E X40).

## DISCUSSION

The goal of cancer chemoprevention is to slow, block, or reverses the process of carcinogenesis through the use of natural or synthetic compounds. For a variety of reasons naturally occurring dietary substances over synthetic agents are preferred by patients to prevent cancer. This approach has largely focused on targeting deregulated intracellular pathways that have been implicated in abnormal cellular function. As a result, there has been an increasing interest in dietary compounds that have an innate ability to modify these pathways thereby delaying process of carcinogenesis (Khan et al., 2007).

The results in this study revealed that there was significant increase in TGF- $\beta$ , MMP-7, CEA and CCSA-4 level in cancer group. High levels of TGF- $\beta$ 1 in the primary colorectal tumor are associated with advanced stages and a greater likelihood of recurrence and decreased survival (Robson et al., 1996). Experimentally, TGF- $\beta$  stimulates the proliferation and invasion of poorly differentiated and metastatic colon cancer cells (Schroy et al., 1999). It was proposed that elevated blood levels of CEA indicate metastasis and poor prognosis. There is increasing evidence that CEA is involved in multiple biological aspects of neoplasia such as cell adhesion, metastasis, suppression of cellular immune mechanisms, and inhibition of apoptosis (Taheri et al., 2003). Moreover, the MMPs are frequently overexpressed in various human cancers. It is noteworthy that only matrilysin and membrane type-1 MMP (MT1-MMP) are produced by colorectal cancer cells themselves and because of the strong extracellular membrane matrix (ECM) degradative activity, much evidence supports the role of MMP-7 in tumorigenesis and progression *in vitro*, and in the animal models (Yamamoto et al., 1994).

Colon cancer-specific antigen CCSA-4 is novel colon cancer markers identified by focused proteomic analysis of nuclear structural proteins. It has been found that both CCSA-3 and CCSA-4 are expressed before the onset of colon cancer, therefore they are considered useful as markers of early detection. Leman et al. (2007) showed that both CCSA-3 and CCSA-4 can be used as highly specific and sensitive serum-based markers for detecting individuals with colon cancer and separating them from those with other benign diseases and cancer types as well as normal individuals. It is also clear from the present study that treatment of cancer induced group with fluorouracil decreased the levels of TGF- $\beta$ , CEA, MMP-7 and CCSA-4; these finding were supported by Fang et al. (2009) and Ghiringhelli et al. (2009).

Treatment with turmeric fractions in colon cancer-induced rats resulted in significant suppression of the plasma level of tumor biomarker TGF- $\beta$  as shown in our results which was is in agreement with the study of Song et al. (2011). These results support the novel role of turmeric as potential inhibitor of apoptosis caused by reduced production of TGF- $\beta$ . TGF- $\beta$  level was



significantly blocked by turmeric in a dose dependent manner. Also, the study revealed the inhibitory effect of turmeric extract on colon cancer biomarkers CEA, CCSA-4 and MMP7 levels. Our biochemical results were strongly supported by the present molecular, immunohisto-chemical and histopathological analysis which revealed the strong antiinflammatory and antitumorigenic effect of turmeric extract against colon cancer-induced rats.

The ability of curcumin to inhibit matrix metalloproteins is well established in prostate and breast cancer. However, the colo205 cell line when treated with curcumin was noted to decrease the levels of MMP-2, promote MMP-9 activities and had no effect on MMP-7 (Johnson and Muktar, 2007). The antiinflammatory mechanisms implicated in the anticarcinogenic potential of curcumin include: inhibition of NF- $\kappa$ B and Cox-2, inhibition of arachidonic acid metabolism via lipoxygenase and scavenging of free radicals generated in this pathway, decreased expression of inflammatory cytokines IL-1, IL-6, and TNF- $\kappa$ , resulting in growth inhibition of cancer cell lines and down-regulation of enzymes, such as protein kinase C, that mediate inflammation and tumor-cell proliferation (Jurenka, 2009). During initiation and promotion, curcumin modulates transcription factors controlling phase I and II detoxification of carcinogens; down-regulates proinflammatory cytokines, free radical-activated transcription factors, and arachidonic acid metabolism via cyclooxygenase and lipoxygenase pathways; and scavenges free radicals. In the promotion and progression stages of carcinogenesis, curcumin decreases frequency and size of tumors and induces apoptosis via suppression of NF- $\kappa$ B and AP-1 in several cancer types (Jurenka, 2009).

The present study revealed significant increase in the gene expression level of  $\beta$ -catenin, K-ras and c-myc in colon tissue of colon-induced rats. This finding is in agreement with that in the previous studies of Takahashi and wakabayashi (2004) and Haigis et al. (2008). When  $\beta$ -catenin is mutated,  $\beta$ -catenin cannot be degraded but accumulates in the cytoplasm and translocates into the nucleus, where it binds to T-cell factor (TCF) and activates the wnt target genes. Thus, the gene that codes for  $\beta$ -catenin can function as an oncogen. Mutations in this gene are a cause of colorectal cancer (Bordonaro, 2009). Also, mutations in the k-ras gene are responsible for activation of the k-ras pathway which is implicated in colon carcinogenesis in humans and rats (Jancik et al., 2010). Mutations of proto-oncogenes ras are most commonly found in colorectal carcinoma, appearing early in the process of carcinogenesis, already in the phase of hyperproliferating epithelium, in anaplastic crypt foci (ACF), in adenocarcinomas and cancers. Moreover, c-myc has been found to be over expressed in several stages of chemically-induced rat colon carcinogenesis (Wali et al., 2002). The c-myc gene is frequently deregulated and overexpressed in colon malignancy, and

strategies designed to inhibit c-myc expression in cancer cells may have considerable therapeutic value (Hongxing et al., 2008).

Treatment with turmeric fraction in colon cancer-induced rats led to significant reduction in  $\beta$ -catenin, K-ras and C-myc gene expression level in colon tissue as shown in the current data. Curcumin induced the activation of caspase-3, which in turn, mediated the cleavage of  $\beta$ -catenin, decreased the transactivation of  $\beta$ -catenin/Tcf-Lef, and decreased promoter DNA-binding activity of the  $\beta$ -catenin/Tcf-Lef complex (Jaiswal et al., 2002). Curcumin appears to interact with all of the key pathways associated with the adenoma-adenocarcinoma sequence including APC, TP53, K-ras and c-myc (Irving et al., 2011). There is *in vivo* evidence that curcumin can prevent disease propagation by modulating cellular mechanisms involved in proliferation, angiogenesis and metastasis. The suggested mechanism for the inhibition of k-ras gene expression level due to treatment with turmeric extract and fraction in colon cancer-induced rats is the ability of curcumin to suppress the activation of Akt. On the other hand, the proposed mechanism for decreasing the expression of c-myc is related to the Cox-2 inhibitory activity of curcumin (Shehzad et al., 2010).

Our data revealed that there was significant elevation in Cox-2, cyclin D1 and survivin expression in colon tissue of colon cancer-induced rats. This finding is in consistent with that of Takahashi and Wakabayashi (2004), Nie et al. (2012), Mao et al. (2011) and Jin et al. (2012). The mechanism of increased Cox-2 expression in our study may be related to k-ras mutation and/or protein activation which increased Cox-2 expression in tumors (Bissonnette et al., 2000). Over expression of cyclin D1 protein was also found in colon cancer (Shan et al., 2009). The study of Mae et al. (2011) provided the first evidence that increased activation of signal transducer and activator of transcription-5 (Stat5) may contribute to the malignancy of colonic adenocarcinoma through overexpression of cyclin D1.

Also, our results showed that 5-fluorouracil significantly down regulates Cox-2, cyclin-D and survivin expression. This results go hand in hand with Srimuangwong et al. (2012). Moreover, Chow et al. (2005) support a potential therapeutic role of 5-fluorouracil as Cox-2 inhibitors in human breast cancer. Wen et al. (2010) found that 5-fluorouracil-triggered apoptosis of DN-HIF-transfected A549 cells was reduced by si cyclin D1 introduction. Furthermore Sawai *et al.* (2010) confirmed the invasion-inhibitory effect of 5-fluorouracil on survivin-3B gene-transfected DLD-1 cells.

Treatment with turmeric fractions in colon cancer-induced rats results in significant depletion in Cox-2, cyclin- D1 and survivin expression colon tissue. Curcumin has the ability to inhibit Cox-2, but not Cox-1 gene expression in colon carcinogenesis (Goel et al., 2001). This effect is due to the inhibition of the I( $\kappa$ )B kinase (IKK) signaling complex. Curcumin has been

found to suppress TNF-induced NF- $\kappa$ B dependent gene products (COX-2, cyclin D1 and c-myc) involved in colorectal cancer cell proliferation (Aggarwal and Shishodia, 2006). Curcumin also downregulated mRNA expression and inhibited the activity of cyclin D1 promoter-dependent reporter gene expression. Thus, curcumin downregulates cyclin D1 expression through the activation of both transcriptional and posttranscriptional mechanisms, and this might contribute to the antiproliferative effects of curcumin (Aggarwal et al., 2003).

In this study, turmeric fractions down regulate survivin expression which confirms the antiapoptotic effect of turmeric. The ability of curcumin to induce apoptosis selectively in cancerous cells contributes to its anticancer potential. The mechanisms responsible for apoptosis induction by curcumin include the release of cytochrome c and modulation of cell survival and death signaling pathways involving Akt, NF- $\beta$ B, AP-1, or JNK and downregulation of the expression of survival genes and inhibitor of apoptosis (IAP) (Sharma et al., 2005).

Histological examination of colon tissue section of rats received intrarectal dose of 2 mg N-methylnitrosourea for five weeks (cancer group) revealed dysplasia and anaplasia associated with pleomorphism and hyperchromachia in the lining epithelial cells of the glandular structure (adenocarcinoma). This histopathological feature is in consistent with that in the studies of Ousingsawat et al. (2007) which confirmed the induction of colon carcinogenesis in rats.

Histological investigation of colon tissue section of colon cancer-induced rats treated with 5-fluorouracil (fluorouracil group) showed the presence of few inflammatory cells infiltration in the lamina propria of the mucosa with oedema in the muscularis. These findings are in agreement with those in El-Malt et al. (2003) study. The influence of fluorouracil on colonic carcinoma showed conflicting results and its influence mainly comes from its growth inhibitory effects on cancer cells (El-Malt et al., 2003).

The observed improvement in the histological feature of colon tissue due to administration of turmeric could be attributed to its active constituent curcumin. Curcumin has been shown to suppress multiple signaling pathways and inhibit cell proliferation, invasion, metastasis and angiogenesis. Moreover, curcumin can induce apoptosis and cell cycle arrest in colon cells (Kunnumakkara et al., 2008).

Based on our results, it was concluded that turmeric fraction has a promising therapeutic role against colon cancer induced by N-methylnitrosourea as indicated by the observed improvement in the measured biochemical, molecular and immunohistochemical markers as well as histopathological investigation. These effects were achieved through the powerful anti-inflammatory properties, antiproliferative and apoptotic effects of the active constituents of turmeric which is mainly curcumin. These results represented good therapeutic approaches for

intervention against progressive of colon cancer with special reference to the inflammation, proliferation and apoptosis.

## REFERENCES

- A.O.A.C (1995). Official methods of analysis. 16 th ed. Association of official analysis, Wahington DC.
- Aggarwal BB, Kumar A, Bharti AC (2003). Anticancer potential of curcumin: Preclinical and clinical studies. *Anticancer Res.* 23(1A):363–398.
- Aggarwal BB, Shishodia S (2006). Molecular targets of dietary agents for prevention and therapy of cancer. *Biochem. Pharmacol.* 14:71(10):1397-1421.
- Asao T, Takayuki A, Shibata HR, Batist G, Brodt P (1992). Eradication of hepatic metastases of carcinoma H-59 combination chemoimmunotherapy with liposomal muramyl tripeptide, 5-fluorouracil, and leucovorin. *Cancer Res.* 52:6254-6257.
- Austinat M, Dunsch R, Wittekind C, Tannappel A, Gebhardt R, Gaunitz F (2008). Correlation between beta-catenin mutations and expression of Wnt-signaling target genes in hepatocellular carcinoma. *Mol. Cancer.* 8(7):21.
- Banchroft JD, Stevens A, Turner DR (1996). Theory and practice of histological techniques. 4th ed. Philadelphia, USA, pp. P25-90.
- Bissonnette M, Khare S, von Lintig FC, Wali RK, Nguyen L, Zhang Y, Hart J, Skarosi S, Varki N, Boss GR, Brasitus TA (2000). Mutational and nonmutational activation of p21ras in rat colonic azoxymethane-induced tumors: effects on mitogen-activated protein kinase, cyclooxygenase-2, and cyclin D1. *Cancer Res.* 60(16):4602-4609.
- Bordonaro M (2009). Modular Cre/lox system and genetic therapeutics for colorectal cancer. *J. Biomed. Biotechnol.* 2009:358230.
- Choudhuri T, Pal S, Aggarwal M L, Das T, Sa G (2002). Curcumin induces apoptosis in human breast cancer cells through p53-dependent Bax induction. *FEBS Lett.* 512(1–3):334-340.
- Chow LW, Loo WT, Wai CC, Lui E L, Zhu L, Toi M (2005). Study of COX-2, Ki67, and p53 expression to predict effectiveness of 5-fluorouracil, epirubicin and cyclophosphamide with celecoxib treatment in breast cancer patients. *Biomed Pharmacother. Suppl.* 2:298-301.
- Chung D (2000). The genetic basis of colorectal cancer: insights into critical pathways of tumorigenesis. *Gastroenterol.* 119:854-865.
- El-Malt M, Ceelen W, Van den C, Broecke Cl, Cuvelier S, Van Belle B, de Hemptinne P (2003). Pasty Influence of Neo-Adjuvant Chemotherapy with 5-Fluorouracil on Colonic Anastomotic Healing : Experimental Study in Rats. *Actachirbelg.* 103:309-314
- Eshak MG, Ghaly IS, Khalil WB, Farag IM, Ghanem KZ (2010). Genetic alterations induced by toxic effect of thermally oxidized oil and protective role of tomatoes and carrots in mice. *J. Am. Sci.* 6(4):175-188.
- Fang YJ, Pan ZZ, Li LR, Lu ZH, Zhang LY, Wan DS (2009). MMP7 expression regulated by endocrine therapy in ERbeta-positive colon cancer cells. *J. Exp. Clin. Cancer Res.* 28:132.
- Fuentes-Calvo I, Blázquez-Medela AM, Santos E, López-Novoa JM, Martínez-Salgado C (2010). Analysis of k-ras nuclear expression in fibroblasts and mesangial cells. *PLoS One* 14:5(1):e8703
- Ghiringhelli F, Guiu B, Chauffert B, Ladoire S (2009). Sirolimus, bevacizumab, 5-Fluorouracil and irinotecan for advanced colorectal cancer: a pilot study. *World J. Gastroenterol.* 15(34):4278-83.
- Goel A, Boland CR, Chauhan DP (2001). Specific inhibition of cyclooxygenase-2 (COX-2) expression by dietary curcumin in HT-29 human colon cancer cells. *Cancer Lett.* 172(2):111-118.
- Haggag FA, and Boushey P (2009). Colorectal cancer epidemiology: incidence, mortality, survival, and risk factors. *Clin. Colon. Rectal. Surg.* 22:191-197.
- Haigis KM, Kendall KR, Wang Y, Cheung A, Haigis MC, Glickman JN, Niwa-Kawakita M, Sweet-Cordero A, Sebolt-Leopold J, Shannon KM, Settleman J, Giovannini M, Jacks T (2008). Differential effects of oncogenic K-Ras and N-Ras on proliferation, differentiation and tumor progression in the colon. *Nat. Genet.* 40:600-608.
- Hongxing Z, Nancai Y, Wen S, Guofu H, Yanxia W, Hanju H, Qian L, Wei M, Yandong Y, Hao H (2008). Depletion of c-Myc Inhibits Human

- Colon Cancer Colo 320 Cells' Growth. *Cancer Biother. Radio pharmaceut.* 23(2):229-237.
- Iqbal M, Sharma SD, Okazaki Y, Fujisawa M, Okada S (2003). Dietary supplementation of curcumin enhances antioxidant and phase II metabolizing enzymes in ddY male mice: possible role in protection against chemical carcinogenesis and toxicity. *Pharmacol. Toxicol.* 92(1):3338.
- Irving GR, Karmokar A, Berry DP, Brown K, Steward WP (2011). Curcumin: the potential for efficacy in gastrointestinal diseases. *Best Pract. Res. Clin. Gastroenterol.* 25(4-5):519-534.
- Jaiswal AS, Marlow BP, Gupta N, Narayan S (2002). Beta-catenin-mediated transactivation and cell-cell adhesion pathways are important in curcumin (diferuylmethane)-induced growth arrest and apoptosis in colon cancer cells. *Oncogene.* 21(55):8414-27.
- Jancik S, Drábek J, Radzioch D, Hajdúch M (2010). Clinical relevance of KRAS in human cancers. *J. Biomed. Biotechnol.* pp. 1-3.
- Jin JS, Tsao TY, Sun PC, Yu CP, Tzao C (2012). SAHA inhibits the growth of colon tumors by decreasing histone deacetylase and the expression of cyclin D1 and survivin. *Pathol. Oncol. Res.* 18(3):713-720.
- Johnson JJ, Mukhtar H (2007). Curcumin for chemoprevention of colon cancer. *Cancer Lett.* 255:170-181.
- Jurenka JS (2009). Anti-inflammatory Properties of Curcumin, a Major Constituent of *Curcuma longa*: A Review of Preclinical and Clinical Research. *Alt. Med. Rev.* 14:2
- Kamat AM, Sethi G, Aggarwal BB, Paneau C, Schaffer P, Bollack C (2007). Curcumin potentiates the apoptotic effects of chemotherapeutic agents and cytokines through down-regulation of nuclear factor-kappaB and nuclear factor-kappaB-regulated gene products in IFN-alpha-sensitive and IFN-alpha-resistant human bladder cancer cells [Epidemiology of bladder cancer]. *Mol. Cancer Ther.* 6(3):1022-1030.
- Khan N, Afaq F, Mukhtar H (2007). Apoptosis by dietary factors: the suicide solution for delaying cancer growth. *Carcinogenesis.* 28(2):233-239.
- Kunnumakkara AB, Anand P, Aggarwal BB (2008). Curcumin inhibits proliferation, invasion, angiogenesis and metastasis of different cancers through interaction with multiple cell signaling proteins. *Cancer Lett.* 269:199-225.
- Leman ES, Schoen RE, Weissfeld JL, Cannon GW, Sokoll LJ, Chan DW, Getzenberg RH (2007). Initial analyses of colon cancer-specific antigen (CCSA)-3 and CCSA-4 as colorectal cancer-associated serum markers. *Cancer Res.* 67:5600-5605.
- Mao Y, Li Z, Lou C, Zhang Y (2011). Expression of phosphorylated Stat5 predicts expression of cyclin D1 and correlates with poor prognosis of colonic adenocarcinoma. *Int. J. Colorectal Dis.* 26(1):29-35.
- Nagase H, Woessner JF (1999). Matrix metalloproteinase. *J. Biol. Chem.* 30: 274(31), 21491-21494.
- Nariswa T, Fukaura Y (2003). Prevention by intrarectal 5-aminosalicylic acid of N-methylnitrosourea-induced colon cancer in F344 rats. *Dis. Colon Rectum.* 46(7):900-903.
- Nie J, Liu L, Zheng W, Chen L, Wu X, Xu Y, Du X, Han W (2012). microRNA-365, down-regulated in colon cancer, inhibits cell cycle progression and promotes apoptosis of colon cancer cells by probably targeting Cyclin D1 and Bcl-2. *Carcinogenesis.* 33(1):220-225.
- Ousingsawat J, Spitzner M, Puntheeranurak S, Terracciano L, Tornillo L, Bubendorf L, Kunzelmann K, Schreiber R (2007). Expression of voltage-gated potassium channels in human and mouse colonic carcinoma. *Clin. Cancer Res.* 13(3):824-831.
- Park C, Kim GY, Kim GD, Choi BT, Park YM, Choi YH (2006). Induction of G2/M arrest and inhibition of cyclooxygenase-2 activity by curcumin in human bladder cancer T24 cells. *Oncol. Rep.* 15(5):1225-1231.
- Parsons DW, Wang TL, Samuels Y, Bardelli A, Cummins JM, DeLong L, Silliman N, Ptak J, Szabo S, Willson JK, Markowitz S, Kinzler KW, Vogelstein B, Lengauer C, Velculescu VE (2005). Colorectal cancer: mutations in signalling pathway. *Nature* 436(7052):792.
- Robson H, Anderson E, James RD, Schofield PF (1996). Transforming growth factor beta 1 expression in human colorectal tumours: an independent prognostic marker in a subgroup of poor prognosis patients. *Br. J. Cancer.* 74:753-758.
- Sasaki Y, Goto H, Tonda C, Hatanaka F, Shibahara N, Shimada Y, Terasawa K, Komatsu K (2003). Effects of Curcuma drugs on vasomotion in isolated rat aorta. *Biol. Pharm. Bull.* 26:1135-1143.
- Sawai K, Goi T, Hirono Y, Katayama K, Yamaguchi A (2010). Survivin-3B gene decreases the invasion-inhibitory effect of colon cancer cells with 5-fluorouracil. *Oncol. Res.* 18(11-12):541-547.
- Schroy P, Rifkin J, Coffey R J, Winawer S, Friedman E (1999). Role of transforming growth factor beta1 in induction of colon carcinoma differentiation by hexamethylene bisacetamide. *Cancer Res.* 50:261-265.
- Schwartz MK (1987). Tumor markers in diagnosis and screening. In: Ting SW, Chen JS, Schwartz MK, eds. *Human tumor markers*, Amsterdam. pp. 3-16.
- Shan BE, Wang MX, Li RQ (2009). Quercetin inhibits human SW480 colon cancer growth in association with inhibition of cyclin D1 and survivin expression through Wnt/beta-catenin signaling pathway. *Cancer Investig.* 27:604-612.
- Sharma RA, Gescher A J, Steward W P (2005). Curcumin: the story so far. *Eur. J. Cancer.* 41:1955-1968.
- Shehzad A, Wahid F, Lee YS (2010). Curcumin in cancer chemoprevention: molecular targets, pharmacokinetics, bioavailability, and clinical trials. *Arch Pharm (Weinheim).* 343(9):489-99.
- Song K, Peng S, Sun Z, Li H, Yang R (2011). Curcumin suppresses TGF- signaling by inhibition of TGIF degradation in scleroderma fibroblasts. *Bio.Biophys.Res. Commun.* 411:821-825.
- Squires MS, Hudson EA, Howells L, Sale S, Houghton CE, Jones JL, Fox LH, Dickens M, Prigent SA, Manson MM (2003). Relevance of mitogen activated protein kinase (MAPK) and phosphatidylinositol-3-kinase/protein kinase B (PI3K/PKB) pathways to induction of apoptosis by curcumin in breast cells, *Biochem. Pharmacol.* 65(3):361-376.
- Srimuangwong K, Tocharus C, Yoysungnoen P, Suksamran A, Tocharus J (2012). Hexahydrocurcumin enhances inhibitory effect of 5-fluorouracil on HT-29 human colon cancer cells. *World J. Gastroenterol.* 18(19):2383-2389.
- Taheri M, Saragovi HU, Stanners CP (2003). The adhesion and differentiation inhibitory activities of the immunoglobulin super family member, carcinoembryonic antigen, can be independently blocked. *J. Biol. Chem.* 278:14632-14639.
- Takahashi M, Wakabayashi K (2004). Gene mutations and altered gene expression in azoxymethane-induced colon carcinogenesis in rodents. *Cancer Sci.* 95(6):475-480.
- Tanaka T (2009). Colorectal carcinogenesis: review of human and experimental animal studies. *Journal of Carcinogenesis* 8: 5.
- Tao L, Kramer PM, Wang W, Yang S, Lubet RA, Steele VE, Pereira MA (2002). Altered expression of c-myc, p16 and p27 in rat colon tumors and its reversal by short-term treatment with chemopreventive agents. *Carcinogenesis* 23(9):1447-1454.
- Wali RK, Khare S, Treiakova M, Cohen G, Nguyen L, Hart J, Wang J, Wen M, Ramaswamy A, Joseph L, Sitrin M, Brasitus T, Bissonnette M (2002). Ursodeoxycholic acid and F(6)-D(3) inhibit aberrant crypt proliferation in the rat azoxymethane model of colon cancer: roles of cyclin D1 and E-cadherin. *Cancer Epidemiol Biomarkers Prev.* 11(12):1653-1662.
- Wen W, Ding J, Sun W, Wu K, Ning B, Gong W, He G, Huang S, Ding X, Yin P, Chen L, Liu Q, Xie W, Wang H (2010). Suppression of cyclin D1 by hypoxia-inducible factor-1 via direct mechanism inhibits the proliferation and 5-fluorouracil-induced apoptosis of A549 cells. *Cancer Res.* 70(5):2010-2019.
- Yamamoto H, Itoh F, Hinoda Y (1994). Expression of matrilysin mRNA in colorectal adenomas and its induction by truncated fibronectin. *Biochem Biophys Res. Commun.* 201:657-664.
- Zafar SS, Hampton JA, Keck RW, Selman SH (2003). Curcumin prevents AY27 bladder transitional cell tumor growth in Fisher 344 rats. *J. Urol.* 169(4):194.