

*Full Length Research Paper*

# **Effect of aqueous extract of *Ocimum gratissimum* on acetaminophen induced renal toxicity in male wistar rats**

**Okerulu Linda<sup>1</sup>, Celestine Ani<sup>2\*</sup>, Choice Nworgu<sup>1</sup>, Igwe Uzoma<sup>3</sup>, Ugwuishi Emeka<sup>2</sup> and Nwachukwu Daniel<sup>1</sup>**

<sup>1</sup>Department of Physiology, College of Medicine, University of Nigeria, Enugu Campus, Nigeria.

<sup>2</sup>Department of Human Physiology, College of Medicine, Enugu State University of Science and Technology, Parklane, Enugu, Nigeria.

<sup>3</sup>Department of Physiology, Faculty of Basic Medical Sciences, Alex Ekwueme Federal University, Ndufu-Alike, Ebonyi State, Nigeria.

Received 15 September, 2018; Accepted 4 October, 2018

The need for an alternative means of managing renal toxicity has become necessary instead of kidney transplant. This study investigated the effect of aqueous extract of *Ocimum gratissimum* (AEOG) on acetaminophen (ACE) induced renal toxicity. Twenty-five male Wistar rats were assigned into five groups (1, 2, 3, 4, and 5) with five rats in each group. Group 1 served as the normal control and received normal saline as placebo. Group 2 served as the negative control and received 500 mg/kg of ACE orally for 21 days. Groups 3, 4 and 5 served as the treatment groups and received 100, 200 and 400 mg/kg AEOG in addition to 500 mg/kg ACE orally for 21 days. The animals were sacrificed on the 22nd day. Blood was collected for the biochemical analysis (serum creatinine, urea and electrolytes). The kidney was harvested, rinsed in 1% KCl and preserved in 10% formaldehyde solution for the histological examination. The phytochemical analysis indicates the presence of tannins, flavonoids, saponin, alkaloids, phenols, phlobatamin, anthraquinone, terpenoids, steroids, cardiac glycosides and absence of cardenolides and chalcones. Biochemical analysis showed significant increase in creatinine and urea levels in the negative control groups when compared with the normal control while there was no significant decrease in both creatinine and urea in the treatment groups when compared with the negative control. There was no significant difference ( $p > 0.05$ ) in the serum electrolytes ( $\text{Na}^+$ ,  $\text{K}^+$ ,  $\text{Cl}^-$  and  $\text{HCO}_3^-$ ). The histological examination showed mild and moderate healing of the renal tissues in the treatment groups when compared with the negative control group which showed severely damaged renal tissues. Based on the aforementioned observations, it was concluded that AEOG possessed ameliorative effect in ACE induced renal toxicity.

**Key words:** Renal toxicity, acetaminophen, *Ocimum gratissimum*, rats, electrolytes.

## **INTRODUCTION**

Plants have been an old companion of man providing food, shelter, wealth and have helped in maintaining

\*Corresponding author. E-mail: [anicelestine2006@gmail.com](mailto:anicelestine2006@gmail.com). Tel: +2348034607689 or +2348159416345.

Author(s) agree that this article remain permanently open access under the terms of the [Creative Commons Attribution License 4.0 International License](https://creativecommons.org/licenses/by/4.0/)

relatively good health by its preventive and curative potentials when properly utilized (Kumar et al., 2011). *O. gratissimum* (commonly known as scent leaf) is known as Nchuanwu or Ahuji in Igbo, Effirin in Yoruba, Daidoya in Hausa and Aramogbo in Edo (Ephrain et al., 2000). It is used mainly to flavor food and meat (Okigbo et al., 1977). It is known to contain alkaloids, tannins, phytates, flavonoids and oligosaccharides (Ijeh et al., 2004). The plant is commonly used in folk medicine to treat different diseases such as upper respiratory tract infections, diarrhea, headache, and diseases of the eye (Adebolu et al., 2005). It has been shown to possess antibacterial activity (Ofokansi et al., 2003), antioxidant properties (Oboh et al., 2008), antimicrobial and antihelminthic activities (Sofowora, 2008), hepatoprotective properties (Gbolade et al., 2009). There have been speculations that scent leaves may possess hypoglycemic activity in streptozotocin induced diabetic rats (Egesie et al., 2006).

The kidney is important for the regulation of body fluids and electrolytes. It is also a major excretory organ for waste substances like creatinine and urea (Nwangwu et al., 2015). Creatinine and urea are major catabolic products of carbohydrate and protein metabolism respectively. The reduction in creatinine concentration in the urine is indicative of impaired renal function (Smith et al., 1990). Accumulation of urea and creatinine in the serum is indicative of kidney impairment (Nisha et al., 2017). The excretion of body fluid with reduced amounts of potassium, sodium and water intake restriction, as well as excessive intake of potassium may result in rare conditions of hyperkalemia and hypernatremia, respectively (Kang et al., 2002). In spite of several scientific reports on *O. gratissimum*, there are couple of studies on *O. gratissimum* on its effect on the kidney (Ogundipe et al., 2017). The incidence of kidney failure or chronic kidney failure has doubled over the last 15 years (Arhgooro et al., 2012). Most of the patients who suffer from kidney disease are not able to afford the cost of kidney transplant. *O. gratissimum* has been reported to possess medicinal properties and it is used in most local dishes/foods especially here in South East, Nigeria; there is need to investigate its effect on the kidney with an aim in establishing its usefulness or otherwise in preventing renal impairment.

Therefore, this work is aimed at investigating the effect of aqueous extract of *O. gratissimum* on acetaminophen induced renal toxicity in male Wistar rats using these renal biomarkers, serum creatinine level, serum urea level, serum electrolytes, and histology of the kidney.

## MATERIALS AND METHODS

### Collection of plant sample, identification and authentication

The fresh leaves of *O. gratissimum* were purchased from a local market in Enugu State. A sample of the leaf of this plant was identified and authenticated at the herbarium section of the Department of Plant Science and Biotechnology, University of

Nigeria Nsukka. A voucher specimen was deposited in the herbarium for further reference with no. (UNH350a).

### Preparation of extract

The aqueous extraction of the leaves of *O. gratissimum* was carried out according to the method of Ojo et al. (2013). The leaves were washed and air dried at room temperature, pulverized using a laboratory mechanical grinder and the fine powder obtained and stored until needed. Seven hundred grams of the powdered sample was extracted with 1 L of distilled water (via maceration) for 48 h. The mixture was decanted and filtered using sterile Whatman filter paper No. 1. The filtrate was concentrated to dryness using a water-bath at a temperature of 50°C giving a dark-green paste with a yield of 8.8%. The extract was later reconstituted such that 1 g of the paste was dissolved in 10 ml of normal saline to make up the concentration of the stock solution which was labeled appropriately and refrigerated at 4°C until required for use.

$$\% \text{ Yield} = \frac{\text{weight of extract}}{\text{weight of sample}} \times 100$$

$$\frac{61.8}{700} \times \frac{100}{1}$$

$$\% \text{ Yield} = 8.8\%$$

### Phytochemical screening

Phytochemical screening was carried out using the method of Ighodalo et al. (2012).

### Acute toxicity study

The modified method of Nirmala et al. (2012) was used to assess the acute oral toxicity of *O. gratissimum* leaves. Healthy Wistar rats weighing (140 to 180 g) were used for this purpose. Four doses of 500, 1000, 2000 and 4000 mg/kg of the extract were given to 4 groups containing 4 animals in each group. Single dose of the extract was administered orally to each animal. The animals were observed individually during the first 30 min and thereafter 24 h for a period of 14 days. Signs of toxicity, body weight, feed and water intake for each group was observed every day for 14 days. The extract was devoid of toxicity even at a dose of 4000 mg/kg by oral route in rats. Hence, 100, 200 and 400 mg/kg doses of the extract were selected for this experiment.

### Experimental design

Twenty five male Wistar rats with weights ranging from 100 to 200 g were obtained from the Animal House of Faculty of Basic Medical Sciences, University of Nigeria, Enugu Campus. The animals were acclimatized for two weeks at 12 h light/dark cycle at a normal room temperature of 27±0.05°C with the standard laboratory conditions. The animals were housed in clean well-ventilated, standard wire mesh cages which were cleaned daily. They were also fed with normal rat chow (Vital Feeds Ltd Jos, Plateau State) and clean tap water *ad libitum* and divided as follows:

- Group 1: Normal control and received normal saline as placebo;
- Group 2: Received 500 mg/kg of ACE orally for 21 days. (Negative control);
- Group 3: Received 100 mg/kg AEOG;
- Group 4: Received 200 mg/kg AEOG;
- Group 5: Received 400 mg/kg AEOG and 500 mg/kg ACE orally for

**Table 1.** Phytochemical analysis of *O. gratissimum* showed that tannins, flavonoids, saponins, alkaloids, phenols and reducing sugar were present while anthraquinones and steroids were absent.

Phytochemicals	Quantitative analysis (mg/100 g)
Tannins	210.07±0.09
Flavonoids	269.86±0.13
Saponin	5.88±0.1
Alkaloids	68.71±0.20
Phenols	0.00±0.00
Reducing Sugar	24.14±0.16
Anthraquinones	0.00±0.00
Steroids	0.00±0.00

**Table 2.** Biomarkers of kidney function.

Kidney biomarkers	Control	500 mg/kg ACE	100 mg/kg <i>O. gratissimum</i> + 500 mg/kg ACE	200 mg/kg <i>O. gratissimum</i> + 500 mg/kg ACE
Creatinine (umol/l)	0.65±0.11	0.91±0.14*	0.65±0.06	0.64±0.04
Urea (mmol/l)	16.92±5.52	20.18±7.71*	17.25±2.17	16.53±1.75

Each value represents the Mean ± Standard deviation. ACE: Acetaminophen. \*P<0.05 shows a significant difference.

21 days.

#### Histology of the kidney

After sacrificing the animal, the kidneys from the rats were quickly removed using a surgical blade to cut the rat open and fixed in 10% formal saline. Afterwards the tissues were processed into slides.

#### Ethical clearance

This study was obtained from the Research Ethics Committee of the College of Medicine, University of Nigeria, Enugu Campus. The protocol number is: 036/12/2017

#### Statistical analysis

All data were expressed as mean±standard deviation. Statistical package for social science (SPSS) version 20 was used for data analysis. One way analysis of variance (ANOVA) was used to determine the difference between the means of various groups. Value of P <0.05 was considered significant.

## RESULTS

### Phytochemical analysis

The phytochemical analysis showed that *O. gratissimum* contains various phytochemical such as tannins, flavonoids, saponins, etc. Elevation of urea and creatinine levels in the serum is taken as the index of

nephrotoxicity (Partwardhan et al., 2005). Aqueous extract of *O. gratissimum* non-significantly decreased serum creatinine and urea level in a dose-dependent manner. The highest dose showed greater improvement in renal function which was also confirmed by the histological analysis where there was mild healing in the group treated with *O. gratissimum* 100 mg/kg, moderate healing in the groups treated with 200 and 400 mg/kg *O. gratissimum* (Table 1). There was a significant increase (p<0.05) in creatinine level in the negative control group when compared with the normal control group. However, there was non-significant decrease in creatinine level in the treated groups when compared with the negative control. There was a significant increase in urea level in the negative control group when compared with the normal control group. However, there is no significant difference (P>0.05) in urea level in the treated groups when compared with the negative control group (Table 2). Phytochemical are known to perform different biological activities. This ameliorative effect of *O. gratissimum* may be due to the presence of flavonoids which exhibits antioxidant activity (Abdullahi et al., 2012). There was no significant change in the serum electrolytes (Na<sup>+</sup>, K<sup>+</sup>, Cl<sup>-</sup> and HCO<sub>3</sub><sup>-</sup>) which indicates that *O. gratissimum* maintained electrolyte balance (Table 3).

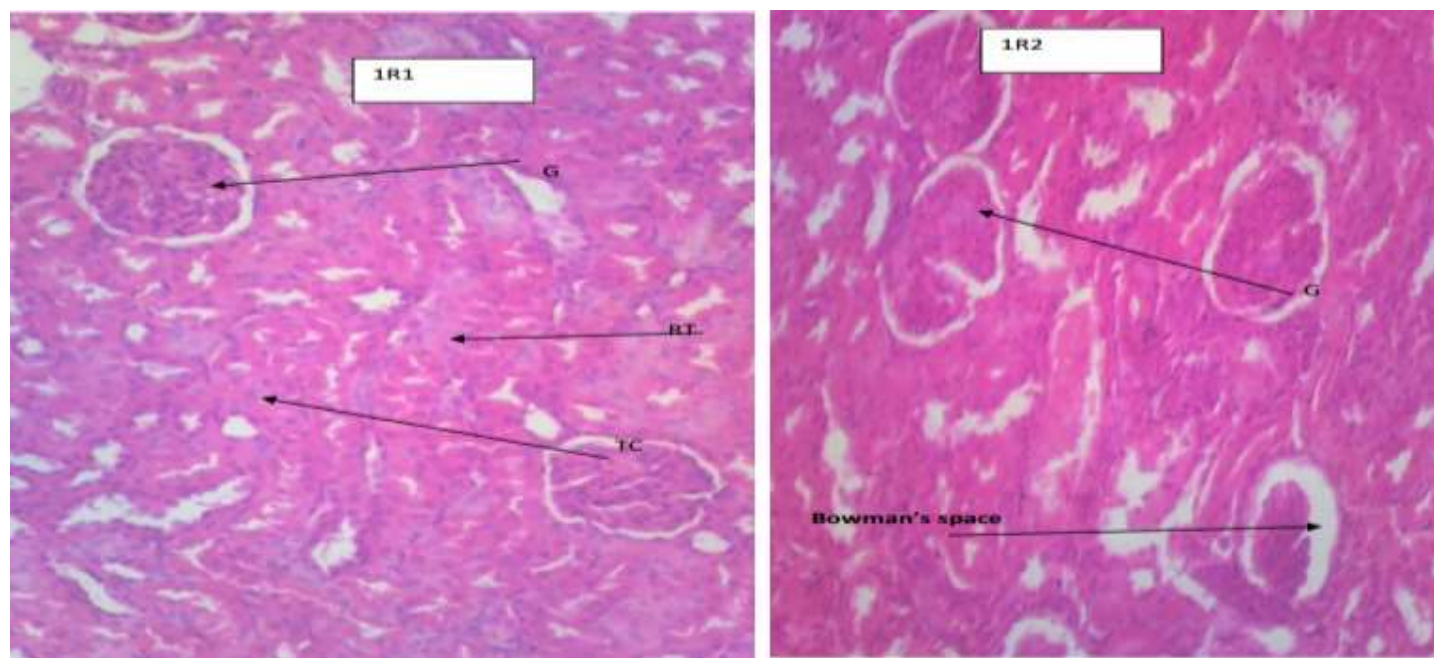
### Histological analysis

However, there are clumping of the renal tubules (CRT) and mild tubular dilation (MTD) and mild fatty changes

**Table 3.** Serum electrolytes.

Serum electrolytes	Control	500 mg/kg ACE	100 mg/kg <i>O. gratissimum</i> + 500 mg/kg ACE	200 mg/kg <i>O. gratissimum</i> + 500 mg/kg ACE
Na <sup>+</sup> (mmol/l)	136.13±2.22	130.53±3.74	134.25±2.05	134.53±1.64
K <sup>+</sup> (mmol/l)	5.76±0.29	5.47±0.64	6.17±0.92	6.17±0.92
Cl <sup>-</sup> (mmol/l)	96.93±1.64	91.58±3.82	93.28±1.13	93.28±1.13
HCO <sub>3</sub> <sup>-</sup> (mmol/l)	32.90±6.38	31.50±1.71	28.23±3.95	28.23±3.95

Values were expressed as Mean± Standard deviation. There was no significant difference ( $P>0.05$ ) in sodium (Na<sup>+</sup>), Potassium (K<sup>+</sup>), Chloride (Cl<sup>-</sup>) and Bicarbonate (HCO<sub>3</sub><sup>-</sup>).



**Figure 1.** Photomicrograph of group 1r1r2 control section of kidney (X400) (H/E) shows normal architecture with glomeruli (G), Bowman space (BS), renal tubules (RT) and tubular cell (TC).

(MFC). The result of histology study confirms an improvement in the histoarchitecture in groups treated with *O. gratissimum* that had moderate regeneration of the glomeruli, moderate regeneration of the tubular cell, mild and moderate healing of renal tissues when compared with the negative control group that had severe coagulative necrosis of glomeruli, tubular cell necrosis and severely damaged renal tissue. The improvement in histology was also dose dependent which may be due to the presence of tannins which protects kidneys from inflammation (Figures 1 to 4) (Just et al., 1998).

## Conclusion

The result of the present study has shown that the aqueous extract of *O. gratissimum* exerted an

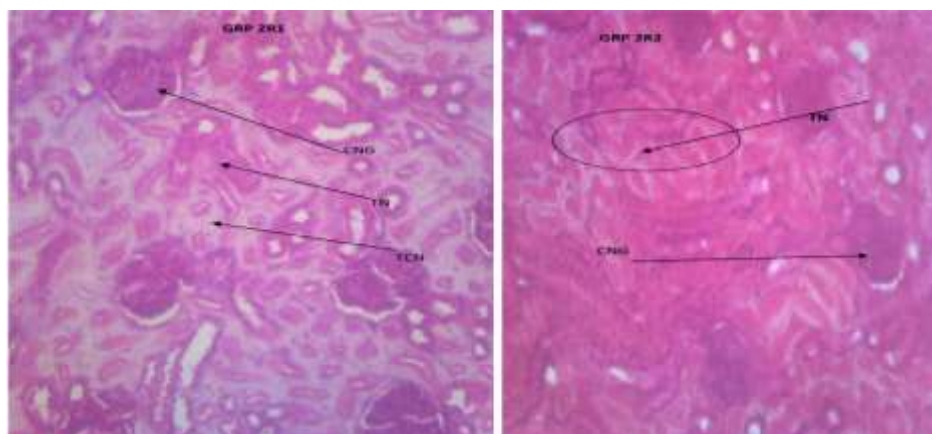
ameliorative effect on acetaminophen induced renal toxicity in a dose dependent manner. Thus consumption of *O. gratissimum* may protect the kidney from injury caused by some toxic agents.

## ACKNOWLEDGEMENT

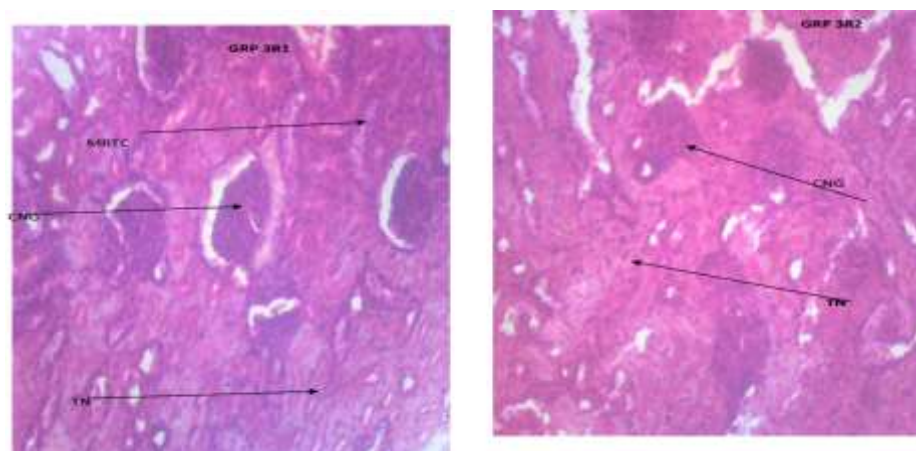
The authors sincerely acknowledged the effort of Prof. Nwachukwu Daniel who initiated and supervised this research work at the Prestigious University of Nigeria, Enugu Campus.

## CONFLICT OF INTERESTS

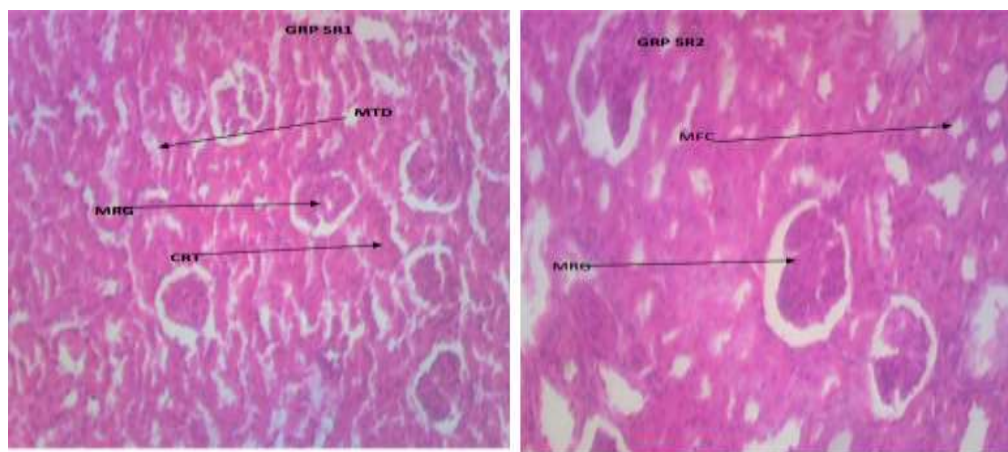
The authors have not declared any conflict of interests.



**Figure 2.** Photomicrograph of 3r1r2 section of kidney administered with 100 mg/kg of *Ocimum gratissimum* 1 h before inducing 500 mg/kg of acetaminophen for 21 days (X400) (H/E) shows mild healing with coagulative necrosis of glomeruli (CNG), tubular necrosis (TN) with moderate regeneration of the tubular cell (MRTC).



**Figure 3.** Photomicrograph of 4r1r2 section of kidney administered with 200 mg/kg of *ocimum gratissimum* 1 h before inducing 500 mg/kg of acetaminophen for 21 days (X400) (H/E) shows moderate healing with moderate regeneration of the glomeruli (MRG) and the renal tubules (RT). However there are fatty changes (MFC) and tubular cell necrosis (TCN)



**Figure 4.** Photomicrograph of group 5r1r2 section of kidney administered with 400mg/kg of *Ocimum gratissimum* 1 h before inducing 500 mg/kg of acetaminophen for 21 days (X400) (H/E) shows moderate healing with moderate regeneration of the glomeruli (MRG) and the renal tubules (RT).

## REFERENCES

- Abdullahi M (2012). Phytochemical constituents and antimicrobial and grain protectant activities of cloves basil (*ocimum gratissimum L.*) grown in Nigeria. *International Journal of Plant Research* 2(1):18
- Adebolu TT, Salau AO (2005). Antimicrobial activity of leaf extracts of *ocimum gratissimum* on selected diarrhea causing bacteria in south western Nigeria. *African Journal of Biotechnology* 4(7):682-684.
- Arhgooro EM, Anosike EO, Uwakwe AA (2012). *Ocimum gratissimum* aqueous extract enhances recovery in cisplatin-induced nephrotoxicity in albino Wistar rats. *Indian Journal of Drugs and Diseases* 1(5):129-142.
- Egesie UG, Adelaiye AB, Ibu JO, Egesie OJ (2006). Safety and hypoglycemic properties of aqueous leaf extract of *Ocimum gratissimum* in STZ-induced diabetic animals". *Nigerian Journal of Physiological Science* 21(1-2):31-35.
- Ephrain KD, Salami HA, Osewa TS (2000). Effect of aqueous extract of *Ocimum gratissimum* on biochemical parameters in rabbits. *African Journal Biomedical Research* 3(3):175-179.
- Gbolade A (2009). Inventory of antidiabetic plants in selected districts of Lagos state, Nigeria. *Journal of Ethnopharmacology* 121(1):135-139.
- Ighodalo OM, Agubiade JO, Kuti OA (2012). Evaluation of the chemical, nutritional, antimicrobial and antioxidant-vitamin profiles of *Ptilostigma thonningii* leaves (Nigeria species). *Research Journal of Medicinal Plants* 6 (7):537-543.
- Ijeh II, Njoku OU, Ekenze EC (2004). Medicinal evaluation of *xylopiia ethiopica* and *Occimum gratissimum*". *Journal of Medicinal and Aromatic Plant Science*, 26 (5):19-21.
- Just MJ, Recio MC, Giner RM, Cueller MV, Manez, S, Billa AR, Rios JI (1998). Anti Inflammatory activity of unusual lupine saponins from *Bupleurum fruticosens*. *Planta Medica* 64(05):404-407.
- Kang SK, Kim W, Oh MS (2002). Pathogenesis and treatment of hypernatremia. *Nephron* 92:14-17.
- Kumar VI, Padhy BM (2011). Protective effect of aqueous suspension of dried latex of *Calotropisprocera* against oxidative stress and renal damage in diabetic rats. *Biocell* 35(3):63-69.
- Nirmala M, Giriya K, Lakshman K, Divya T (2012). Hepatoprotective activity of *Musa paradisiaca* on experimental animal models. *African Pacific Journal of Biomedicine* 2(1):11-15.
- Nisha R, Srinivasa KSR, Thanga MK, Jagatha P (2017). Biochemical evaluation of creatinine and urea in patients with renal failure undergoing hemodialysis. *Journal of Clinical Pathology and Laboratory Medicine* 1(2):1-5.
- Nwangwu SCO, Josiah SJ, Offor CE, Ekhyame EC (2015). Evaluation of the effects of aqueous extracts of *Ocimum gratissimum* on some kidney function parameters in normal male rats. *Global Journal of Pharmacology* 9(1):72-76.
- Oboh G (2008). Antioxidant Potential of *ocimum gratissimum* and *Ocimum canum* leaf polyphenols and protective effects on some pro-oxidants induced lipid peroxidation in rat brain. An *in vitro* study. *Anal Journal of Food Technology* 3(5):325-334.
- Ofokansi KC, Adikwu MU, Esimone CO, Nwodo NM (2003). Antibacterial activity of the leaf extract of *Ocimum gratissimum* (famlabiatae). *Journal of Biological Research and Biotechnology* 9(1):35-37.
- Ogundipe DJ, Akomolafe RO, Sanusi AA, Imafidon CE, Olukiran OS, Oladele AA (2017). *Ocimum gratissimum* Ameliorates gentamicin-induced kidney injury but decreases creatinine clearance following sub-chronic administration in rats. *Journal of Evidence Based Complementary Alternative Medicine* 22(4):592-602.
- Ojo OA, Oloyede OI, Olanrewaju OI, Ojo AB, Ajiboye BO, Onikanni SA (2013). Toxicity studies of the crude aqueous leaves extracts of *Ocimum gratissimum* in albino rats. *IOSR Journal of Environmental Science, Toxicology and Food Technology* 6:434-439.
- Okigbo EN (1977). Neglected plants of horticultural and nutritional importance in traditional farming systems of tropical Africa. *Acta Horticulture* 53:31-150.
- Partwardhan B, Warude D, Pushpangadan P, Bhatt N (2005). Ayurveda and traditional Chinese medicine: A comparative overview. *Evidence Based Complementary and Alternative Medicine* 2(4):465-473.
- Smith CL, Hampton EM (1990). Using estimated creatinine clearance for individualizing drug therapy: A reassessment DICP pp. 1185-1190.
- Sofowora A (2008). Medicinal plants and traditional medicine in Africa. 3<sup>rd</sup> Edn. Spectrum Books Limited Ibadan, Nigeria pp. 199-204
- Sofowora A (2008). Medicinal plants and traditional medicine in Africa. 2<sup>nd</sup> Edn Spectrum Books Ltd Ibadan Nigeria ISBN-13:9789782462190, P 289.