

Full Length Research Paper

Liver damage in an experimental model of peripheral neuropathy induced by *Karwinskia humboldtiana* (Buckthorn) fruit: Histopathological evidence

Rubén García-Garza¹, Martha E. Salazar-Leal², Viktor J. Romero-Díaz³, Jaime García-Juárez³, Carlos Leyva-Orasma⁴, Javier Morán-Martínez⁵, Odila Saucedo-Cárdenas^{3,6} and Adolfo Soto-Domínguez^{3*}

¹Departamento de Histología, Facultad de Medicina, Universidad Autónoma de Coahuila, Unidad Torreón. Av. Gregorio A. García 198 Sur, Torreón, Coah. México. C.P. 27000.

²Departamento de Farmacología y Toxicología. Facultad de Medicina. Universidad Autónoma de Nuevo León. Monterrey Nuevo León. A.P. 1583. México.

³Departamento de Histología. Facultad de Medicina. Universidad Autónoma de Nuevo León. Monterrey Nuevo León. A.P. 1583. México.

⁴Universidad Autónoma Agraria Antonio Narro, Periférico Raúl López Sánchez y Carretera a Santa Fé, C.P 27054, Torreón, Coah, México.

⁵Departamento de Biología Celular y Ultraestructura, Centro de Investigación Biomédica, Universidad Autónoma de Coahuila, Unidad Torreón. Av. Gregorio A. García 198 Sur, Torreón, Coah. México. C.P. 27000.

⁶Centro de Investigación Biomédica del Noreste (CIBIN), IMSS, San Luis y 2 de Abril. Col. Independencia. Monterrey, N.L. México. C.P. 64720.

Received 2 February, 2016; Accepted 19 April, 2016

***Karwinskia humboldtiana* (Kh) is a poisonous shrub that causes acute or chronic intoxication in animals and humans. In chronic intoxication, the main sign is the presence of paralysis. Previously we reported a model of intoxication with Kh fruit that reproduces paralysis and clinical phases in humans when they do not die; however, there are no studies that describe damage to liver in this model. The objective was to evaluate histopathological alterations in liver during chronic intoxication. Wistar rats (n=25) were divided into five groups (n= 5). Four groups were intoxicated with Kh and one received only water as a control group. Animals were euthanized at different times during paralysis evolution. Samples of liver were obtained, and processed either for light or electron microscopy evaluation. Histological, histochemistry and immunohistochemistry analyses were performed, including a morphometric analysis. Results demonstrated necrotic areas, vascular congestion and vacuoles in the cytoplasm of hepatic cells that increased during intoxication and decreased in the recovery stage. These findings were confirmed at electron microscopy level. Morphometric analysis demonstrated statistically significant difference in occurrence of necrotic cells and PCNA positive cells between control and intoxicated groups. This was not observed with TUNEL staining. These findings demonstrate that during Kh intoxication there is a severe damage in liver that is reversible. Thus, it could be suggested that Kh causes a systemic intoxication not only damage to peripheral nervous system.**

Key words: *Karwinskia humboldtiana*, plant intoxication, liver damage.

INTRODUCTION

Karwinskia humboldtiana (*Kh*) also known as tullidora, capulín tullidor or coyotillo, is a poisonous shrub from the *Rhamnaceae* family. It is distributed throughout the Mexican Republic, South America, Central America and Northern of Colombia (Fernández, 1992). Dreyer et al. (1975) isolated from the endocarp of *Kh* four dimeric anthracenonic compounds named as T-496, T-514, T-516 and T 544, according to their molecular weights, which have been demonstrated to be responsible for the toxicity of this plant (Dreyer et al., 1975; Waksman et al., 1989; Rivas et al., 1990; Bermúdez et al., 1992; Waksman and Ramirez, 1992).

In the literature, there are numerous reports of accidental human intoxications with *Kh* fruit (Castillo et al., 1920; Segovia et al., 1972; Bustamante et al., 1978; Puértolas et al., 1984; Arellano et al., 1994; Bermudez et al., 1995; Ocampo et al., 2007). Clinical sign of this intoxication varies according to the amount of fruit ingested. In acute intoxication, respiratory failure and death may occur within 2 to 3 days without paralysis signs. If it is consumed in small quantities or chronic intoxication, after a few weeks of consumption, a clinically flaccid, symmetrical, ascending and progressive paralysis appears which can lead to death (Segovia et al., 1972); or in some cases human can recover slowly from the paralysis (Arellano et al., 1994).

Acute intoxication of Wistar rats with *Kh* fruit has shown liver disorders and clotting characterized by an increase in aspartate transaminase (AST) and alanine transaminase (ALT), as well as a decrease in II, V, VII and X coagulation factors (Jaramillo et al., 2009). Only there are two *in vitro* studies in hepatocytes of rat treated with *Kh* fruit (Wheeler et al., 1971), or with T-514 (Garza-Ocañas et al., 2003) that reported mitochondrial alterations and increase of toxic oxygen radicals. *In vivo* experimental studies of acute toxicity with purified toxin T-514 administered to different species have reported atelectasis and emphysema, along with infiltration of polymorphonuclear cells in alveolar septa, rupture of capillaries and bleeding (Bermúdez et al., 1986; Sepúlveda et al., 1992). In liver, congestion and massive necrosis were reported, especially with T-514 (Bermudez et al., 1986).

Salazar et al. (2006) reported a model of chronic intoxication with *Kh*, by the administration of fractionated doses of mature fruit of this plant to Wistar rat. This model reproduces the clinical phases of paresis, paralysis, and recovery that are presented in intoxicated humans when they do not die (Salazar et al., 2006). Recently, we demonstrated a toxic effect of *Kh* fruit on striatum of Wistar rat using this same intoxication model (Díaz-Pérez et al., 2016). Since there have not been

found any studies that describe damage to organs like the liver in this model, the objective was to evaluate histopathological alterations in this organ during chronic intoxication with the fruit of *Kh*.

MATERIALS AND METHODS

Study groups and administration of Kh fruit

Wistar rats (n=25) were used, and all animals were divided into five groups (n = 5). Four groups were intoxicated with fruit of *Kh* according to the intoxication model described by Salazar et al. (2006), and one only received water as control animals; all the animals were kept under standard laboratory conditions. Experiments were carried out according to the International Guidelines on the Appropriate use of Experimental Animals, and according to Mexican Norm NOM-062-ZOO-1999 on the Technical Specifications for Production, Care and Use of Laboratory Animals (SAGARPA, 1999). The protocol was approved by the Bioethical Committee of the Faculty of Medicine UANL in Monterrey, Nuevo León, México.

After a period of 6 h of fasting, rats to intoxicate received a fractionated dose of dry, ground, and sieved fruit of *Kh* that was dissolved in water and orally administered through an orogastric tube. The first dose was of 1.5 g/kg (Day 0) followed by four subsequent doses of 0.5 g/kg at days 3, 7, 10 and 14 after the first dose (total dose of 3.5 g/kg). Control rats received only water and all rats were clinically evaluated during the experimental study time according to intoxication model described by Salazar et al., (2006). Weight was determined daily during the first two weeks, every third day from third to eighth week, and weekly from eighth week until the end of the study at day 112 post-intoxication. The clinical evaluation included the appearance of piloerection, spontaneous mobility, muscle tone, gait abnormalities, respiratory rate, weight loss, limb weakness and paralysis.

Sample collection

Animals of all study groups were sacrificed by cervical dislocation at the corresponding days after the intoxication as follows: First group was sacrificed at day 24 post-intoxication before the rats presented paresis (group without paresis). Second group was sacrificed at day 48 post-intoxication when rats had paresis (paresis group). Third group corresponded to intoxicated rats showing paralysis at day 58 (paralysis group), and finally the recovery group corresponded to the intoxicated rats that showed clinical recovery from paralysis and were sacrificed at day 112 post-intoxication.

Histopathological analysis

Liver samples were obtained, fixed by immersion in formalin 10 % in PBS (Phosphate Buffer Saline) 1X, pH 7.2-7.4 and processed by routine histological technique until inclusion of samples in paraffin blocks. Histopathological evaluation was performed on sections of 5-7 µm thickness. Sections were stained with hematoxylin and eosin (H&E) for histopathological evaluation, Masson's trichrome to detect connective tissue, and silver impregnation to identify reticular fibers (collagen type III). This was performed as follows 5 µm

*Corresponding author. E-mail: ibqasoto@yahoo.com.mx. Fax: 52-82-8348-5477.

paraffin sections were hydrated and then oxidized with 1% potassium permanganate. They were rinsed well with tap water, bleached in 5% oxalic acid for a 1 min and sensitized with 1% uranium nitrate solution for 5-10 s. Later, they were rinsed with distilled water, treated with Bielchowsky's ammoniacal silver for 1 min (48 mL of 2% silver nitrate) and 0.4 mL of 40% sodium hydroxide was added. While swirling, slowly drops of strong ammonium hydroxide were added until the precipitate dissolved. They were put in 100 mL of distilled water and then rinsed briefly with 90% ethanol. They were placed in the developer (5 ml of 37% formalin, 0.15 g uranium nitrate and 1L of distilled water) for 1 min and rinsed well with tap water and distilled water. Then, they were toned with 0.2% gold chloride solution and rinsed with distilled water. Also, they were fixed in 5% sodium thiosulphate for 1 min and washed well with running tap water. They were counterstained with eosin for 1 min and rinsed with tap water. Finally, they were dehydrated with ethanol, cleared with xylene and mounted onto a resinous medium.

Histochemistry

A portion of formalin-fixed tissue was processed for frozen section technique. Histological sections of 6-8 μm thickness were obtained, and stained with Oil Red technique for the histochemistry identification of lipids droplets deposits.

Immunohistochemical evaluation

To distinguish between morphological necrotic alterations induced by *Kh* intoxication from apoptotic hepatocytes, the TUNEL (TdT-mediated dUTP-biotin Nick-End Labeling) test was performed on 6-8 μm thick sections to detect fragmentation of nuclear DNA, a hallmark of apoptosis (Gavrieli et al., 1992) using the kit TACS™ 2 TdT *In situ* Apoptosis Detection of Trevigen® (Gaithersburg, MD, USA), according to the instructions of the manufacturer. Nuclei were contrasted with methyl green.

Furthermore, to determine whether *Kh* intoxication inhibits proliferation of liver cells, histological sections (4-5 μm thick) were incubated with anti-PCNA (Proliferating Cell Nuclear Antigen) monoclonal antibody (1: 200) to identify proliferating cells (Matsumoto et al., 1987; Zhang et al., 1999) using the Envision® detection system and 3, 3'-diaminobenzidine (DAB). PCNA antibody and the detection system were purchased from Dako Cytomation, Inc® (Carpinteria, Ca. USA). Nuclei were contrasted with Mayer's hematoxylin. As a negative control, the monoclonal antibody was omitted. The samples were analyzed by light microscope.

Morphometric analysis

To quantify necrotic hepatocytes, the liver parenchyma was divided in hepatic acini or liver Rappaport acini. Hepatic acini (zones 1, 2 and 3) or Rappaport's hepatic acinus represents a liver lobule that is divided into 3 regions based on their proximity to the distributing veins: zone I has cells closest to the vessels (portal triad) and first to be affected by incoming blood with toxins, zone II with cells which are second to respond to toxic compounds in blood (in between portal triad and central vein), and zone III with cells near the central vein. Quantization was performed in 24 random fields per group (eight fields/slide, one slide/rat, three rats/group) were chosen from sections stained with H&E and observed with the oil immersion objective (100X). In these fields the normal and necrotic hepatocytes in the 3 zones described for the hepatic acini were quantified.

This methodology was also applied to quantify positive cells to TUNEL test and to PCNA antibody. Digital high-resolution

images were obtained with a Nikon Microscope Eclipse 50i, and with the image analysis system Digital Sight dDS-2Mu. Averages and standard deviations (SD) were calculated, and a student's t-test was performed with the statistics software SPSS program v.16 to compare the control vs experimental groups, a value of $p \leq 0.05$ was considered as statistically significant.

Ultrastructure

Simultaneously, other portion of liver was fixed by immersion in solution of Karnovsky-Ito (4% paraformaldehyde, 5% glutaraldehyde, and 0.05% picric acid in 0.1 M PBS pH 7.2-7.4) (Ito and Karnovsky; 1968). Samples were post fixed in 2% aqueous osmium tetroxide, and processed by conventional technique for transmission electron microscopy until their inclusion in epoxy resins to form blocks. Semithin and ultrathin sections were obtained by ultramicrotomy; semithin sections were stained with 1% toluidine blue and analyzed by light microscopy. Ultrathin sections were mounted on copper grids 200 mesh without support medium, and contrasted with 5% uranyl acetate followed by 0.04% lead citrate; samples were analyzed with a Zeiss EM 109 transmission electron microscope.

RESULTS

Clinical manifestations

Clinical manifestations, such as weight loss, ocular secretion, hair bristling, weakness, and respiratory difficulty, were analyzed in rats intoxicated with *Kh* fruit. These manifestations were present in the paresis group at 48 days, were more evident at 58 days in the paralysis group, and almost all of the symptoms resolved in the recovery group, which only presented piloerection (Table 1).

Histopathological evaluation

In the control samples hepatocytes, portal triads, central venous and sinusoids with normal histological features were observed (Figure 1A). In groups without paresis and with paresis, vascular congestion and small cytoplasmic vacuoles in most hepatocytes were observed (Figure 1B and 1C). In these groups we also observed areas of necrotic hepatocytes characterized by hyperchromatic nucleus and extracted cytoplasm. In the paralysis group, generalized vascular congestion, large cytoplasmic vacuoles in most hepatocytes (Figure 1D), as well as larger amount of necrotic areas of hepatic cells were observed. Finally, in recovery group, most of the alterations described above were absent; only vascular congestion was observed (Figure 1E).

With the method of Masson's trichrome, in all groups few blue collagen fibers were observed around the central veins, and portal triads with normal characteristics (Figure 2A-2E). Signs of fibrosis were not observed. Also, in control and intoxicated groups, with the silver impregnation it was possible to identify thin reticular fibers without differences among all groups (Figure 3A-

Table 1.

Clinical manifestations	Without Paresis (24 days)	Paresis (48 days)	Paralysis (58 days)	Recovery (112 days)	Related organ	Histopathological findings
Weight loss	+	+	++	-	Liver (Present Study)	Steatosis, necrosis of hepatic cells.
Respiratory difficult	+	++	+++	+	Lung (García- Garza et al., 2013)	Fibrosis in interalveolar septum, presence of mast cells.
Ocular secretion	+	+	++	-	Peripheral nerve (Salazar et al., 2006, García- Garza et al., 2013)	Segmental demyelination in some fibers, swelling and myelin sheath vacuolization. Axonal alterations such as alternating thinned and thickened zones.
Hair bristling	+	+	++	-	Peripheral nerve (Salazar et al., 2006, García- Garza et al., 2013)	Segmental demyelination in some fibers, swelling and myelin sheath vacuolization. Axonal alterations such as alternating thinned and thickened zones.
Weakness	+	+	+++	-	Peripheral nerve (Salazar et al., 2006, García- Garza et al., 2013) Brain (Díaz-Pérez et al., 2016)	Segmental demyelination in some fibers, swelling and myelin sheath vacuolization. Axonal alterations such as alternating thinned and thickened zones. Neuronal damage.
Decreased spontaneous activity	+	+	++	-	Peripheral nerve (Salazar et al., 2006, García- Garza et al., 2013) Brain (Díaz-Pérez et al., 2016)	Segmental demyelination in some fibers, swelling and myelin sheath vacuolization. Axonal alterations such as alternating thinned and thickened zones. Neuronal damage.
Alopecia of eyebrows	+	+	++	-	Peripheral nerve (Salazar et al., 2006, García- Garza et al., 2013)	Segmental demyelination in some fibers, swelling and myelin sheath vacuolization. Axonal alterations such as alternating thinned and thickened zones.
Alopecia of dorsal region	+	+	++	-	Peripheral nerve (Salazar et al., 2006, García- Garza et al., 2013)	Segmental demyelination in some fibers, swelling and myelin sheath vacuolization. Axonal alterations such as alternating thinned and thickened zones.
Walk alterations	-	+	++	-	Peripheral nerve (Salazar et al., 2006, García- Garza et al., 2013) Brain (Díaz-Pérez et al., 2016)	Segmental demyelination in some fibers, swelling and myelin sheath vacuolization. Axonal alterations such as alternating thinned and thickened zones. Neuronal damage.
Muscular atrophy	-	+	++	-	Peripheral nerve (Salazar et al., 2006, García- Garza et al., 2013)	Segmental demyelination in some fibers, swelling and myelin sheath vacuolization. Axonal alterations such as alternating thinned and thickened zones.

Table 1 cont'd

General sickness	-	+	++	-	Liver (Present Study) Lung (García- Garza et al., 2013a) Kidney (García Garza et al., 2013b)	Fibrosis in interalveolar septum, presence of mast cells, steatosis, necrosis in uriniferous tubules, damage to filtration slits.
Spinal deformity	-	+	++	-	Peripheral nerve (Salazar et al., 2006, García- Garza et al., 2013) Brain (Díaz-Pérez et al., 2016)	Segmental demyelination in some fibers, swelling and myelin sheath vacuolization. Axonal alterations such as alternating thinned and thickened zones. Neuronal damage.
Claw hand	-	-	+	-	Peripheral nerve (Salazar et al., 2006, García- Garza et al., 2013)	Segmental demyelination in some fibers, swelling and myelin sheath vacuolization. Axonal alterations such as alternating thinned and thickened zones.
Paralysis	-	-	+	-	Peripheral nerve (Salazar et al., 2006, García- Garza et al., 2013) Brain (Díaz-Pérez et al., 2016)	Segmental demyelination in some fibers, swelling and myelin sheath vacuolization. Axonal alterations such as alternating thinned and thickened zones. Neuronal damage.
Polineuropathy disappears	-	-	-	+	Peripheral nerve (Salazar et al., 2006, García- Garza et al., 2013)	Remyelination of peripheral nerve.
Improvement of the general condition	-	-	-	+	Liver (Present study) Peripheral nerve (Salazar et al., 2006)	Liver recovery , remyelination of peripheral nerves.

-: Absent, +: Mild, ++ : Severe

3E).

Histochemistry evaluation

In the control samples, lipids were not present in the cytoplasm of hepatocytes demonstrated with oil red (Figure 4A). Groups without paresis and with paresis showed a diffuse positivity to this reaction in the cytoplasm in extended areas of

hepatocytes (Figure 4B and 4C); deposits of lipids were more evident in the samples of paralysis group (Figure 4D). In recovery group little lipids droplets remained in the cytoplasm of hepatocytes (Figure 4E).

Immunohistochemical evaluation

By the TUNEL assay, few positive cells to

chromatin fragmentation were observed in control group and experimental groups (Figure 5A-5E). By immunohistochemical analysis of PCNA, the highest number of proliferating cells was observed in control group (Figure 6A); followed by groups without paresis (Figure 6B) and with paresis (Figure 6C). It is noteworthy that group with paralysis showed fewer positive cells (Figure 6D), recovery group showed higher number of positive cells compared with the other treated group

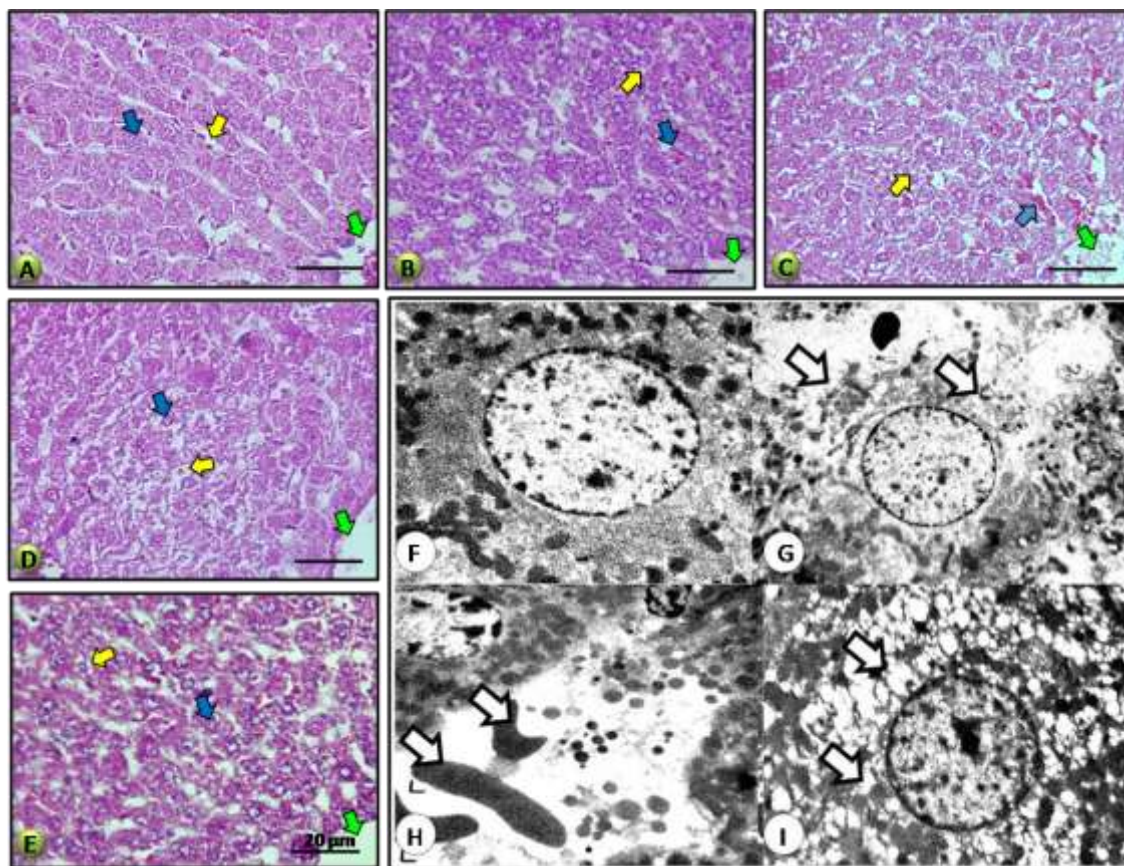


Figure 1. *Kh* induces necrotic alterations in hepatocytes in intoxicated groups: A) Control group with normal histology: nuclei (blue arrow), sinusoids (yellow arrow), central vein (green arrow). B-D) Groups without paresis, paresis and paralysis, respectively, showing vascular congestion (blue arrow), increasing cytoplasmic vacuoles and necrotic alterations in hepatocytes (yellow arrow), central vein (green arrow). E) Recovery group shows most of hepatocytes with normal appearance, only small cytoplasmic vacuoles remained (yellow arrow). H&E. Bar: 20 μ m. *Hepatic ultrastructural alterations induced by Kh* fruit: F) Hepatocyte of control group with normal ultrastructural appearance. In intoxicated groups following alterations were observed: G) hepatic necrosis with loss of continuity of the cell membrane and cytoplasmic extraction (arrow), H) vascular congestion in the sinusoidal lumen (arrow), I) vacuolization of the cytoplasm of hepatocytes (arrows). Inclusion in epoxy resins. Transmission electron microscope, F: 7000x, G-I: 4400x.

(Figure 6E).

Morphometric analysis

In the morphometric analysis of liver acini (zones 1, 2 and 3), control group showed only a few hepatocytes damaged per field of view ($2,583 \pm 1,127$; $2,850 \pm 0,476$ and $1,800 \pm 0,519$). In the group without paresis, more altered hepatocytes were observed ($19,900 \pm 2,351$; $23,600 \pm 5,567$ and $17,183 \pm 2,133$). In paresis group, increased damaged hepatocytes ($29,933 \pm 4,623$; $34,667 \pm 1,607$ and $34,833 \pm 1,985$). However, paralysis group presented the highest number of necrotic damage ($50,333 \pm 4,523$; $61,867 \pm 2,400$ and $61,167 \pm 2,478$), recovery group showed $8,233 \pm 2,315$; $8,833 \pm 2,182$ and $9,633 \pm 0,416$. Statistical analysis revealed a significant

difference in intoxicated group compared with control group (Figure 7A).

The number of positive nuclei in TUNEL analysis in the control group was 2.978 ± 1.321 , while in the groups intoxicated with *Kh* the results are as follows: group without paresis (4.159 ± 0.888), paresis group (4.344 ± 0.432), paralysis group (5.122 ± 0.992) and recovery (3.233 ± 1.523), respectively. When comparing the results of control vs treated groups no significant difference was found for a value of $p \leq 0.05$ (Figure 7B).

In proliferation analysis (the number of PCNA positive cells) in control and treated groups, it was observed that control group showed the highest number of positive cells: $26,110 \pm 0,639$, group without paresis had 22.185 ± 1.054 , then paresis group with an average of 18.245 ± 0.732 . Group with paralysis showed the lowest amount of positive cells with an average of 12.503 ± 0.521 , and

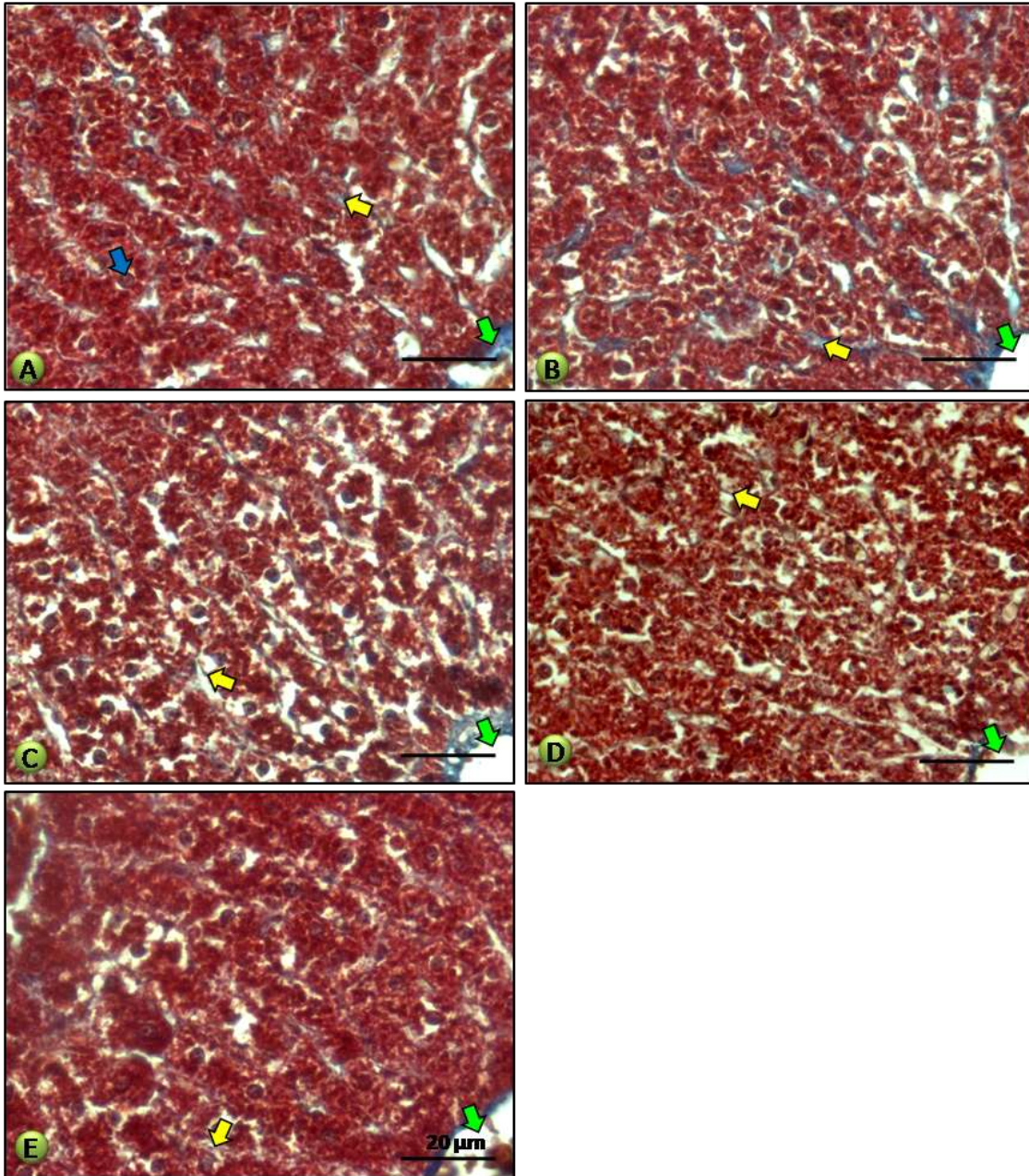


Figure 2. *Kh* does not causes fibrosis :A) Control group with normal histology: nuclei (blue arrow), collagen fibers (yellow arrow), central vein (green arrow). B-E) intoxicated groups showing collagen fibers similar to control group, collagen fibers (yellow arrow), central vein (green arrow). Masson's trichrome. Bar: 20 µm.

finally recovery group showed an amount of $19.024 \pm 3,792$. All treated groups intoxicated with *Kh* were significantly different from the control group ($p \leq 0.05$; Figure 7C).

Ultrastructural evaluation

In control samples hepatocytes were observed with the

cell membrane, nucleus and organelles with normal ultrastructural features (Figure 1F). In groups without paresis and with paresis, necrotic hepatocytes with loss of the continuity of the cell membrane and cytoplasmic extraction (Figure 1G) were observed, as well as sinusoids with vascular congestion (Figure 1H). In these same groups other hepatocytes were observed with small spaces in the cytoplasm corresponding to extracted lipids (Figure 1I). In paralysis group these alterations increased

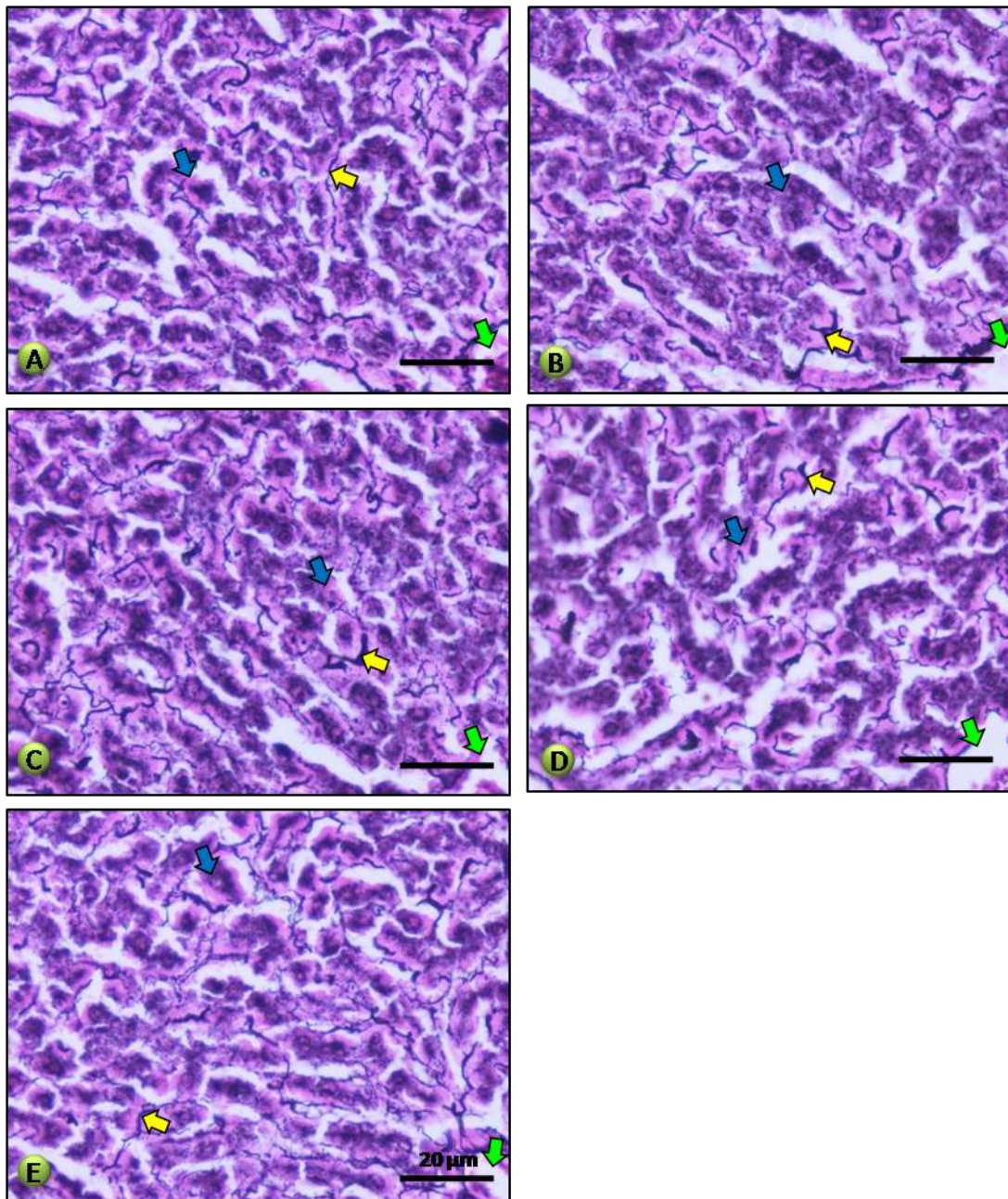


Figure 3. *Kh* does not increase reticular fibers: A-E) Control and experimental groups show normal reticular fibers, fibers (yellow arrow), contrast stain (blue arrow), central vein (green arrow). Wilder's reticulin stain. Paraffin embedded, light microscopy. Bar: 20 µm.

with extended areas of necrotic hepatocytes and hepatocytes with large cytoplasmic vacuoles. In the samples of recovery group only vascular congestion and few and small cytoplasmic vacuoles were observed.

DISCUSSION

Since numerous reports of accidental intoxication in

humans (Arellano et al., 1994; Bermúdez et al., 1995; Ocampo et al., 2007) or experimental intoxication in animals with *Kh* fruit (Escobar and Nieto, 1965; Charlton and Pierce, 1970; Muñoz and Chávez, 1979; Muñoz et al., 1983; Bermúdez et al., 1986; Bermúdez et al., 1992; Salazar et al., 2006, García-Juárez et al., 2012) were focused on the alterations of peripheral nerve, it was considered for a long time that *Kh* affects exclusively peripheral nerve system (PNS). However, this study is

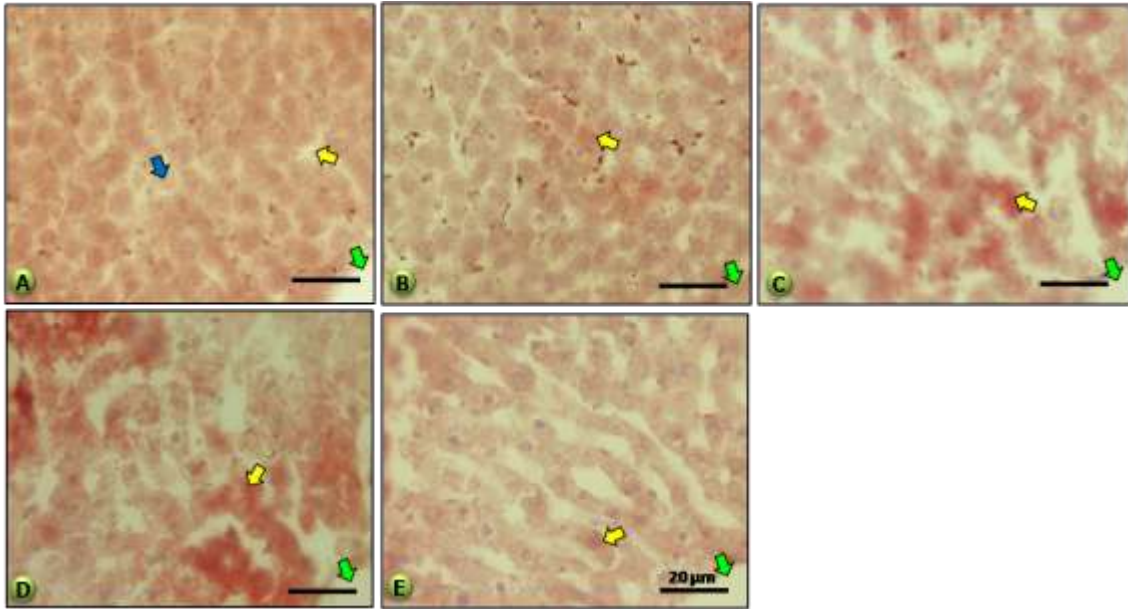


Figure 4. *Kh* induces steatosis in intoxicated groups: A) Control group with absence of lipids in the cytoplasm of hepatocytes (blue arrow), sinusoids (yellow arrow), central vein (green arrow). B-D) Groups without paresis, paresis and paralysis, respectively, showing increasing amount of lipids (yellow arrows), central vein (green arrows). E) Recovery group shows scarce lipids remaining (yellow arrow). Oil red histochemistry. Bar: 20 μ m.

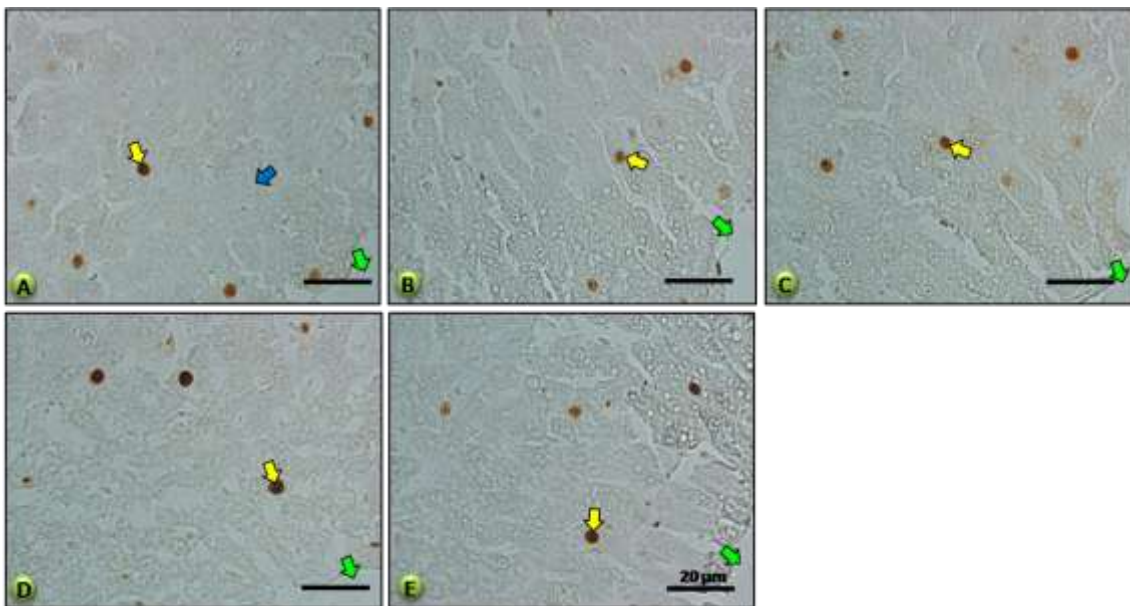


Figure 5. *Kh* does not induce apoptosis in chronic intoxicated rats: A-E) Control group and experimental groups showing scarce cells positive for chromatin fragmentation, positive nuclei (yellow arrow), negative nuclei (blue arrow), central vein (green arrow). TUNEL staining. Bar: 20 μ m.

the first to describe the histopathological alterations in the liver caused by *Kh* fruit in an experimental model of peripheral neuropathy. These alterations began at 24 days post-intoxication and increased at 48 and 58 days

post-intoxication, but at 112 days post-intoxication some alterations disappeared, demonstrating a possible recovery of liver. Previously we have described histopathological alterations in cerebral motor cortex,

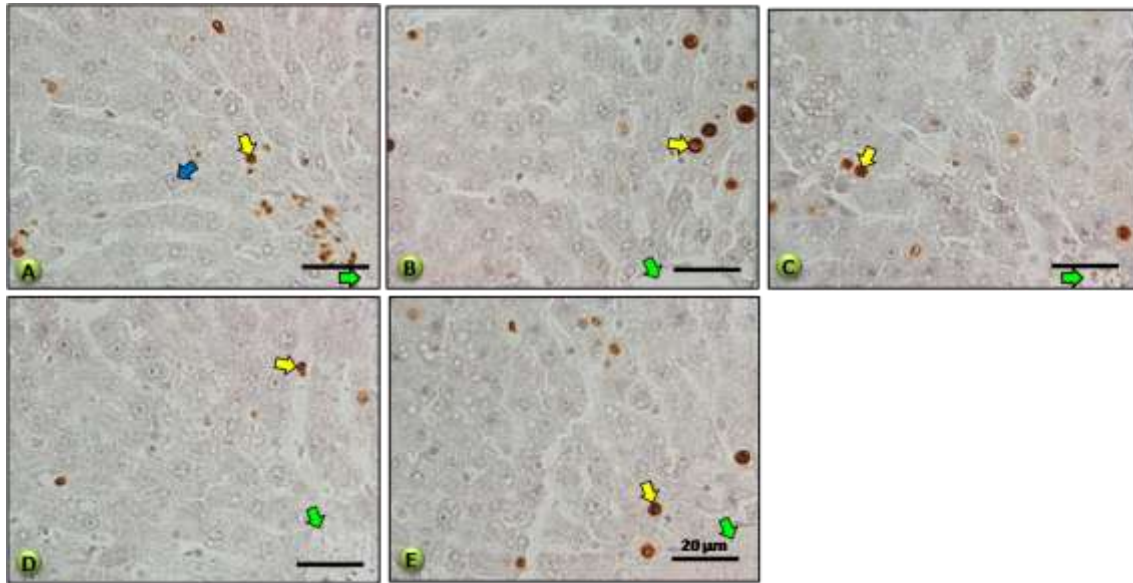


Figure 6. *Kh* induces an antiproliferative effect: A) Control group with numerous proliferation positive nuclei (yellow arrow), negative nuclei (blue arrow), central vein (green arrow). B-E) Intoxicated groups showing decreasing positive nuclei and an increase in the recovery group, central vein (green arrow). PCNA immunohistochemistry. Paraffin embedded, light microscopy. Bar: 20 µm.

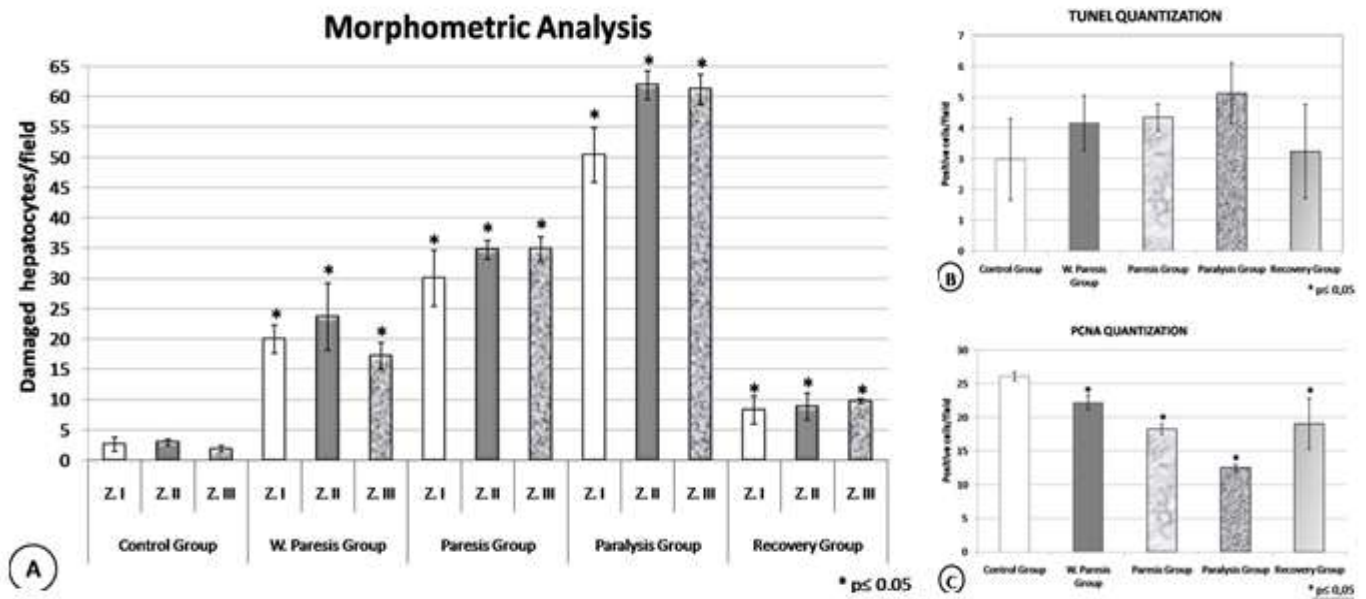


Figure 7. Morphometric analysis. A) number of damaged hepatocytes, showing increasing damage in liver cells in intoxicated groups and a decrease in recovery group. Intoxicated groups show statistically significant difference compared with control group. * $p \leq 0,05$. B) Number of positive nuclei to chromatin fragmentation with TUNEL method, no statistically significant difference was observed between control and intoxicated groups. * $p \leq 0,05$. C) Number of proliferating nuclei measured by PCNA immunohistochemistry, showing decreasing positive cells in intoxicated groups and an increase in recovery group. Intoxicated groups showed statistically significant difference compared with control group. * $p \leq 0,05$.

cerebellum, spinal cord, vestibular nucleus, and corticopontocerebellar tract (Becerra-Verdín et al., 2009)

and recently in striatum (Díaz-Pérez et al., 2016); as well as severe damage in kidney and lung (García et al., 2013)

a, b). Furthermore, the present investigation also contributes to the fact that accidental intoxication with *Kh* in humans and experimentally in animals causes a systemic damage in addition to the damage of PNS in this experimental model (Salazar et al., 2006).

Clinical manifestations, such as weight loss, ocular secretion, hair bristling, weakness, and respiratory difficulty, were analyzed in the rats intoxicated with *Kh* fruit. These manifestations were present in the paresis group at 48 days, were more evident at 58 days in the paralysis group, and almost all of the symptoms resolved in the recovery group, which only presented piloerection. These results agree with other studies regarding the clinical signs in humans and animals intoxicated with *Kh* fruit (Padron-Puyou, 1951; Padrón and Velázquez, 1956; Bermúdez et al., 1986; Salazar et al., 2006, García-Juárez et al., 2012).

In this study, we observed a gradual increase of necrotic hepatocytes with abundant vacuolated spaces, as well as vascular congestion and hemorrhagic signs in sinusoids in the groups intoxicated with *Kh* fruit. These signs agree with the findings reported by Bermúdez et al., (1986) who studied the effect of T-514, one of the toxins isolated from *Kh* fruit on liver.

The increasing areas of necrosis in the treated groups were observed in the morphometric analysis, showing the highest amount of necrotic cells in the paralysis group that decreased in the recovery group. This finding has not been described before for chronic intoxication with *Kh* fruit. It has been described that several plants as *Larrea tridentata* (Stickel et al., 2000), and *Ruta graveolens* (Serrano-Gallardo et al., 2013) can cause a hepatotoxic effect similar to the necrotic damage observed in this study.

Another important point is that even though experimental studies of acute intoxication in different animal species with isolated toxins or *Kh* fruit have reported similar alterations in liver to those observed in the present investigation (Bermúdez et al., 1986; 1992). These studies do not report the progression and recovery of the histopathological damage in the liver observed in the present investigation.

The liver necrosis observed in the present investigation correlates with other experiments reporting that acute administration of ground fruit of *Kh* causes a significant increase of transaminases AST and ALT levels in serum (Jaramillo et al., 2009), where the increase of these enzymes is indicative of hepatic necrosis.

An *in vitro* study using the toxin T-514 showed that it suppresses the metabolic activity of mitochondria and it induces the production of reactive oxygen species, both in primary cultures of hepatocytes and microsomes (Garza-Ocañas et al., 2003). Furthermore, an *in vitro* study performed by Wheeler et al., (1971) using ether extracts of *Kh* reported that the extracts decreased oxygen consumption, and they produced inhibitory effects. In the same study they observed an uncoupling

effect of the respiration chain and an inhibition in the oxidative phosphorylation in mitochondria from rat liver (Wheeler et al., 1971). These alterations could be part of the mechanisms of hepatic cytotoxicity observed in the present investigation.

The recovery of liver necrosis observed in the recovery group at 112 days post-intoxication with *Kh*, correlates with the high capacity of regeneration of hepatocyte as it has been reported in experimental models treated with chemical agents, where the organ regenerates when the toxic stimulus is removed (Fausto et al., 2000). Moreover, the hepatic steatosis observed in treated groups in this study has not been reported previously in the chronic intoxication model with *Kh* fruit. The finding that it was reversible in the recovery group correlates with reported experimental intoxications with chemical agents where hepatic steatosis is a normal response to toxic stimuli, and it is a reversible injury when the stimulus is removed (Riet-Correa et al., 1986; Islas et al., 1991).

On the other hand, it has been proposed that steatosis is caused by an inhibition of the hepatic lipid transportation system (Fromenty et al., 1995; Jaeschke et al., 2002; Xu et al., 2003). These findings suggest that during the chronic intoxication with *Kh* there is induction of steatosis in the treated groups, but probably the toxic stimulus decreases or ends at the last stages allowing the reversal of hepatic steatosis observed in the recovery group.

In the present study, the areas of necrotic cells were analyzed with the TUNEL assay for chromatin fragmentation, one of the characteristics of apoptosis; and the results showed that few cells were positive in control and intoxicated groups, which demonstrated a normal turnover of hepatocytes. However, no significant difference in the number of positive cells was found among all groups. These results are different compared to findings described in liver of rats treated with *Ruta graveolens* where necrotic and apoptotic hepatocytes were detected in intoxicated groups (Serrano-Gallardo et al., 2013; Soto-Domínguez et al., 2013). In liver of CD-1 mouse intoxicated with 28 mg of PA1 (toxin T-514)/kg body weight, it was observed that apoptosis was extensive in liver samples (Soto-Domínguez, 2005), in contrast to the present investigation that demonstrated a necrotic effect of *Kh* fruit.

Using the specific monoclonal antibody anti-PCNA, we observed the largest number of positive cells in the control group; that gradually decreased in intoxicated groups and increased again in the recovery group. This was confirmed in the morphometric analysis. These results are similar to those observed in liver of rats treated with *Ruta graveolens* where this plant showed an antiproliferative effect in intoxicated groups (Serrano-Gallardo et al., 2013).

The observation of histopathological alterations in the liver of animals intoxicated with *Kh* fruit, contributes to the knowledge of the toxicological effect of this plant to

determine whether this intoxication also affects other organs besides the central and peripheral nervous system. Further studies will be required to elucidate the mechanism of damage and recovery in the hepatocytes observed in this study. Currently *in vitro* and *in vivo* studies, related to the aforementioned observations are being performed in the present investigation, as well as studies to evaluate the effect of toxins isolated from the *Kh* seed, such as T-514 administered at different durations and concentrations.

Conflict of Interests

The authors have not declared any conflict of interests.

ACKNOWLEDGMENTS

This study was supported by a grant from CONACYT for RGG. We acknowledge the work of QCB Rosa Maria Leal G. and Nora Frías Trejo for technical assistance involved in electron microscopy processing and ultramicrotomy, and to Stefanie Galue for reviewing English manuscript. Present study is dedicated to memory of Ph.D. Julio Sepúlveda-Saavedra (†February 10th, 2014) Chairman of Histology Department, Faculty of Medicine, UANL until the day of his death.

REFERENCES

- Arellano CE, Mendoza CJ, Domínguez CF (1994). Intoxicación por *Karwinskia johnstonii*: Estudio de 12 pacientes. Bol. Med. Hosp. Infant. Mex. 51:1051-112. Available at: <http://cat.inist.fr/?aModele=afficheN&cpsid=3964264>
- Becerra-Verdin EM, Bermúdez-Barba MV, Salazar-Leal ME, Ancer Rodríguez J, Romero-Díaz V, Soto-Domínguez A, Ballesteros-Eliozone RG, Saucedo-Cardenas O, Piñeyro Lopez A, Sepúlveda-Saavedra J (2009). *Karwinskia humboldtiana* (buckthorn) fruit causes Central Nervous System damage during chronic intoxication in the rat. Toxicol 53(6):645-51.
- Bermúdez MV, González-Spencer D, Guerrero M, Waksman N, Piñeyro A (1986). Experimental intoxication with fruit and purified toxins of Buckthorn (*Karwinskia humboldtiana*). Toxicol 24:1091-1097.
- Bermúdez MV, Lozano FE, Salazar ME, Waksman N, Piñeyro A. (1995). Intoxicación de una familia con *Karwinskia humboldtiana* (tullidora). Gac. Méd. Mex. 131:100-106.
- Bermúdez MV, Martínez FJ, Salazar ME, Waksman N, Piñeyro A. (1992). An experimental acute intoxication with Ripe Fruit of *Karwinskia humboldtiana* (tullidora) in Rat, Guinea pig, Hamster and Dog. Toxicol 30:1493-1496.
- Bustamante S, Olvera R, Correa N (1978). Intoxicación fatal por tullidora (*Karwinskia humboldtiana*). Gac. Méd. Mex. 4:241-244.
- Castillo-Nájera F (1920). Contribución al estudio de la parálisis tóxica. Un envenenamiento colectivo con tullidora. En Memoria del V Congreso Médico. Dirección de Talleres Gráficos Méx. pp. 240-244.
- Charlton KM, Pierce KR (1970). A Neuropathy in Goats Caused by Experimental Coyotillo (*Karwinskia-humboldtiana*). Poisoning Part V Lesions in the Central Nervous System. Pathol. Vet. 7:435-47.
- Díaz-Pérez RN, Castillo-González JA, Carcaño-Díaz K, García-Juárez J, Salazar-Leal ME, Montes-de-Oca-Luna R, Saucedo-Cárdenas O and Soto Domínguez A (2016). Histopathological Alterations in Striatum Caused by *Karwinskia humboldtiana* (Buckthorn) Fruit in An Experimental Model of Peripheral Neuropathy. Histol. Histopathol. 31:393-402.
- Dreyer DL, Arai I, Bachman CD, Anderson WR, Smith RG, Daves GD. (1975). Toxins Causing no inflammatory Paralytic Neuropathy Isolation and Structure Elucidation. J. Am. Chem. Soc. 97:4895-990.
- Escobar A, Nieto D (1965). Aspectos neuropatológicos de la intoxicación con *Karwinskia humboldtiana*. Estudio experimental. Gac. Med. Mex. 95:163-177.
- Fausto N (2000). Liver regeneration. J. Hepatol. 32:19-31.
- Fernández R (1992). Nombres Comunes uso y distribución del genero *Karwinskia* (*Rhamnaceae*) en México. Anal. Inst. Biol. Univ. Auton. Méx Set Bot. 63:1-23.
- Fromenty B, Pessayre D (1995). Inhibition of mitochondrial beta-oxidation as a mechanism of hepatotoxicity. Pharmacol. Ther. 67(1):101-154.
- García R, Salazar ME, Becerra EM, Romero V, García J, Soto A, Sepúlveda J (2013a). Lung and Peripheral Nerve Mast Cells in Chronic Intoxication with *Karwinskia humboldtiana* in Wistar Rat: Histological and Histochemical Studies. Int. J. Morphol. 31(4):1216-1222.
- García GR, Salazar LME, Romero DV, García JJ, Soto DA, Juárez ROA, Sepúlveda SJ (2013b). Chronic Intoxication with Ripe Fruit of *Karwinskia humboldtiana* in Wistar Rats: Renal Damage. Int. J. Morphol. 31(4):1449-1454.
- García-Juárez J, Salazar-Leal ME, Guzmán-López S, Romero-Díaz VJ, Ramírez-Durón R, Sepúlveda-Saavedra J (2012). Evaluation of the Effect of Treatment with Lipoic Acid Administered to the Wistar Rat Intoxicated with the Fruit of *Karwinskia humboldtiana*. Int. J. Morphol. 30 (2):572-578.
- Garza-Ocañas L, Zanatta-Calderón MT, Acosta A, Torres-Alanis O, Piñeyro-López A (2003). Production of reactive oxygen species by toxin T-514 of genus *Karwinskia in vitro*. Toxicol. *in vitro*. 17(1):19-25.
- Gavrieli Y, Sherman Y, Ben-Sasson SA (1992). Identification of programmed cell death *in situ* via specific labeling of nuclear DNA fragmentation. J. Cell Biol. 119(3):493-501.
- Islas A (1991). Intoxicación con palqui (*Cestrum parqui*) en bovinos. Pat. Anim. 5(1):32-33.
- Ito S, Karnowsky M (1968). Formaldehyde-glutaraldehyde fixative containing trinitro compounds. J. Cell Biol. 39:168a-9a.
- Jaeschke H, Gores GJ, Cederbaum AI, Hinson JA, Pessayre D, Lemasters JJ. (2002). Mechanisms of Hepatotoxicity. Toxicol. Sci. 65(2):166-176.
- Jaramillo J, Rodríguez V, Castillo C, Quezada T, Cerda G, Posadas F, Taboada C (2009). Daño hepático y en la coagulación de la sangre producido por la administración de los frutos maduros de la planta tullidora (*Karwinskia humboldtiana*) en la rata. Rev. Mex. Cienc. Farm. 40(1):28-34.
- Matsumoto K, Moriuchi T, Koji T, Nakane PK (1987). Molecular cloning of cDNA coding for rat proliferating cell nuclear antigen (PCNA)/cyclin. EMBO J. 6(3):637-42.
- Muñoz ME, Chávez B (1979). Conduction block and functional denervation caused by tullidora (*Karwinskia humboldtiana*). Exp. Neurol. 65:255-270.
- Muñoz ME, Chávez B, Nathan J (1983). Denervation caused by tullidora (*Karwinskia humboldtiana*). Neuropathol. Appl. 9(2):121-134.
- Ocampo RL, Ontiveros NO, Fernández LO (2007). Intoxicación with buckthorn (*Karwinskia humboldtiana*): report of three siblings. Pediatr. Dev. Pathol. 10:66-68.
- Padron-Puyou F (1951). Clinical and experimental studies on paralysis in children due to *Karwinskia humboldtiana*. Gac. Med. Mex. 81(2-4):299-311.
- Padrón F, Velázquez T (1956). Patología experimental y clínica de la parálisis por *Karwinskia humboldtiana*. Rev. Mex. Ped. 25:225-237.
- Puértolas MM, Nava JO, Medina LH, López OF, Oyervides PJ (1984). Polirradiculoneuritis por *Karwinskia humboldtiana*. Informe de seis casos. Rev. Med. IMSS. (Mex). 22:22-27.
- Riet-Correa F, Schield AL, Méndez MC, Pinheiro MH (1986). Intoxicação por *Cestrum parqui* (*Solanaceae*) em bovinos no Rio Grande do Sul. Pesq. Vet. Bras. 6:111-115.
- Rivas V, Torres R, Waksman N (1990). Dimeric anthracenones from *Karwinskia* species. J. Med. Plant Res. 56(6):562-564.
- Secretaría de Agricultura, Ganadería, Desarrollo Rural, Pesca y Alimentación (SAGARPA) (1999). Norma Oficial Mexicana NOM-062-

- ZOO-1999, Especificaciones técnicas para la producción, cuidado y uso de los animales de laboratorio.
- Salazar-Leal ME, Flores MS, Sepúlveda-Saavedra J, Romero-Díaz VJ, Becerra-Verdín EM, Taméz-Rodríguez VA, Martínez HR, Piñeyro-López A, Bermúdez MV (2006). An experimental model of peripheral neuropathy induced in rats by *Karwinskia humboldtiana* (buckthorn) fruit. *J. Peripher. Nerv. Syst.* 11(3):253-61.
- Segovia PA, Zermeño F (1972). Polirradiculoneuritis tóxica por *Karwinskia humboldtiana*. A propósito de un caso. *Biol. Med. Hosp. Infant.* 29:98-90.
- Sepúlveda-Saavedra J, González-Corona B, Taméz-Rodríguez VA, Bermúdez MV, Piñeyro A (1992). Ultrastructure of the lesion induced by toxin T-514 isolated from *K. humboldtiana* in the alveolar region of the lung. *Proc. 50th Ann. Meet. EMSA.* Bailey GW, Bentley J, Small JA (Eds). Published by San Francisco press, Inc. pp. 640-641.
- Serrano-Gallardo LB, Soto-Domínguez A, Ruiz-Flores P, Nava-Hernández MP, Morán-Martínez J, García-Garza R, Martínez-Pérez EF (2103). Toxic Effect of Aqueous Extract of *Ruta graveolens* from the North of Mexico on the Liver of Wistar Rat. *Int. J. Morphol.* 31(3):1041-1048.
- Soto-Domínguez A (2005). Evaluación morfológica y bioquímica de la presencia de apoptosis en varios órganos del ratón tratado con una dosis tóxica de Peroxisomicina A1, 2005. Tesis de Maestría. Facultad de Medicina. UANL.
- Soto-Domínguez A, Serrano-Gallardo LB, García-Garza R, Ruiz Flores P, Morán-Martínez J, Nava-Hernández MP, Martínez-Pérez EF (2013). Aqueous Extract of *Ruta graveolens* From the North of Mexico Causes Apoptosis and Shows Antiproliferative Effect on the Liver of Wistar Rat: Morphological Evidence. *Int. J. Morphol.* 31(4):1340-1348.
- Stickel F, Egerer G, Seitz H (2000). Hepatotoxicity of botanicals. *Public Health Nutr.* 3:113-124.
- Wheeler MH, Camp BJ (1971). Inhibitory and uncoupling actions of extracts from *Karwinskia humboldtiana* on respiration and oxidative phosphorylation. *Life Sci.* 10(1):41-51.
- Waksman N, Martínez L, Fernández R (1989). Chemical and toxicological screening in genus *Karwinskia*. *Rev. Latinoamer. Quim.* 20(1):27-29.
- Waksman N, Ramirez R (1992). Isolation of a new dimeric anthracenone from *Karwinskia parvifolia*. *Rev. Latinoamer. Quim.* 23(1):25-27.
- Xu A, Wang Y, Keshaw H, Xu LY, Lam KSL, Cooper GJS (2003). The fat-derived hormone adiponectin alleviates alcoholic and nonalcoholic fatty liver diseases in mice. *J. Clin. Inv.* 112(1):91-100.
- Zhang G, Gibbs E, Kelman Z, O'Donnell M, Hurwitz J (1999). Studies on the interactions between human replication factor C and human proliferating cell nuclear antigen. *Proc. Natl. Acad. Sci. U.S.A.* 96(5):1869-74.