

Full Length Research Paper

Effects of oral administration of crude leaf extracts of *Aglaia loheri* Blanco and *Ardisia pyramidalis* (Cav.) Pers on mouse embryo morphology and maternal reproductive performance

Annabelle A. Herrera*, Rich Ericson C. King and Lerrie Ann D. G. Ipulan

Institute of Biology, College of Science, University of the Philippines, Diliman. BLIB Philippines.

Accepted 20 June, 2011

Aglaia loheri Blanco and *Ardisia pyramidalis* (Cav.) Pers are both endemic plant species with a variety of bioactive compounds, but remain largely untested for their toxicity, and their effects on maternal reproductive performance and fetal morphology. Inbred ICR mice were orally administered with 10 and 5 mg/ml concentrations for *A. loheri*, and 10 and 1 mg/ml concentrations for *A. pyramidalis* from the 8th to the 15th day of pregnancy. Dissection at 16 days post coitum (dpc) showed significant differences in maternal reproductive performance, as estimated by gestation index, % dead implants, % females with resorption, % resorption and % fetus with morphological abnormalities. For *A. pyramidalis*, the 1 mg/ml extract + vitamin A treatment reduced maternal reproductive performance most significantly, while, for *A. loheri*, treatment with 10 mg/ml extract, with or without vitamin A, as well as with 5 mg/ml extract only resulted to a 100% resorption. Additionally, maternal hepatotoxicity was observed in mice treated with *A. pyramidalis*, while significant weight losses among mice treated with higher doses of *A. loheri* + vitamin A suggests toxicity and synergism with vitamin A. These results suggest that caution must be taken when taking these extracts during pregnancy due to their possible toxicity and teratogenicity.

Key words: *Aglaia loheri* Blanco, *Ardisia pyramidalis* (Cav.) Pers, Meliaceae, Myrsinaceae, teratogenicity, hypervitaminosis A, reproductive performance, embryo morphology.

INTRODUCTION

Women remain susceptible to illnesses at any time during pregnancy and possibly require treatment with prescription drugs to protect their own health as well as that of the fetus. In other circumstances, a woman may be taking a medication before she is aware of her pregnancy, or become pregnant while undergoing a treatment. However, among all of the drug treatments approved in the United States between 1980 and 2000, 91.2% of them still have undetermined teratogenic risks associated with human pregnancies. Because of this, for most of the drug treatments introduced in the past 20 years, there exists an inadequacy of information available for pregnant women and their physicians to determine whether the benefits of undergoing a particular treatment

or medication exceeds the teratogenic risks that may come along with it (Lo and Friedman, 2002).

Teratogens are compounds that cause insult to a developing conceptus, and in doing so, induce the development of congenital defects (Keeler, 1984). The embryo is most sensitive to teratogenic agents from fertilization through the early postimplantation stage. During this period, the "all of none effect" occurs where the embryo is more likely to die than to survive with congenital malformations (Brent and Fawcett, 2004). This period is also called the "resistant period", because totipotent cells at this stage are able to recover from injury and continue to multiply normally (Arabia and Herrera, 2003). The period of organogenesis, which spans from the 18th to the 40th day after conception in humans, is the stage when most anatomical malformations can be induced. Exceptions to this include malformations of the genito-urinary system, the palate, the brain, and deformations due to physical constraints

*Corresponding author. E-mail: annabelle.a.herrera@gmail.com.
Tel: (02)922-3585, (02) 920-5471. Fax: (02)920-5471.

(Brent and Fawcett, 2004). The stage of organogenesis is also called the "maximum susceptibility stage", because generally, after an organ has fully developed, a teratogenic agent may no longer induce malformations on it (Arabia and Herrera, 2003). Cell growth, differentiation and migration characterize the histogenesis that occurs in the subsequent fetal period. Teratogens that induce cell depletion, vascular disruption, necrosis, tissue or organ pathology, functional derangement or growth retardation can potentially cause abnormalities at this stage, as with all other stages of gestation. While microcephaly and mental retardation are induced at the first trimester and the beginning of the second trimester, most other neurological effects are induced during the second and third trimesters (Brent and Fawcett, 2004).

Severe congenital malformations, which include birth defects that lead to death, hospitalization or mental retardation, or demand surgical procedures or interfere with physical performance, occur in 3% of all births worldwide. According to a recent study, 65 to 75% of human congenital malformations still have unknown causes, which are assumed to be effects of gene-environment interactions, polygenes, synergistic interactions of teratogens and spontaneous errors during development. Inherited genetic diseases, chromosomal abnormalities and new mutations cause 15 to 25% of reported cases of human congenital malformations. The remaining 10% of cases of congenital abnormalities result from harmful maternal conditions, infections, mechanical problems, as well as chemicals, drugs and radiation among others (Brent, 2004).

Drugs that have been known to induce malformations when taken during pregnancy include Etretinate, Isotretinoin and Thalidomide that all pose a high teratogenic risk, as well as Captopril, Enalapril Maleate and Lisinopril that are known to cause moderate teratogenic risk late in pregnancy (Lo and Friedman, 2002). It is then important that antiteratogenic agents of different activities be discovered, so that in the unfortunate and unavoidable event that exposure to a teratogenic agent occurs during pregnancy, an appropriate treatment that can best inhibit the occurrence of malformations can readily be undertaken.

This study involves the investigation of the effects of two plant species endemic to the Philippines, *Ardisia pyramidalis*, and *Aglaiia loheri* on mouse embryogenesis and maternal reproductive performance. *Ardisia* species have exhibited protective action against human immunodeficiency virus (HIV) and Herpes Simplex Virus (HSV), in addition to its anti-cancer, anti-fungal and anti-malarial activities, among others (Sumino et al., 2002; Chiang et al., 2003; Singh et al., 2005; Noor Rain et al., 2007). Species of *Aglaiia*, on the other hand, have been shown experimentally to have promising insecticidal action, as well as anti-cancer and anti-bacterial activity (Choudhury et al., 2005; Duong, 2005; Watanabe et al., 1998).

The importance of this study lies on the demonstration of the effects of these endemic species with a unique variety of bioactive potentials compared to known teratogenic drugs. Alternatively, this study may also demonstrate the possible teratogenic action of these particular plant extracts, as well as their toxicity to the mother.

MATERIALS AND METHODS

Test animal

Six to eight-week old ICR strain weighing between 25 and 30 grams were utilized as test subjects. Acclimatization of mice to laboratory conditions took place for two weeks, during which and throughout the study, food in the form of standard pellets and water *ad libitum* were provided, as well as other requirements imposed by the University of the Philippines College of Science Animal Care and Use Committee. Only reproductively mature females were used for mating.

Plant material

Fresh, mature leaves of *A. pyramidalis* and *A. loheri* were collected from their natural habitat in Bataan, Philippines. The collected specimens were transported to the Developmental Biology Laboratory of the Institute of Biology, University of the Philippines, Diliman, Quezon City, Philippines, where these were dried and extraction was undertaken.

Bulk extraction and solution preparation

Fresh, mature leaves of *A. pyramidalis* and *A. loheri* were removed from the stems, washed with running water and air-dried for two weeks to a weight of approximately 1 kg. The leaves were then cut into small pieces and homogenized with a blender before soaking in methanol and filtered. The filtrate was then concentrated *in vacuo* at a maximum temperature of 40°C using a rotary evaporator, and diluted to the desired concentrations, 10 and 5 mg/ml for *A. loheri* and 10 and 1 mg/mL for *A. pyramidalis*, using distilled water. The prepared solutions were then chilled at 4°C prior to administration in order to prevent the degradation of the active compounds.

Vitamin A used in this study was in the form of retinol palmitate (Afaxin), commercially-available in 50,000 IU soft-gel capsules.

Application of extracts and determination of toxicity or antiteratogenic potential

Reproductively mature female mice with regular cycles were selected and mated with male mice at a maximum of a 2 female: 1 male ratio. The presence of a copulatory plug in females was used as an evidence for the occurrence of mating. The day of copulatory plug appearance was referred to as day one of pregnancy. The females were transferred to a separate cage with a maximum of nine mice per cage. The females were subsequently weighed on a weekly basis, with gradual but steady increases in weight used to confirm pregnancy.

In order to determine the toxicity of the extract, pregnant mice were administered with 0.5 ml of one of the four treatment solutions via oral gavage from the 8th through the 15th day after the appearance of the vaginal plug. For the testing for antiteratogenic potential, treatment with 0.5 ml extract was coupled with treatment

Table 1. Effects of oral administration of *A.loheri* extract on mouse embryogenesis and maternal reproductive performance in ICR mice.

Parameter	Control			10 mg/ml <i>A. loheri</i>			5 mg/ml <i>A. loheri</i>		
	12500 IU	vitamin A only	H ₂ O	12500 IU	vitamin A	H ₂ O	12500 IU	vitamin A	H ₂ O
No. of replicates	5		3	5		5	4		4
No. females with implants	1		3	1		0	0		1
Gestation index	20		100	0		0	0		25
% Dead implants	80		0	100		100	100		75
% Female with resorption	80		0	100		100	100		75
% Resorption	80		0	100		100	100		75
% Fetus with MA	100		0	100		100	100		63.64
Average fetal weight (g)	0.4		0.47	n/a		n/a	n/a		0.37

of 12500 IU vitamin A supplement. For the negative control, 0.5 ml distilled water was used, while 12500 IU vitamin A supplement alone served as the positive control. Treatments were performed with a minimum of three replicates per treatment.

Dissection of pregnant mice

On the 16th day, pregnant females were sacrificed by cervical dislocation, and dissected to expose the uterine horns. The number of implants, resorptions, live and dead fetuses was recorded. Gestation index, % of dead implants, % of females with resorptions and % resorption were calculated. Fetuses were then obtained and fixed overnight in fresh buffered 4% paraformaldehyde for the morphological and histochemical preparations.

Morphological examination

Embryos were observed under a stereomicroscope and noted for the presence of any morphological abnormalities. These include an angular head shape, unelongated snout, delayed appearance or absence of otic and optic vesicles, delayed development or absence of forelimbs, hindlimbs and digits, excessive skin wrinkling, bulging of visceral and umbilical areas, tail growth and changes in skin texture and color. The percentage of fetus with morphological abnormalities was calculated for each treatment.

Histochemical analysis of skeletogenesis

After overnight fixation in 4% paraformaldehyde, the embryos were fixed in 90% ethanol for 10 days and subsequently stained following the Alizarin Red S and Alcian Blue double staining method. Pink stains represent the bone while blue stains represent the cartilage.

Statistical analysis

The non-parametric Kruskal-Wallis test was performed on the reproductive performance data. Significant differences were identified between specific treatments using the Mann-Whitney test.

RESULTS

Maternal toxicity

In order to detect maternal toxicity, the weight records of

the treated mice which did not proceed with pregnancy were summarized in Table 1 to allow comparison between the treatment groups. The weight records of pregnant mice were disregarded. This is because during pregnancy, any weight loss that is associated with maternal toxicity may be matched by a weight increase associated with pregnancy, such that considering the weight records of pregnant mice would give an improper description of the extent of toxicity.

Non-pregnant mice treated with 12500 IU vitamin A alone experienced some degree of weight loss starting generally from the 8th day through the 16th day after mating, which coincides with the days of vitamin A treatment. This positive control group lost an average of 21.57% (S.D. = 6.29%) of body weight through the nine days of treatment, with the greatest weight loss reaching 27.27% of body weight. However, no maternal lethargy or mortality was observed for this treatment.

When 12500 IU vitamin A was administered together with 10 mg/mL *A. loheri* extract, maternal weight loss was further enhanced, averaging 33.52% (S.D. = 9.13%) of body weight, with the greatest weight loss reaching 41.12% of body weight. Two of the five treated mice exhibited observable lethargy and weakness, along with the occurrence of a pronounced increase in spinal curvature (Figure 1). Both mice eventually died, one at day 15 while the other at day 16, with the latter also experiencing vaginal bleeding and discharge of one resorbed embryo (Figure 2a).

Mice treated with 12500 IU vitamin A and 5 mg/ml *A. loheri* extract daily starting from the 8th day also demonstrated some degree of weight loss. The dosage of vitamin A was decreased to only 2500 IU from day 13 to 15. Weight loss over the course of the treatment period averaged at 17.97% (S.D. = 8.68%) of body weight, with the greatest weight loss reaching 26.79% of body weight.

There were no observed anomalies in the weight record of mice treated with different concentrations of *A. pyramidalis* extract alone, or together with 2500 IU vitamin A. These treatments also had no occurrence of mortality, or abnormalities in behavior or appearance. However, upon dissection, there were observed cases of

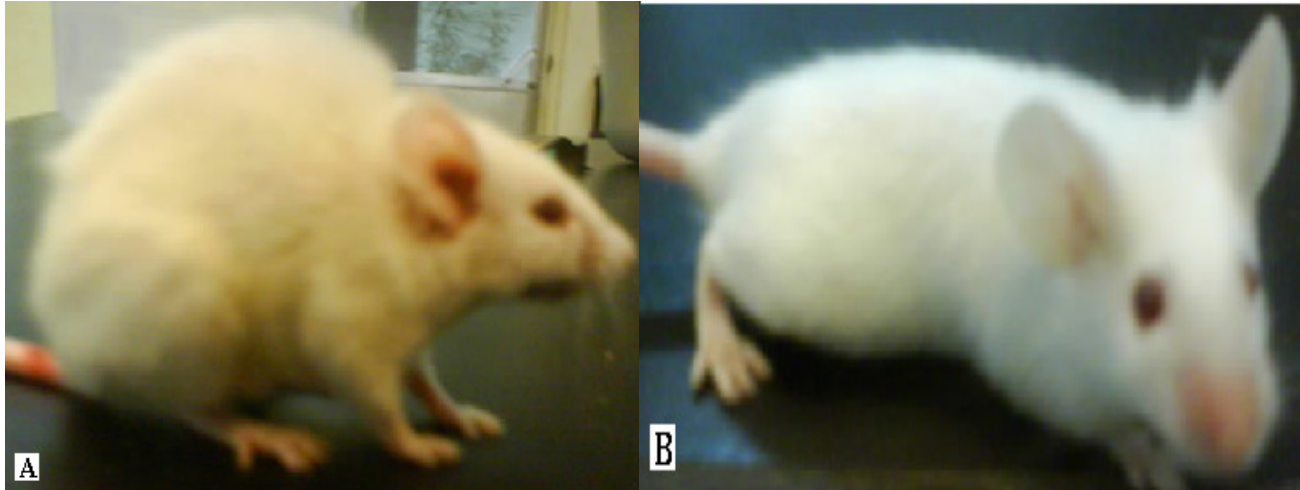


Figure 1. (A) Exaggerated spinal curvature in mice treated with 10 mg/ml *A. loheri* with 12500 vitamin A, compared to (B) normal spinal curvature in untreated mice. % Dead implants = $100 - \text{Gestation index}$, % Female with resorption = $\frac{\text{No. of females with resorptions}}{\text{No. of pregnant females}}$, % Resorptions = $\frac{\text{Total no. of resorptions}}{\text{Total no. of fetus}} \times 100$, % Fetus with morphological abnormalities (MA) = $\frac{\text{No. of fetus with MA}}{\text{Total no. of fetus}} \times 100$, % Fetus with skeletal abnormalities (SA) = $\frac{\text{No. of fetus with SA}}{\text{Total no. of fetus}} \times 100$.

an abnormal lack of pigmentation in the liver. One out of five (20%) of the mice treated with vitamin A and 10 mg/ml *A. pyramidalis* extract exhibited this kind of abnormality. This abnormality was also observed in one out of nine (11.11%) of the mice treated with 10 mg/ml *A. pyramidalis* extract only. Furthermore, it was observed that the abnormal liver obtained from extract + vitamin A treatment was even less pigmented, having a paler coloration than the abnormal liver from the extract only treatment (Figure 3). The rest of the mice in these treatment groups, as well as all the mice from other treatment groups exhibited normal liver pigmentation similar to the negative control.

It was also noted that among non-pregnant mice treated with extract only, there was a slight weight increase during the duration of the treatment period for 10 mg/ml *A. pyramidalis* extract (3.69% of body weight) and 5 mg/ml *A. loheri* extract (4.69% of body weight), whereas there was a slight weight decrease for 10 mg/ml *A. loheri* extract (5.01% of body weight). No data exists for mice treated with 1 mg/ml *A. pyramidalis* extract, because all treated mice for this setup proceeded with pregnancy.

Reproductive performance

The reproductive performance of the treated mice are summarized in Tables 2, which show the differences between the different treatments in terms of gestation index, % dead implants, % females with resorption, % resorption, % fetus with morphological abnormalities, as well as average fetal weights.

The implantation index shows the total number of

implantations per pregnant female, considering both the live and the dead implants. This was not obtained in this study because of the difficulty in numbering the implantation sites among pregnancies that were evidenced by extensive vascularization only.

The gestation index for each treatment group describes the survivability of the implants after exposure to the treatment, and is taken as the proportion of live implants among the total number of implantations for that treatment group. Results from the Mann-Whitney test revealed that for *A. pyramidalis*, most of the treatment groups did not vary in gestation index, except for the treatment with 1 mg/ml concentration combined with 2500 IU vitamin A, wherein the gestation index was found to be lower than the other treatments. On the other hand, for *A. loheri*, the gestation index for the treatment with 10 mg/ml concentration with or without vitamin A, and 5 mg/ml concentration combined with vitamin A did not vary significantly with the positive control data, which all demonstrated a gestation index of 0%. As expected, the negative control exhibited the highest gestation index, while that of the 5 mg/ml concentration of extract only gave a gestation index of an intermediate value.

The percentage of dead implants as well as the percentage of females with resorptions and percent resorption is related to the teratogenicity of the treatment administered. The term dead implant in this study includes both dead fetuses characterized by a morphology that is underdeveloped for a 16 dpc fetus and early resorptions. The trends in these indices were simply opposite to that of the gestation index. For *A. pyramidalis*, 1 mg/ml extract + 2500 IU vitamin A resulted to a higher % dead implant, % female with resorption and % resorption, compared to the rest of the treatments that

did not vary significantly with each other. Similarly, for *A. loheri*, % dead implant, % female with resorption and % resorption was lowest in the negative control, followed by the 5 mg/ml extract treatment alone, while the rest of the treatments resulted to 100% resorption.

The percent morphological abnormality gauges the potential of a treatment to induce morphological abnormalities. In this study, resorptions were also considered to have morphological abnormalities, because they would have acquired such had they continued with their development. For *A. pyramidalis*, treatments of different concentrations of extract with or without vitamin A all resulted to a frequency of morphological abnormalities lower than that of the positive control, 2500 IU vitamin A. Among the extract treatments, the 1 mg/ml extract + vitamin A treatment resulted to the highest % morphological abnormality, followed by 10 mg/ml extract + vitamin A treatment, then by 10 mg/ml extract only, and lastly by 1 mg/ml extract only. All these treatments varied significantly with each other. For *A. loheri*, all the treatments that resulted to 100% resorption are then considered to have the highest % morphological abnormality. The treatment, 5 mg/ml *A. loheri* also had a significantly higher % morphological abnormality than the negative control.

Analysis of the gross morphology of fetuses from different treatments

Normal morphology of fetuses from negative control mice

Fetuses from water-treated mice exhibited proper development, appropriately exhibiting the morphology of a Theiler stage 24 fetus. They were characterized by an elongated snout, smooth skin flushed with a pinkish coloration and prominent optic and otic vesicles. Their extremities were well-developed, and had digits that were clearly separate from each other. They had a lobe-shaped head and a slender body, in contrast to an angular head and an arched body in earlier developmental stages.

Early resorption and stalled development in fetuses from vitamin A-treated mice

Treatment with 12500 IU vitamin A resulted to a high rate of resorption, as evidenced by extensive uterine vascularization among treated mice (Figure 4). Live fetuses from these treatment exhibit underdeveloped optic and otic vesicles, a non-elongated snout, and for some, a bulging viscera. All fetuses exhibited shortened forelimbs and hindlimbs lacking one or two digits, with the digits not completely separate from one another, as well as a shortened tail. A shortened lower jaw, pale skin

coloration and a rough-textured skin are also characteristic of fetuses from this treatment (Figures 5 and 6). Pale coloration is indicative of poor fetal vascularization. Internal hemorrhage also occurred in two of the fetuses.

On the other hand, treatment with 2500 IU vitamin A did not result to any resorptions, although malformations were still seen in all of the fetuses. Limb deformations are the most common, which manifested in lacking digits, fused digits and shortened limbs. Crooked tails and arch-shaped body were also observed, as well as internal hemorrhage in one of the fetuses. In fact, gestation index, % dead implant and % resorption from this positive control group did not vary significantly with negative control data, although there was a significant increase in incidence of morphological abnormalities.

Resorption and abnormalities in the head and eyes in fetuses from mice treated with *A. loheri* extract

No live fetuses were obtained from treatments with 10 mg/ml *A. loheri* extract, with or without vitamin A, as well as with 5 mg/ml *A. loheri* extract + 12500 IU vitamin A. Out of 11 fetuses obtained from mice treated with 5 mg/ml extract only, four exhibited an underdeveloped optic capsule, three exhibited an angular head while there were two cases of internal hemorrhage (Figure 7b).

Varied morphological abnormalities observed in fetuses from mice treated with *A. pyramidalis* extract

Out of 38 fetuses obtained from the treatment with 10 mg/ml *A. pyramidalis* extract only, there was a 39.5% incidence of internal hemorrhage, 23.7% incidence of an angular head, 15.8% incidence of an arched body and 13.2% incidence of pale coloration. There was also one case of a crooked tail, while two fetuses had underdeveloped optic vesicles (Figure 7c).

Combining the treatment of 10 mg/mL concentration of this extract with the administration of 2500 IU vitamin A resulted to a 38.5% incidence of digit abnormalities in the form of unseparated digits, among 26 fetuses. There was also a 34.6% incidence of an angular head and 23.1% incidence of an arch-shaped body. In addition, there were also two cases of internal hemorrhage, and one incidence of a crooked tail.

Decreasing treatment concentration to 1 mg/ml *A. pyramidalis* extract only, the frequency of morphological abnormalities was likewise reduced to only 13.75 for an angular head, and only one case of internal hemorrhage was observed, among 22 fetuses. However, there were also five cases (22.7%) of hindered development as evidenced by small body size (Figure 8). Seven resorptions were also obtained from this treatment, as well as one dead embryo which may have ceased




Figure 2. (A) Resorption ejected at 15 dpc by the mother undergoing treatment with 10 mg/ml *A. loheri* extract + 12500 IU vitamin A, and (B) resorptions and dead implant obtained from a mother treated with 1 mg/ml *A. pyramidalis* extract only, dissected at 16 dpc.

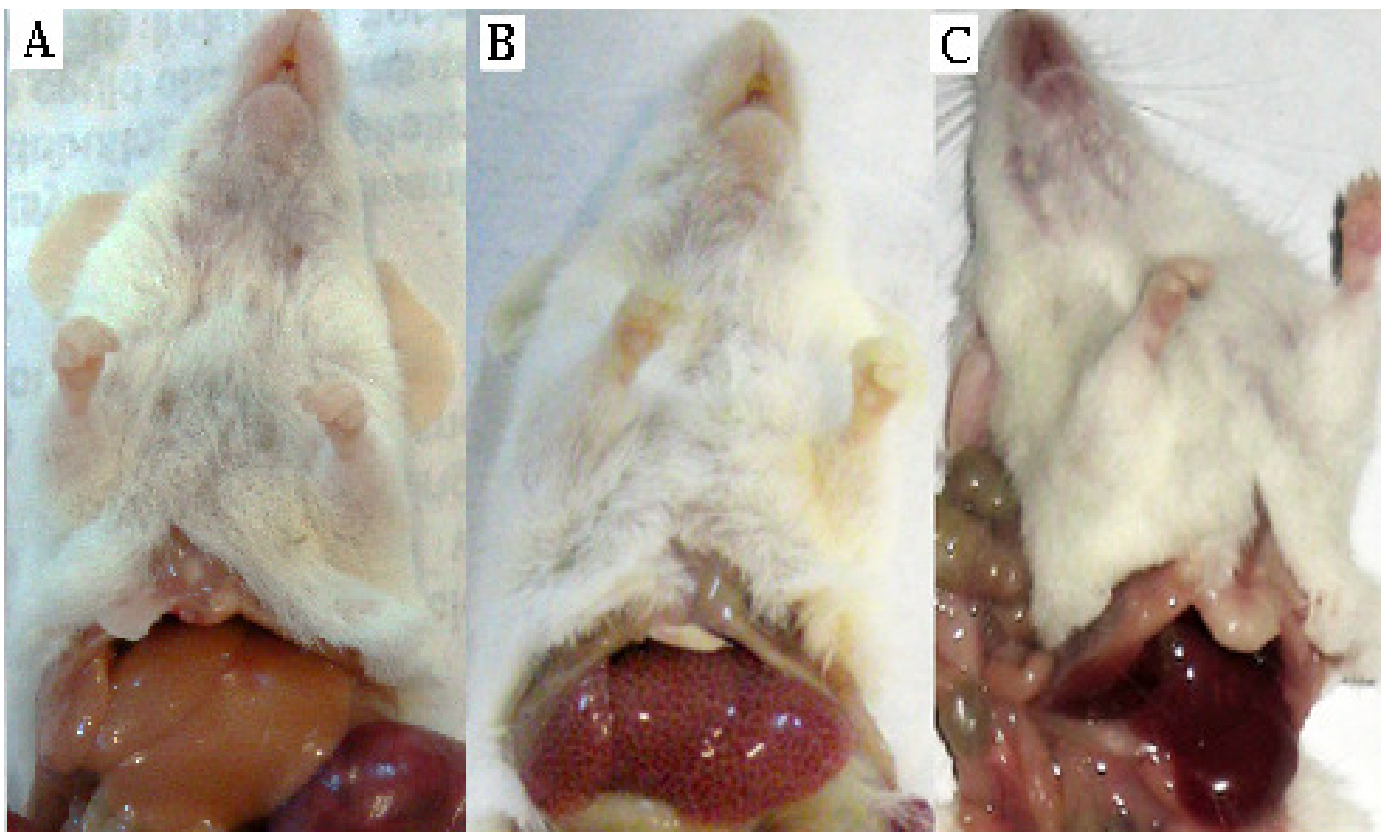

Figure 3. (A) Mouse treated with 10 mg/ml *A. pyramidalis* + 2500 IU vitamin A exhibited severe decrease in liver pigmentation, while (B) mouse treated with 10 mg/ml *A. pyramidalis* extract only exhibited considerable liver pigmentation, compared to (C) negative control mice, suggesting the hepatotoxicity of *A. pyramidalis* at this concentration.

development at around Theiler stages 15 to 19 (Figure 2b, 9 and 10). No specific morphological data exist for the 1 mg/ml *A. pyramidalis* + 2500 IU vitamin A treatment because only resorptions were obtained from this treatment.

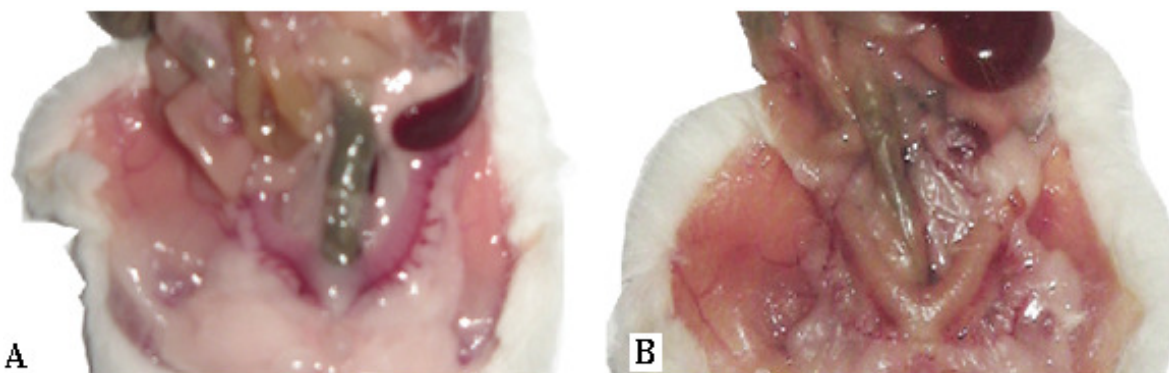
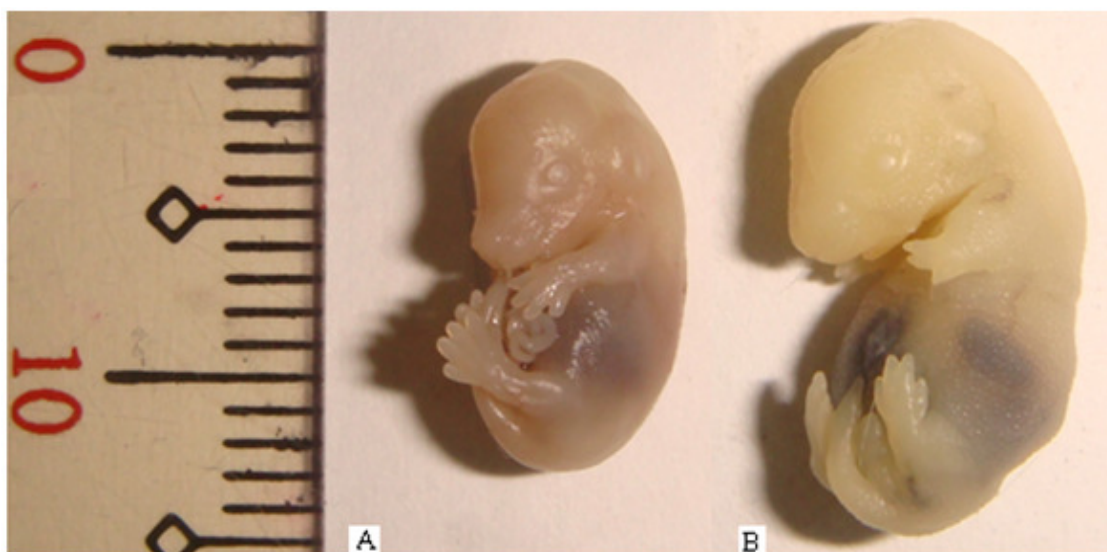
Histochemical analysis of skeletogenesis through Alizarin Red S and Alcian Blue double staining

Fetuses from mice treated with 5 mg/ml *A. loheri* showed significant staining of cartilage in the skull, limbs, tail, ribs

Table 2. Effects of oral administration of *A. pyramidalis* extract on mouse embryogenesis and maternal reproductive performance in ICR mice.

Parameter	Control		10 mg/ml <i>A. pyramidalis</i>		1 mg/ml <i>A. pyramidalis</i>	
	2500 IU vitamin A	H ₂ O	Vitamin A	H ₂ O	Vitamin A	H ₂ O
No. of replicates	3	3	5	4	3	3
No. females with implants	3	3	5	4	0	3
Gestation index	100	100	95.74	100	0	73.33
% Dead implants	0	0	4.26	0	100	26.67
% Female with resorption	0	0	20	0	100	66.67
% Resorption	0	0	4.26	0	100	23.33
%Fetus w/ MA	100	0	78.57	73.68	100	53.33
Average fetal weight (g)	0.48	0.47	0.45	0.4	n/a	0.42

Gestation index = (No. of live implants / Total no. of implants) × 100.

**Figure 4.** Comparison between (A) a highly vascularized uterus, used in this study as a sign of pregnancy, and (B) a normal, sparsely vascularized uterus in non-pregnant mice.**Figure 5.** Comparison between (A) a normal 16 dpc fetus from the negative control and (B) a 16 dpc fetus with morphological abnormalities from 12500 IU vitamin A treatment at (B) is characterized by underdeveloped optic and otic vesicles, shortened extremities, digits still partly fused, a non-elongated snout, a shortened lower jaw, pale and rough-textured skin and bulging viscera.

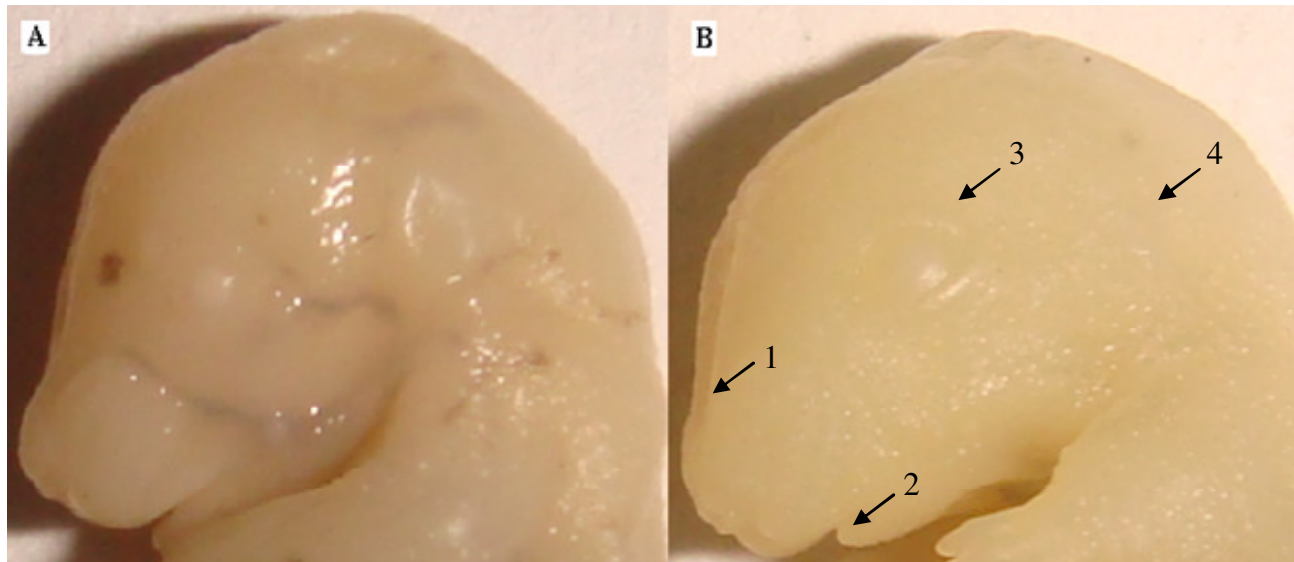


Figure 6. Comparison in head morphology between (A) a normal 16 dpc fetus from the negative control and (B) a 16 dpc fetus with morphological abnormalities from 12500 IU vitamin A treatment. at (B) exhibited (1) a non-elongated snout, and (2) a shortened lower jaw compared to the negative control. The (3) optic vesicles were underdeveloped, while the (4) otic vesicles were indistinguishable.

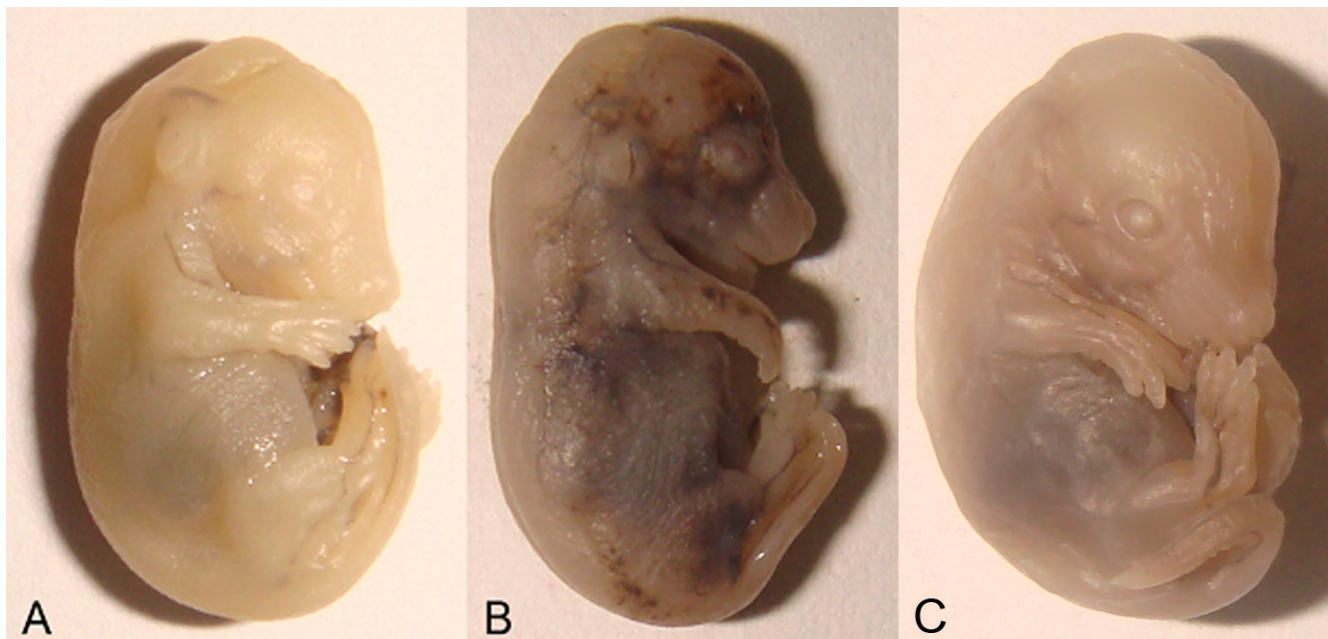


Figure 7. Lateral view of 16 dpc fetuses comparing (A) a normal fetus with (B) a fetus with internal hemorrhages from 5 mg/ml *A. loheri* extract only treatment and (C) a fetus with a crooked tail from 10 mg/ml *A. pyramidalis* extract only treatment.

and spine. Moreover, the region behind the skull exhibited a purple coloration suggesting that some degree of ossification is occurring at the time of dissection (Figure 11a).

Live fetuses obtained from mice treated with 12500 IU vitamin A exhibited limited cartilage and bone

development, as evidenced by a very lightly stained fetus after the staining procedure. The skull, limbs and tail stained blue signifying the presence of cartilage, but the spine and ribs were not visualized after staining. No ossification sites were observed from fetuses from this treatment (Figure 11b). Unfortunately, staining of the

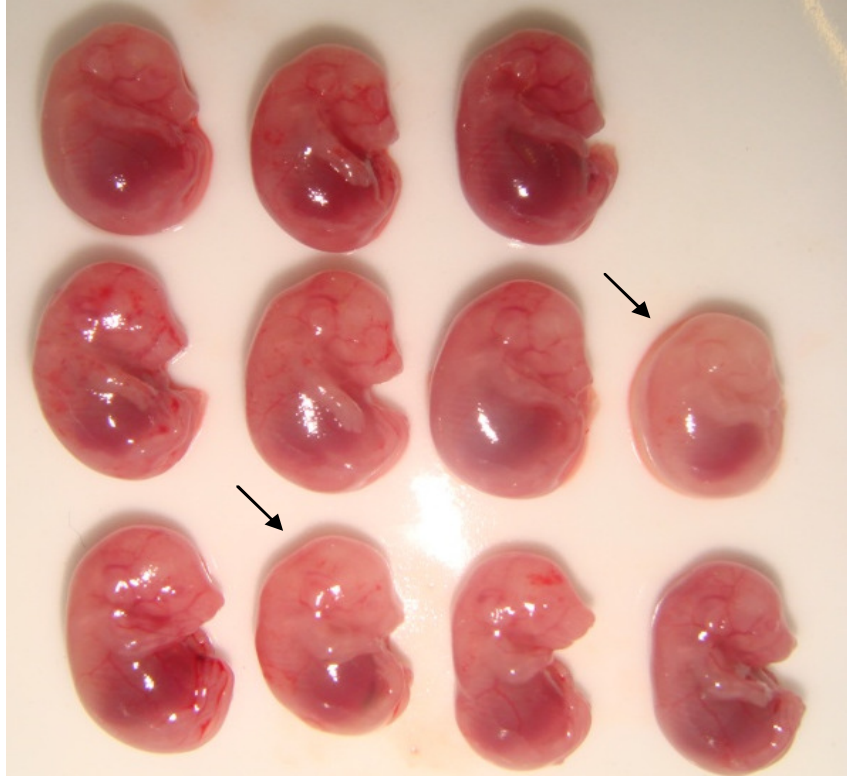


Figure 8. A litter of 11 fetuses from a pregnant mouse treated with 10 mg/ml *A. pyramidalis* extract and 2500 IU vitamin A. Fetuses with black arrows have pale coloration, are smaller than the rest of the fetuses and are arched, comparable to fetuses from earlier developmental stages.

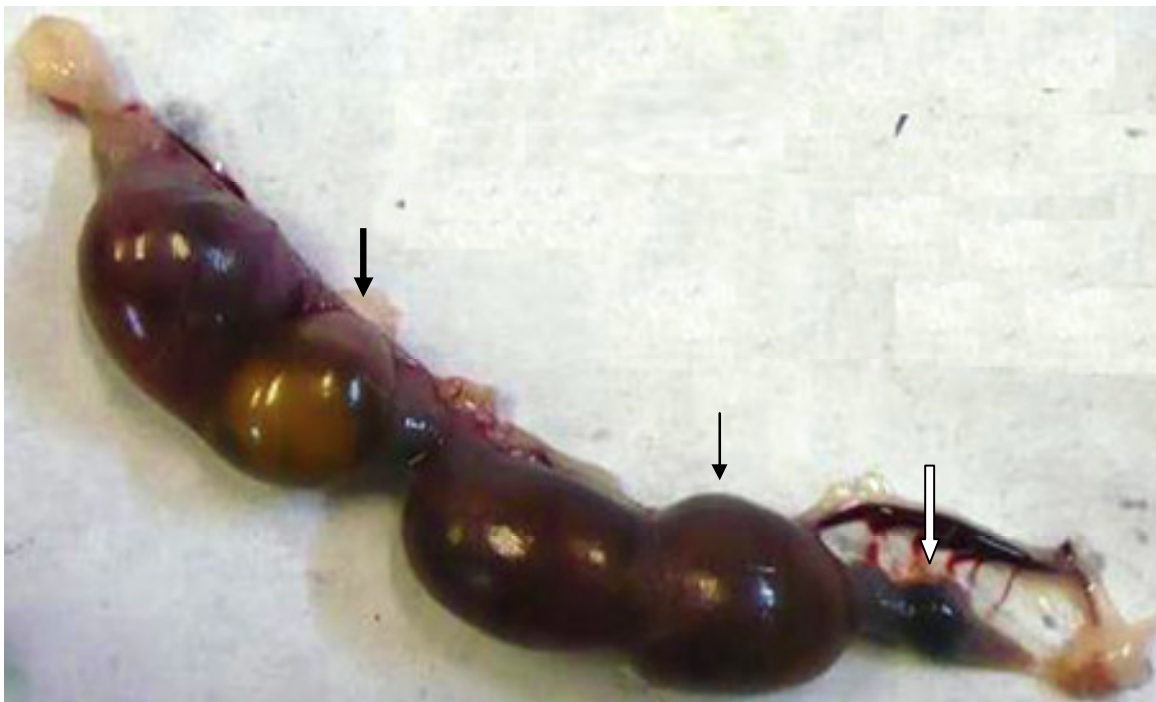

Figure 9. Fetuses of pregnant mouse treated with 1 mg/ml *A. pyramidalis* extract only, showing live implants (thin black arrow), dead implants (thick black arrow) and early resorptions (white arrow).

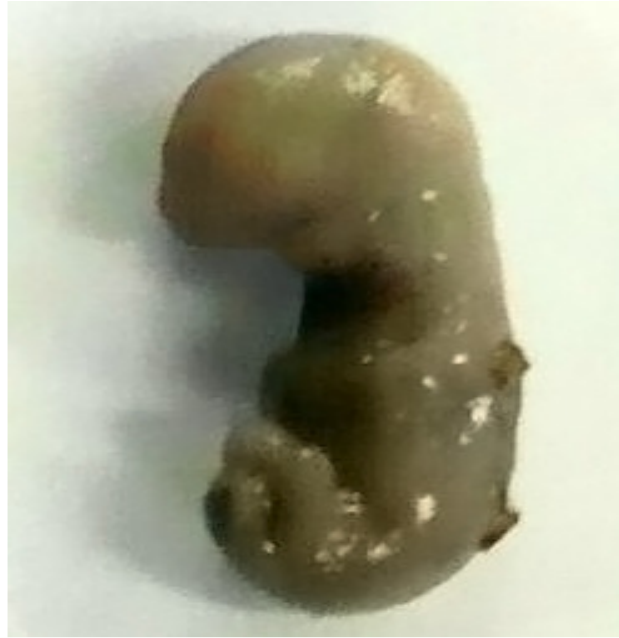

Figure 10. Dead embryo approximately at Theiler stage 15 to 19 obtained from a mother treated with 1 mg/ml *Ardisia pyramidalis* extract only, dissected at 16 dpc.

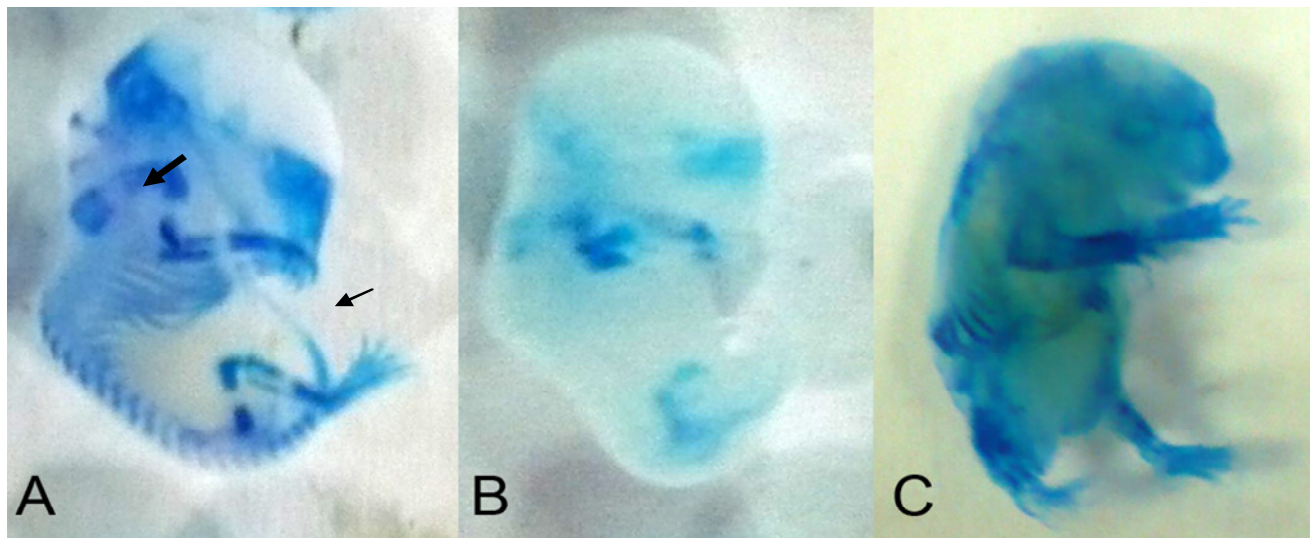


Figure 11. Lateral view of 16 dpc fetuses after Alcian Blue and Alizarin Red S double staining. (A) Cartilage stained blue (thin arrow) and ossification sites stained purple (thick arrow) in a fetus obtained from 10 mg/ml *A. pyramidalis* extract treatment. (B) A fetus from 12500 IU vitamin A treatment showed delay in chondrogenesis through the lack of blue stains, while (C) a fetus from 5 mg/ml *A. loheri* treatment shows an example of a fetus damaged during the process of staining.

fetuses from the other treatment groups did not succeed, due to the fragility of the fetuses and the damage they are susceptible to from the different chemicals involved in the staining procedure (Figure 11c). For these fetuses, the staining procedure was prolonged because they did not stain as readily as those from the positive control and

from the 5 mg/ml *A. loheri* treatment. It is possible that the unsuccessful staining for these treatment groups was due to the simple deficiency in cartilage and bone among these fetuses. However, there exists the possibility that there was not enough stain in the staining solution to accommodate the high number of fetuses from these

treatment groups to allow sufficient staining. To account for this possibility, the staining procedure was prolonged, but only resulted to damage among the fetuses.

DISCUSSION

Vitamin A and retinoids, its physical metabolites, including retinoic acid are required for normal embryo development, at sufficient levels. However, excess or insufficient amounts of this at the susceptible developmental stage are known to cause various defects on the developing embryo. Retinoic acid functions in the antero-posterior patterning in the embryo, but also effects a great inhibition on the inner cell mass, which may be responsible for the high rate of resorption among retinoic acid-treated mice (Gilbert, 2006; Huang et al., 2006). Malformations due to vitamin A include neural plate and hindbrain defects, limb deformations and inner ear deformations, among others (Huang et al., 2006). These malformations arise because vitamin A teratogenesis affects tissues derived from the cranial neural crest (Rothman et al., 1995).

It should be considered that maternal hypervitaminosis A has adverse effects not only to the developing embryo, but also to the mother. In a study by Moore and Wang (1945), daily oral treatment of vitamin A equivalent to 50,000 IU for four days, and subsequent daily treatment of 25,000 IU resulted to weakness in the legs of the treated rats by the 8th day, and eventually led to the formation of leg fractures. The drastic weight losses for the positive control mice in this study suggest that oral treatment with a lower concentration of vitamin A at 12,500 IU can still result to mouse hypervitaminosis A. Moore and Wang (1945) also cited previous similar work that reported observations of hair loss, as well as kidney, liver and heart degeneration and eventual death. These symptoms were not observed among the positive control mice, and would probably require higher doses or longer treatments with vitamin A in order to manifest.

However, the fact that substantial limb weakness, exaggerated spinal curvature and eventual death was only observed in mice treated with both 12500 IU vitamin A and 10 mg/ml *A. loheri* extract, and not in extract only and positive control setups, suggests the possibility that *A. loheri* extract, at this dosage, increases the susceptibility of mice to hypervitaminosis A. This is further supported by the weight record of mice, where weight loss in vitamin A + 10 mg/ml *A. loheri* extract treatment (33.52%) was higher than the sum of the weight losses in mice treated with vitamin A only (21.57%) and 10 mg/ml *A. loheri* only (5.01%). Hence, there may exist a synergistic action between vitamin A and the *A. loheri* extract, enhancing the effects of hypervitaminosis A, or lowering the threshold dose for the toxicity of vitamin A. The occurrence of an exaggerated spinal curvature and limb weakness among mice in this

treatment group can be attributed to vitamin A toxicity, as similar observations has been previously documented in cases of hypervitaminosis A, such as in dogs (Maddock et al., 1949).

Upon observation of hypervitaminosis A in treated mice, vitamin A dosage was accordingly decreased to 2500 IU in order to prevent maternal toxicity, as such might cause additional stress to the developing embryo. A decreased vitamin A dosage may also provide the plant extracts with an increased capacity to counteract the teratogenic action of vitamin A, if they indeed possess antiteratogenic potential. As such, vitamin A dosage was decreased by the 6th day of vitamin A + 5 mg/ml *A. loheri* extract treatment. In this treatment, there were no observed cases of limb weakness, spinal curvature or eventual death. Moreover, the observed weight loss was less than that observed from the positive control. Whether this is due to a decreased vitamin A dosage or a decreased plant extract concentration, and whether or not the synergistic action between the two still exists at these doses was not determined in this study.

Decreased liver pigmentation as observed in some of the mice treated with 10 mg/ml *A. pyramidalis*, with or without 2500 IU vitamin A, may be indicative of the occurrence of hepatotoxicity, although the frequency of such was only low in the experimental data (only one mouse for each treatment). This abnormality was not observed in the 1 mg/ml treatment, suggesting that its toxicity occurs only at higher concentrations. Moreover, the fact that depigmentation was more extensive in the extract + vitamin A treatment suggests that the hepatotoxicity of this dosage of *A. pyramidalis* is potentiated by combined treatment with vitamin A.

In this study, heavy uterine vascularization was used as evidence for the occurrence of pregnancy. Traditionally, the presence of uterine scars is used to confirm pregnancy, but such were not observed in this study. Strictly speaking, uterine scars, also called placental scars, represent the sites of implantation of the embryos in the uterine wall. Implantation is said to begin at the 6th Theiler stage of mouse embryonic development, which is roughly at around 4.5 dpc (Nagy et al., 2003). At this stage, the implanted blastocyst differentiates, eventually leading to the penetration of the trophoblast through the uterine epithelium into the maternal capillaries for the nourishment of the embryo (Purcell et al., 1999). Given the fact that administration of different treatments started at 8 dpc, when the ectoplacental cone is starting to be filled with maternal blood and almost 4 days after supposed implantation, it then puts into question the non-occurrence of placental scars among mice dissected at 16 dpc showing heavy uterine vascularization. Nevertheless, the progression of uterine vascularization is still a good indication of the occurrence of pregnancy, despite the failure to observe artifacts of implantation sites. This is because the formation of the decidua is associated with the induction of angiogenesis, resulting to

an increase in the number and diameter of maternal vessels to supply the growing fetus. In fact, the success of implantation greatly relies on the proper regulation of angiogenesis, and an accurate detection of pregnancy has been achieved in other studies by as early as 4.5 dpc by MRI analysis of angiogenesis (Plaks et al., 2006). The most probable scenario that may have occurred to explain why no placental scars were observed upon dissection is that resorptions in these cases may have occurred during the first days of the treatment period. An early onset of teratogenic insult may lead to the termination of embryonic development while the decidua is still forming. Placental scars eventually do disappear over time through the digestion of macrophages and other endocytic cells in order to repair the uterine wall (Stewart and Mitchell, 1992). It is then logical that decidua that is only partially formed will be easier for macrophages to digest, such that dissection at the 16th day is enough time for the disappearance of the placental scars. This then further suggests the rapid action of the teratogens of concern in this study in the form of vitamin A or any compound in the plant extracts, or the high susceptibility of the embryo to toxicity from these foreign substances at the concentration administered, especially during the first days of treatment when the all or none response may still be in effect. Additionally, since both plant extracts have been shown to possess some degree of toxicity, they may have also caused toxicity to the uterus itself, further adding difficulty to the detection of placental scars.

The first day of administration of the different treatments is at 8 dpc, when the embryo is expected to be at Theiler stage 12 characterized by the occurrence of the neural folds and the formation of the anterior-most somites (Nagy et al., 2003). At this point, the developing embryo is still very sensitive and susceptible to the action of foreign substances, and may still be encompassed by the resistant period of embryonic development. The exposure of the embryo to the extract of *A. loheri*, which quite possibly possesses insecticidal action similar to many other species under the same genus, can result to the termination of embryonic development, following the all or none effect. The genus *Aglaia* is a known source of many insecticidal compounds, such as cycloartane-type triterpenoids as well as rocaglamide and its derivatives (Simanjuntak et al., 1999; Duong, 2005). Interestingly, rocaglamide has been shown experimentally to inhibit the activity of nuclear factor-kappa B (NF- κ B). NF- κ B is important not only in the innate immune response, but also in embryonic development (Baumann et al., 2002). In particular, NF- κ B activation is prominent in the developing central nervous system, brain roof and floor plates, epithelial structures and vasculature (Dickson et al., 2004). NF- κ B is also important in the cell cycle process, especially in the regulation of cyclin D1 expression, which is important in the cell proliferation process involved in embryonic development (Baumann et

al., 2002). It might then be possible that the teratogenicity of *A. loheri* is due to the NF- κ B-inhibiting activity of its rocaglamides.

The dose-dependence of the effects of treatment with extracts of *A. loheri* was also shown in this study with a higher concentration (10 mg/ml) resulting to 100% resorption, and a lower concentration (5 mg/ml) allowing one out of four treated mice to bear 11 live fetuses. Aside from teratogenicity, maternal toxicity also decreased with the dose of *A. loheri* extract administered, as shown in the weight record of mice subjected to these treatments.

For *A. pyramidalis*, the % morphological abnormality for extract treatments, with or without vitamin A, being significantly lower than the positive control, suggests some degree of protective action from vitamin A-induced teratogenicity. However, results also showed that combining vitamin A treatment with a low dose of this extract at 1 mg/ml effects a high rate of resorption (100%). How a high frequency of resorption might occur at low extract concentration + vitamin A treatment, but not occur for treatment with 10 mg/ml concentration with vitamin A may further indicate a dose-dependent protective action of *A. pyramidalis* against vitamin A. At the same time, *A. pyramidalis* may itself have its own teratogenicity, as seen in extract only treatments that is also dose-dependent. In fact, previous works have documented cytotoxic effects of ardisenone, a phenol from a relative species *A. iwahigensis*, also found in the Philippines (Calderon et al., 2000). This compound may also be present in *A. pyramidalis*, and be responsible for the observed teratogenic effects in this study. The insecticidal activity of a compound, $C_{49}H_{75}N_7O_{15}$, from a related species, *A. crenata*, against mosquitos and houseflies may further suggest a toxicity conferred by this plant (Khan, 1991).

Conclusions

Both *A. pyramidalis* and *A. loheri* leaf extracts showed some degree of teratogenicity in ICR mice. Further, *A. loheri* extract may even have a synergistic action with vitamin A, enhancing its toxicity. On the other hand, *A. pyramidalis* may possess some degree of protective action against vitamin A-induced malformations, but may have its own teratogenicity as well. Treatment with *A. pyramidalis* also resulted to hepatotoxicity when administered at a 10 mg/mL concentration. The use of extracts of both plants for medical purposes should therefore be limited until sufficient safety testing is under taken, given the fact that both might possess certain insecticidal activity, and as shown in this study, teratogenic potential. Although both plants are rich in bioactive compounds with many potential biomedical applications, caution should still be taken during intake of these extracts, especially during the delicate period of pregnancy.

RECOMMENDATIONS

More replicates per treatment may be performed in order to decrease the standard error obtained for the different indices. In addition, laboratory conditions may still be further improved. Prolonged noise from construction prevented the mating of mice due to disturbance, while light conditions were not optimal for all workspaces in the laboratory. Further, future studies on this plant may also involve fractionation of the crude extract, which may potentially separate teratogenic and toxic compounds from compounds that are safe and with antiteratogenic action. The use of generous volumes of staining solutions during the staining procedure may also prevent future failures in the staining process. The experience from this study suggests that ten fetuses should be stained using no less than 40 ml solution for each of the steps in the staining procedure.

ACKNOWLEDGEMENTS

The authors thank the University of the Philippines System Creative and Research Scholarship Program and the Natural Sciences Research Institute for the research grant, the Institute of Biology, College of Science for the use of facilities and Dr. Lourdes Cruz of the Marine Science Institute, University of the Philippines for the collaboration in the use of plants from Barangay Kanawan, Morong, Bataan, Philippines.

REFERENCES

- Baumann B, Bohnenstengel F, Siegmund D, Wajant H, Weber C, Herr I, Debatin KM, Proksch P, Wirth T (2002). Rocaglamide derivatives are potent inhibitors of NF- κ B activation in T cells. *J. Biol. Chem.*, 277(47): 44791-44800.
- Brent RL, Fawcett LB (2004). Environmental causes of human congenital malformations: the pediatrician's role in dealing with these complex clinical problems caused by a multiplicity of environmental and genetic factors. *Pediatrics*, 113: 957-968.
- Calderon AI, Angerhofer CK, Pezzuto JM, Farnsworth NR, Foster R, Condit R, Gupta MP, Soejarto DD (2000). Forest plot as a tool to demonstrate the pharmaceutical potential of plants in a tropical forest of Panama. *Econ. Bot.*, 54(3): 278-294.
- Chiang LC, Cheng HY, Liu MC, Chiang W, Lin CC (2003). *In vitro* anti-herpes simplex viruses and anti-adenoviruses activity of twelve traditionally used medicinal plants in Taiwan. *Biol. Pharm. Bull.*, 26(11): 1600-1604.
- Choudhury S, Sree A, Mukhurjee SC, Pattnaik P, Bapuji M (2005). *In vitro* antibacterial activity of extracts of selected marine algae and mangroves against fish pathogens. *Asian Fish. Sci.*, 18: 285-294.
- Dickson KM, Bhakar AL, Barker PA (2004). TRAF6-Dependent NF- κ B transcriptional activity during mouse development. *Dev. Dyn.*, 231: 122-127.
- Duong NT (2005). Isolation and structure elucidation of insecticidal secondary metabolites from *Aglaia* species collected in Vietnam. PhD Pharmaceutical Biology and Biotechnology dissertation. Heinrich Heine University, Düsseldorf, Germany.
- Gilbert SF (2006). Medical implications of developmental biology In: *Developmental Biology*. Sinauer Associates, 8th Ed.
- Huang FJ, Hsuuw YD, Lan KC, Kang HY, Chang SY, Hsu YC, Huang KE (2006). Adverse effects of retinoic acid on embryo development and the selective expression of retinoic acid receptors in mouse blastocysts. *Hum. Reprod.*, 21(1): 202-209.
- Khan MTJ (1991). Investigations on the isolates and derivatives of plant antimicrobials. PhD Pharmaceutical Chemistry dissertation. University of the Punjab, Lahore, Pakistan.
- Lo WY, Friedman JM (2002). Teratogenicity of recently introduced medications in human pregnancy. *Obstet. Gynecol.*, 100: 465-473.
- Maddock CL, Wolbach SB, Maddock S (1949). Hypervitaminosis A in the dog. *J. Nutr.*, 39(1): 117.
- Moore T, Wang YL (1945). Hypervitaminosis A. *Biochem. J.*, 39: 222-228.
- Nagy A, Gertsenstein M, Vintersten K, Behringer R (2003). Manipulating the mouse embryo: a laboratory manual. CSHL Press 3rd Ed., P. 36.
- Noor RA, Khozirah S, Mohd RMAR, Ong BK, Rohaya C, Rosilawati M, Hamdino I, Badrul A, Zakiah I (2007). Antiplasmodial properties of some Malaysian medicinal plants. *Trop. Biomed.*, 24(1): 29-35.
- Plaks V, Kalchenko V, Dekel N, Neeman M (2006). MRI analysis of angiogenesis during mouse embryo implantation. *Magn. Reson. Med.*, 55: 1013-1022.
- Purcell TL, Given R, Chwalisz K, Garfield RE (1999). Nitric oxide synthase distribution during implantation in the mouse. *Mol. Hum. Reprod.*, 5(5): 467-475.
- Rothman KJ, Moore LL, Singer MR, Nguyen UDT, Mannino S, Milunsky A (1995). Teratogenicity of high vitamin A intake. *New Engl. J. Med.*, 333(21): 1369-1370.
- Simanjuntak P, Parwati T, Rachmat J, Soeksmanto A (1999). Screening of some Indonesian *Aglaia* spp. plants for their insecticidal potential by brine shrimp lethality test (BSLT). *Ann. Bogor.*, 6(1): 61-70.
- Singh IP, Bharate SB, Bhutani KK (2005). Anti-HIV natural products. *Curr. Sci.*, 89(2): 269-290.
- Stewart IJ, Mitchell BS (1992). Macrophages and other endocytic cells in the mouse uterus during the second half of pregnancy and into the postpartum period. *J. Anat.*, 181: 119-126.
- Sumino M, Sekine T, Ruangrunsi N, Igarashi K, Ikegami F (2002). Ardisiphenols and other antioxidant principles from the fruits of *Ardisia colorata*. *Chem. Pharm. Bull.*, 50(11): 1484-1487.
- Watanabe T, Kohzuma S, Takeuchi T, Otsuka M, Umezawa K (1998). Total synthesis of (\pm)-aglaiaastatin, a novel bioactive alkaloid. *Chem. Commun.*, 10: 1097-1098.