

Full Length Research Paper

Blood glucose and morphology of the liver and pancreas in garlic –fed Wistar rats

Ebomoyi, Maureen Isoken* and Abuda, Onobu

Department of Physiology, School of Basic Medical Sciences, College of Medical Sciences, University of Benin, Benin City, Edo State, Nigeria.

Accepted 2 August, 2010

The effect of aqueous fresh garlic (*Allium sativum*) cloves extracts on blood glucose level and on the morphology of liver and pancreas of Wistar rats was determined. Four groups of 5 each of preweighed male and female (controls) as well as 5 each of male and female experimental Wistar albino rats were administered with 500 mg/kg body weight of extracts for 12 weeks and blood glucose analysis was done after a 10 h fast before and at the 3rd, 6th, 9th and 12th week of garlic administration and the liver and pancreas were also taken for histological analysis. Results showed that at the end of the 3rd and 6th week of garlic administration, there was a slight decrease in blood glucose levels in both the male and female rats, and at the end of the 9th and 12th week, there was a very significant decrease in the blood glucose levels of both the male and female garlic-fed rats. There were morphological changes in the liver and pancreas of the garlic-fed rats. The results suggest that chronic garlic feeding decreases blood glucose level.

Key words: Garlic, blood glucose level, liver, pancreas.

INTRODUCTION

The healthful properties of garlic are legion, and have been identified and validated for over thousands of years and in many scientific report this last decade. Some of these studies have indicated that garlic possesses cholesterol reduction, anticoagulative, antihypertensive, hepatoprotective and hypoglycemic properties (Yuriko et al., 2001; Chetty et al., 2003; Thomson et al., 2000; Kalantari and Salahi, 2001; Thomson et al., 2006). It has also been found to reduce lead acetate (Senapati et al., 2001; Pourjafar et al., 2007). Garlic metabolites such as diallyl trisulfide have been reported to have spermicidal effects (Chakrabarti et al., 2003). Many traditional plant treatments for diabetes are also used, but most of the evidence for their beneficial effects is anecdotal (Bailey and Day, 1989). The plant was reported to have a hypoglycemic (Sharma and Raghuram, 1990) and antidiabetic (Eidi et al., 2006) effects. Although garlic and other herbal medicines have long been used effectively in treating many diseases in various communities

throughout the world, the mechanism of most of the herbals has not been defined (Jelodar et al., 2005). Garlic may act on blood glucose through different mechanisms - It may have insulin-like substances (Colier et al., 1987); it may inhibit insulinase activity (Bhide and Aiman, 1963); it may enhance insulin secretion (Liu et al., 2005; Eidi et al., 2006); it may increase beta cells in the pancreas by activating regeneration of these cells (Shanmugasundaram et al., 1990; Abdel et al., 1997); the fiber of the plant may also interfere with carbohydrate absorption, thereby affecting blood glucose (Nelson et al., 1991). Garlic has been found to increase the glycogen content of the liver (Meiling and Margaret, 1980).

Literature is scanty on the effect of garlic on glucose level and on the morphology of liver and pancreas tissues. The study therefore assessed the effect of garlic on blood glucose level and morphology of the liver and pancreas in rats.

MATERIALS AND METHODS

Source of garlic and rat specimens

Local cultivar of garlic (*Allium sativum*) was purchased

*Corresponding author. E-mail: maureenebomoyi@yahoo.com.
Tel: 080233396807.

Table 1. Blood glucose levels (mg/dl) of the various groups of rats.

	Group 1A Blood glucose (Mean ± SEM)	Group 2A Blood glucose (Mean ± SEM)	Group 1B Blood glucose (Mean ± SEM)	Group 2B Blood glucose (Mean ± SEM)
Week 3	67.20 ± 1.16	62.00 ± 2.35	59.60 ± 2.69	56.60 ± 3.28
Week 6	68.60 ± 2.66	59.60 ± 3.34	62.20 ± 2.84	54.20 ± 3.56
Week 9	70.20 ± 2.87	57.60 ± 2.29	66.40 ± 2.11	54.80 ± 1.99
Week 12	77.60 ± 6.01	60.20 ± 3.96	70.40 ± 2.94	53.60 ± 2.65

from the local market and it was authenticated by a professor at the Botany Department, University of Benin where a sample was deposited at the herbarium of that department. The garlic sample was hand-peeled and sun-dried for 6 h and then stored for further use.

Twenty adult Wistar albino rats (weighing 150 - 160 g) obtained from the Animal House of the Faculty of Pharmacy, University of Benin, were used for the study. The rats were housed in wooden cages in the animal house of the Department of Anatomy, University of Benin, and allowed to acclimatize for a period of two weeks prior to the study.

Preparation of plant sample and extraction of bioactive components

The dried garlic cloves (320 g) were crushed with mortar and pestle and then weighed. The crushed garlic was exposed to air for 10 - 15 min so that there was conversion of alliin to allicin by the enzyme allinase. The crushed garlic was then mixed with 320ml distilled water and left for 24 h to macerate (Lachance, 1997). The resulting mixture was filtered and the filtrate was concentrated by evaporation in a water bath to obtain a chocolate-coloured syrup extract, weighing 180 g. The extract so obtained was used for blood glucose experiment. The experiments were repeated in triplicates and results were recorded as mean values.

Effect of garlic extracts on blood glucose level and morphology of liver and pancreas

The rats were divided into 4 groups of 5 each; Groups 1A and 1B each with 5 male or female rats respectively serving as controls, and Groups 2A and 2B each with 5 male or female rats respectively serving as the experimental groups. Food and water was given to the animals *ad libitum* during the acclimatization period and throughout the 12 weeks of the experiment. Prior to the study, the rats were weighed, and then they were administered with garlic (500 mg/kg body weight) every morning at 10.00 am for 12 weeks using an orogastric tube (Ezeala et al., 2009).

The rats' blood glucose was analyzed every 3 weeks throughout the experimental period. Blood (0.5 ml) was collected from the tail of each of the rats after a 10 h fast and blood glucose was then analyzed using a blood glucose analyzer (Tang et al., 2000). At the end of 12 weeks, the animals were weighed again after which they were sacrificed and their abdominal cavities were opened in order to isolate their livers and pancreas. Each of the extracted liver and pancreas was fixed in a 10% formaldehyde solution (1 part of tissue to 10 parts of fixative), and then taken for histological analysis.

All data were expressed as means ± standard error of mean. The student t - test was used to compare the differences between the groups, and P values less than 0.05 ($p < 0.05$) were taken as statistically significant. All analyses were done with SPSS statistical package and graphs were plotted using micro cal origin 5.0 software.

RESULTS

Table 1 shows the effect of garlic extracts on rat blood glucose level. Results showed that there were slight decreases in blood glucose levels of the male experimental (Group 2A) compared to the male control (Group 1A) rats ($P < 0.05$) after the 3rd and 6th weeks of extract treatment. The blood glucose levels of the experimental rats further decreased significantly ($P < 0.05$) compared to the control rats for both the male and the female groups. Results also showed a significant increase in the weights of all the rats at the end of the 12th week, compared to their weights at the beginning of the study (Table 2).

Figures 1 and 2 shows the livers of the control male (group 1A) and the control female (group 1B) rats, while Figures 3 and 4 shows the livers of the experimental male (group 2A) and the experimental female (group 2B) rats. The sections of the livers of the experimental rats showed vascular events evidenced by portal and sinusoidal congestion, and mild periportal chronic inflammation. Results also showed that there was increased blood flow in the liver, as well as mild chronic inflammation.

Figures 5 and 6 shows the pancreas of the control male (group 1A) and the control female (group 1B) rats, while Figures 7 and 8 shows the pancreas of the experimental male (group 2A) and the experimental female (group 2B) rats. In Figure 7 results showed that vascular changes including congestion hypertrophy, dilatation as well as mild infiltrates of chronic inflammatory cells occurred in the pancreas. Figure 8 revealed vascular changes which included moderate congestion, hypertrophy, dilatation which involved the interstitial space and the Islets of Langerhans.

DISCUSSION

The significant fall in rat blood glucose levels at the end of the 3- 6 or 9- 12th weeks of study is consistent with earlier reports that oral administration of garlic extract significantly decreased blood glucose levels (Jelodar et al., 2005; Eidi et al., 2009). Garlic may have insulin-like properties (Bailey and Day, 1989) and therefore directly reduce blood glucose levels by stimulating glycogenesis and inhibiting gluconeogenesis and glycogenolysis in

Table 2. Body weights (gms) of the various groups of rats at the beginning (week 0) and at the end (week 12) of the experiment.

	Group 1A Body weight (kg) (Mean ± SEM)	Group 2A Body weight (kg) (Mean ± SEM)	Group 1B Body weight (kg) (Mean ± SEM)	Group 2B Body weight (kg) (Mean ± SEM)
Week 0	151.80 ± 1.00	151.00 ± 1.87	151.20 ± 3.96	152.00 ± 1.02
Week 12	232.00 ± 9.17	233.00 ± 11.36	231.00 ± 5.10	240.00 ± 7.35

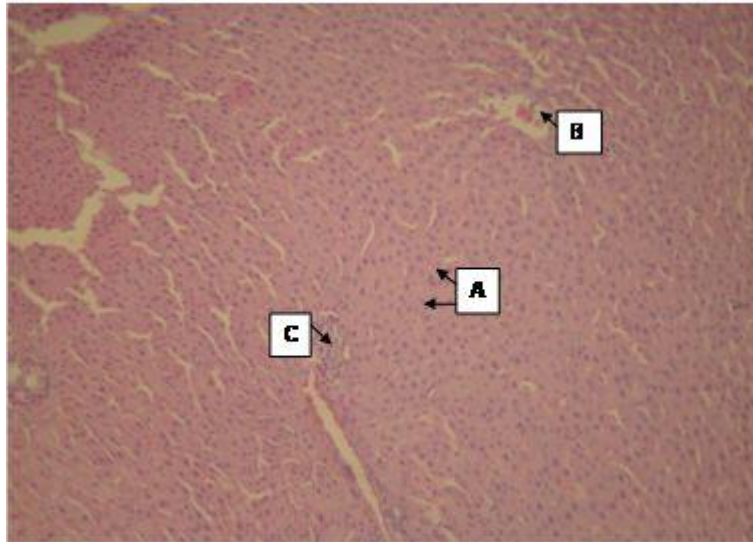


Figure 1. Male control rat liver showing hepatocytes (A), central Vein (B) and portal Triad (C) [H and E x4].

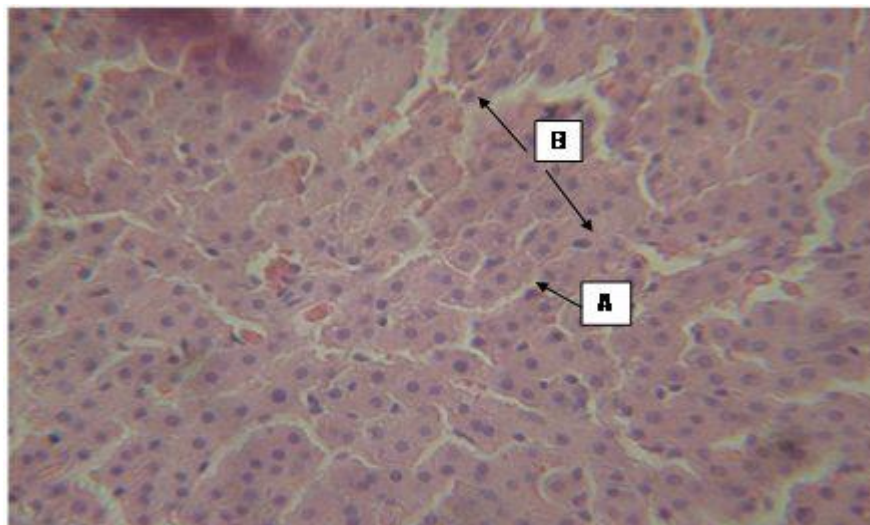


Figure 2. Female control rat liver showing hepatocytes (A), sinusoid (B) [H and E x 4].

hepatic and muscle cells; it may increase beta cells in the pancreas by activating regeneration of these cells (Shanmugasundaram et al., 1990), or the fiber of the

plant may also interfere with carbohydrate absorption, thereby affecting blood glucose (Nelson et al., 1991). The body weights of rats in both the control and the

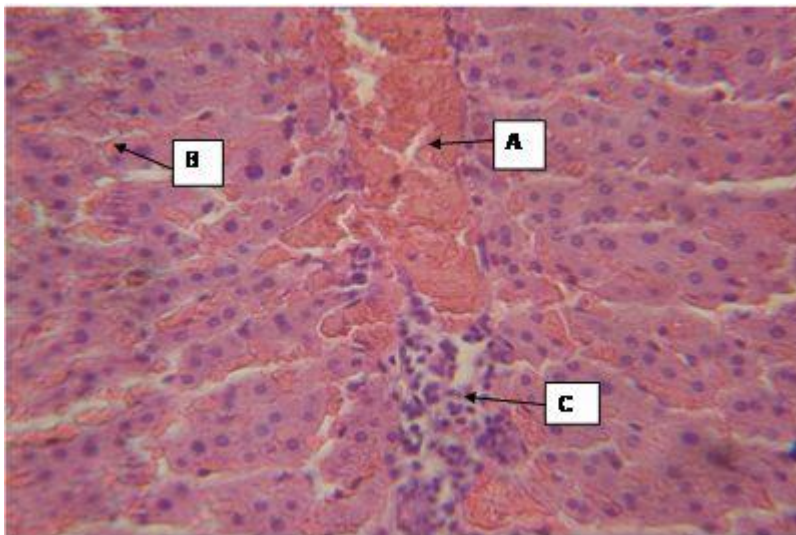


Figure 3. Male garlic-fed rat liver, showing moderate portal (A) and sinusoidal (B) congestion and mild periportal infiltrates of chronic inflammatory cells (C). (H and E x 10).

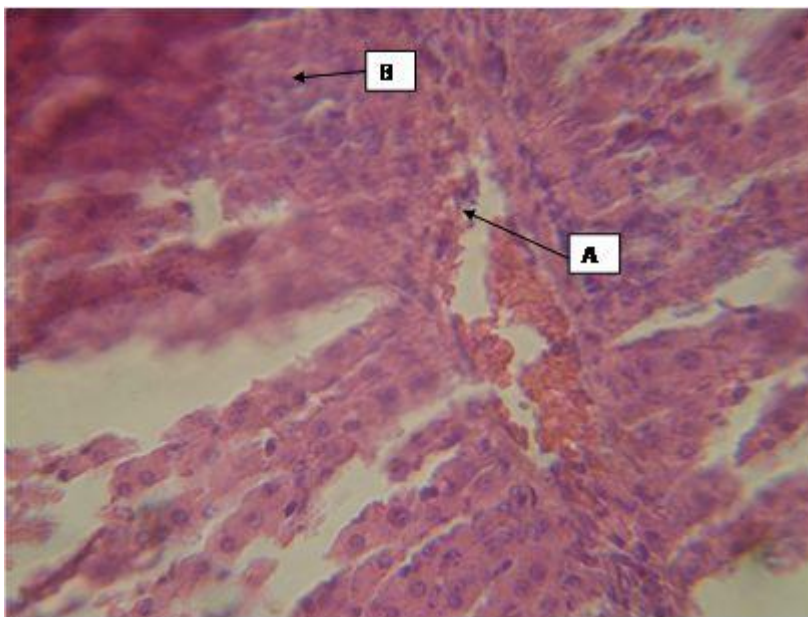


Figure 4. Female garlic – fed rat liver, showing mild portal congestion (A) and mild periportal infiltrates of chronic inflammatory cells (B) (H and E x 10).

experimental groups increased at the end of the 12th week of study compared to the controls. This shows that garlic administration did not affect body weight in the rats. The observed increase in their body weights at the end of the study was due to normal growth.

The histological sections of the liver of both the male and female experimental rats showed vascular events associated with increased blood flow in the liver, as well

as mild chronic inflammation. This implied that at that dosage and duration of administration of garlic, the liver cells would take up more glucose for conversion to glycogen, thus resulting in further fall in blood glucose level. This observation was in agreement with that of Meiling and Margaret (1980).

The histological sections of the pancreas of both the male and female experimental rats showed vascular

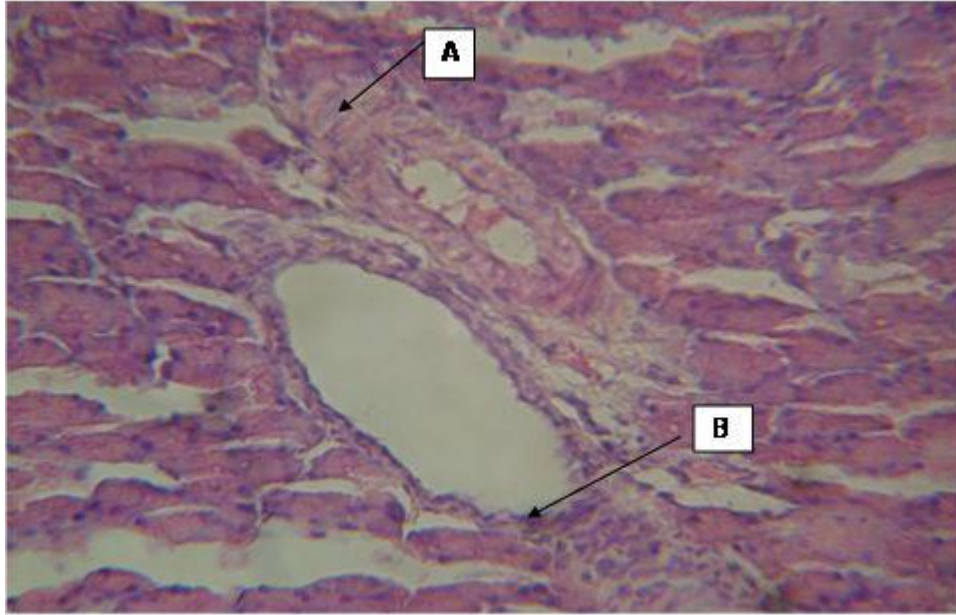

Figure 7. Male garlic – fed rat pancreas, showing Interstitial vascular hypertrophy and dilatation (A) and mild infiltrates of chronic inflammatory cells (B) (H and E x10).

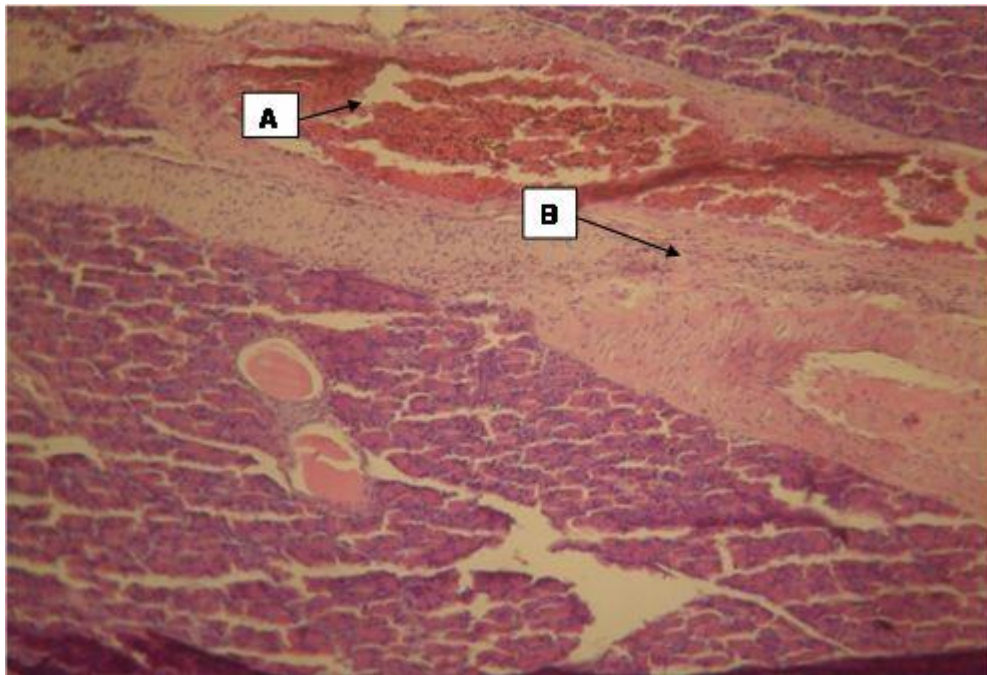


Figure 8. Female garlic – fed rat pancreas showing moderate interstitial congestion (A) and vascular hypertrophy (B) and congestion around the endocrine (C) (H and E x 4).

changes as well, including congestion, hypertrophy, dilatation as well as mild infiltrates of chronic inflammatory cells, in addition to dilatation involving the interstitial space and the Islets of Langerhans in the female rats. This could have been due to the activation of

the local immune system. These findings showed that garlic administration increased blood flow to the endocrine and exocrine pancreas, and thereby possibly increasing the transport of insulin through the bloodstream to its target tissues. This would ultimately

result in a lowering of the blood glucose level.

Conclusion

The administration of garlic to rats in this study reduced blood glucose levels, and caused vascular changes in their liver and the pancreas associated with increased blood flow in these tissues that would ultimately cause increased delivery of metabolites (e.g. glucose) and hormones to the tissues. This would suggest that there could be increased movement of insulin from the pancreatic Islet cells by the bloodstream and increased deposition of glycogen in the liver. However, future studies involving diabetic rats would throw more light as to the exact mechanism of action of garlic.

REFERENCES

- Abdel MA, El-feki M, Sarah E (1997). Effect of Nigella Sativa, fish oil and glyclazide on alloxan diabetic rats, 1-biochemical and histopathological studies. *J. Zoo.*, 23: 237-265.
- Bailey CJ, Day C (1989). Traditional treatment of diabetes. *Diab. Care.*, 12: 553-564.
- Bhide MB, Aiman R (1963). Mechanism of action of oral antidiabetic drugs. *Ind. J. Med. Res.*, 51: 733.
- Chetty KN, Calahan L, Harris KC, Dorsey W, Hill D, Chetty S, Jain SK (2003). Garlic attenuates hypercholesterolemic risk factors in olive oil fed rats and high cholesterol fed rats. *Pathophysiol.*, 9: 127-132.
- Collier E, Watkinson A, Cleland CF, Roth J (1987). Partial purification and characterization of an insulin-like material from spinach and lemna gibba G3. *J. Biol. Chem.*, 262: 6238-6247.
- Ezeala CC, Nweke W, Unekwe PC, El safty IA, Nwaegerue E (2009). Fresh garlic extract protects the liver against Acetaminophen-induced toxicity. *J. Nutr.*, 7(1): 205.
- Eidi A, Eidi M, Esmaeili E (2006). Antidiabetic effect of garlic (*Allium sativum*) in normal and streptozotocin-induced diabetic rats. *Phytomed.*, 13(9): 624-629.
- Jelodar GA, Maleki M, Motadayen MH, Sirus S (2005). Effect of Fenugreek, Onion and Garlic on blood glucose and histopathology of pancreas of alloxan- induced diabetic rats. *Ind. J. Med. Sci.*, 59: 64-69.
- Kalantari H, Salahi M (2001). The protective effect of garlic oil on hepatotoxicity induced by acetaminophen in mice and comparison with N-acetyl cysteine. *Saudi Med. J.*, 22(12): 1080-1084.
- Lachance PA (1997). Designer foods III: Garlic, Soy, and Licorice. Nutr. Press Trumbull, CT.
- Liu CT, Hse H, Lii CK, Chen P, Sheen LY (2005). Effects of garlic oil and diallyl trisulfide on glycemic control in diabetic rats. *Eur. J. Pharmacol.*, 5(6): 165-173.
- Meiling WC, Margaret AJ (1980). Effect of Garlic on carbohydrate metabolism and lipid synthesis. *J. Nutr.*, 110: 931- 936.
- Nelson RW, Ihie SL, Lewis LD, Salisbury SK, Bottoms GD (1991). Effects of dietary fibre supplementation on glycemic control in dogs with alloxan induced diabetes mellitus. *Am. J. Vet. Res.*, 52: 2060-2066.
- Pourjafar M, Aghobolaghi PA, Shakhse NM (2007). Effect of garlic along with lead acetate administration on lead burden of some tissues in mice. *Pakistan J. Bios.*, 10(16): 2772-2774.
- Senapati SK, Dey S, Dwivedi SK, Swarup D (2001). Effect of garlic (*Allium Sativum*) extract on tissues lead level in rats. *J. Ethnopharm.*, 76: 229-232.
- Shanmugasundaram ER, Gopith KL, Radha SK, Rajendran VM (1990). Possible regeneration of the islets of Langerhans in streptozotocin-diabetic rats given gymnema sylvestere leaf extract. *J. Ethnopharm.*, 30: 265-269.
- Sharma RD, Raghuram TC (1990). Effect of fenugreek seeds on blood glucose and serum lipids in type 1 diabetes. *Eur. J. Clin. Nutr.*, 44: 301-309.
- Tang Z, Du X, Lowie RF, Kost GJ (2000). Effects of drugs on glucose measurement with hand held glucometers and a portable glucose analyzer. *Am. J. Clin. Pathol.*, 113: 75-86.
- Thomson M, Khaled KA, Tanuja B, Muslim A (2006). Significance of garlic and its constituents in cancer and cardiovascular Disease. *J. Nutr.*, 136(5): 800-802.
- Thomson M, Mustafa T, Ali M (2000). Thromboxane B₂ levels in serum of rabbits receiving a single intravenous extract of garlic and onion. *Prostag. leukot. Essent. Fatty acids.*, 63: 217-221.
- Yuriko O, Mika I, Chiaka S, Yutako K, Syoji N, Kazuo I (2001). Garlic supplementation increases testicular testosterone and decreases plasma corticosterone in rats fed a high protein diet. *Biosci. Rep.*, 21: 19-24.