

*Full Length Research Paper*

# 'Naobitong' reduces hyperalgesia, decreases interleukin-6 level and ameliorates inflamed joint in arthritic rats

Shan Gong<sup>1#</sup>, Qian Liang<sup>1#</sup>, Chiyi Kwok<sup>2</sup>, Zhenlun Gu<sup>2</sup>, Jin Tao<sup>1</sup> and Xinghong Jiang<sup>1\*</sup>

<sup>1</sup>Department of Neurobiology, Key Laboratory of Pain Research and Therapy, Medical College of Soochow University, Suzhou 215123, P. R. China.

<sup>2</sup>Suzhou Institute of Chinese Materia Medica, Medical College of Soochow University, Suzhou 215123, P. R. China.

Accepted 9 June, 2011

**This study was to investigate the effects of Chinese medicinal compound 'Naobitong' (NBT) on hyperalgesia, serum interleukin-6 (IL-6) level, histo-pathological changes and X-ray images of inflamed joint in adjuvant-induced arthritic rats. Monoarthritic model was induced by intra-articular (tibio-tarsal joint) injection of complete Freund's adjuvant (CFA). Aspirin (100 mg/kg) and normal saline were used as positive and negative control, respectively. Hyperalgesia was measured by paw pressure-withdrawal test. ELISA analysis was used to detect the serum IL-6 level. Conventional methods were used to examine the histo-pathological changes and to take the X-ray images of inflamed joint. Our results showed that NBT could significantly attenuate the hyperalgesia during 6 week period of treatment. In addition, NBT robustly decreased the serum IL-6 level and significantly ameliorated the histo-pathological changes, as well as the X-ray images of inflamed joint. Our results suggested that NBT played antihyperalgesic and probably, some anti-inflammatory roles for adjuvant-induced arthritis in rats.**

**Key words:** Naobitong (NBT), hyperalgesia, interleukin-6, adjuvant-induced arthritis.

## INTRODUCTION

It is widely accepted recently that chronic pain is a disease, whose etiology and pathogenesis are very complicated. Clinical practices indicate that although currently existing analgesic drugs such as morphine can give some alleviative effect for chronic pain, their use is limited because they produce severe adverse effects including respiratory depression, constipation and addiction. The use of traditional Chinese medicine (TCM) and herbal medicaments to treat different pain syndromes has a long lasting history and many experiences have been accumulated in this field. Growing evidence demonstrated that TCM and natural herbal drugs in the pain therapy are characterized by better pharmacological effects, no addiction and less adverse effects, and

therefore become an important source for the research and development of new analgesic drugs (Zhou et al., 2007). 'Naobitong' (also named 'Braitone', NBT) is a compound made of extracts from San-qi (radix notoginseng), Chuan-xiong (rhizoma chuanxiong), Hong-jing-tian (radix rhodiolae) and leaves of Ginkgo (Folium ginkgo).

It is produced by Herbs Products Ltd (Winsor Health Products Ltd., Hong Kong, China). Functionally, this compound has the ability to support healthy circulation to the brain and maintain healthy blood vessel tone and memory. Moreover, preliminary pharmacological studies have demonstrated that this compound elicited analgesic effect on acute hotplate test and writhing test in mice (Zhang et al., 2004). However, whether this compound could work in the pathological conditions especially in inflammatory pain remains still unknown. In this study we examined the analgesic effect of NBT using monoarthritic model induced by complete Freund's adjuvant (CFA). Meanwhile, the serum interleukin-6 level and the pathomorphological changes of inflamed joint were also

\*Corresponding author. E-mail: [jiangxinghong@suda.edu.cn](mailto:jiangxinghong@suda.edu.cn).  
Tel: +86-512-65880126. Fax: +86-512-65880397.

#These authors contribute to this work equally.

detected in order to analyze the mechanism of analgesic effect of this compound.

## MATERIALS AND METHODS

### Animals and drugs

Adult Sprague-Dawley (SD) rats of both sexes, weighing  $189 \pm 13$  g at the beginning of experiments, were used in this study. The animals were provided by the Experimental Animal Center, Medical College of Soochow University. All of the methods used in this study were approved by the animal care and use committee, Soochow University and conformed to the ethical guidelines of the International Association for the Study of Pain (Zimmermann, 1983). All the rats were acclimated to the experiment environment and experimental manipulations for 3 days.

### Induction of monoarthritis

Monoarthritis was induced using the method described previously (Butler et al., 1992; Liu et al., 1996). Animals were anesthetized with 4% chloral hydrate and the complete Freund's adjuvant (CFA) containing heat-killed *Mycobacterium tuberculosis* (Shanghai Institute of Biological Products, lot No. 200703001) suspended in sterile mineral oil (5 g/L) was injected intra-articularly into the ankle (tibio-tarsal) joint of the right hindpaw at a volume of 0.03 ml. Fourteen hours after injection, CFA-injected joint developed the symptoms of local inflammation as evidenced by redness, swelling and movement disorders (elevation or licking of the injected paw), as well as hyperalgesia (decreases the pain threshold). From the second day after CFA injection animals were divided randomly into several groups and began to receive drug administration.

### Animal grouping

All the arthritic rats were divided into 5 groups (7 to 9 rats in each group): 1) group treated with high dose of NBT (Herbs Products Ltd, Hong Kong, lot No 3GB081021) (350 mg/kg), 2) group treated with middle dose (175 mg/kg), 3) group treated with low dose (87.5 mg/kg), 4) group treated with aspirin (Suzhou Pharmaceutical Co. lot No. BTA6NX1) (100 mg/kg) as positive control and 5) group treated with normal saline as negative control. All the drugs were dissolved in normal saline and given intra-gastrically (i.g.) once daily at a volume of 1 ml/100 g for 6 consecutive weeks.

### Measurement of pain threshold

The Randall-Selitto method was adopted to evaluate mechanical hyperalgesia in arthritic animals by using Analgesy-meter (Ugo Basile, Italy). A graded mechanical force in gram was delivered onto the convex surface of the inflamed paw and the paw withdrawal behavior was taken as pain threshold. The threshold was tested three times and the mean value was applied to analyze. The less force the animal tolerates, the more become the hyperalgesia. The measurement of pain threshold was performed before and during the treatment with NBT every 2 weeks.

### Detection of serum IL-6 level

After 6 week period of treatment animals were anesthetized. Blood samples were obtained from the heart and centrifuged at 3000 r/min for 10 min to isolate the serum, which was stored at  $-20^{\circ}\text{C}$  until the cytokine assay. The concentration of IL-6 in serum was determined

using enzyme-linked immunosorbent assay (ELISA) kits (Shanghai Xi-Tang Biological Science Technology Co. Ltd, lot No.0803283) the manufacturer's instruction on enzyme-linked immuno-detector (East China Electronics Co. China).

### Histological processing

At the end of whole experiment, two rats were taken randomly from each group, sacrificed and the injected (right tibio-tarsal) joints were excised. The specimens were fixed in 10% formalin for one week and decalcified in a demineralizing solution for 48 h. Then the samples were embedded in paraffin, sectioned with microtome at a thickness of 5  $\mu\text{m}$ , stained with hematoxylin and eosin and finally observed under light microscope. The joint inflammation was evaluated using three criteria: 1) infiltration of inflammatory cells, 2) synovial congestion and 3) synovial hyperplasia, the intensity of which was scored using a grading scale of "—" to "++", in which "—" normal without infiltration, congestion and hyperplasia; "±", occasionally occurred; "+", regularly seen; "++", significant manifestation. From every joint four sections were taken from different depths to give a representative appreciation of the whole joint. Final mean scores were determined from the different sections of the individual animal.

### X-ray imaging

At the beginning and the end of treatment, two rats were taken randomly from each group and their hind paws were exposed to x-ray film (30 mA s, 25 kV) using digital X-ray machine (GIOTTO IMAGE-MD, Italy). The images were analyzed by radiological signs such as the presence of soft tissue swelling, clarity of joint space, periosteal reaction and bone destruction.

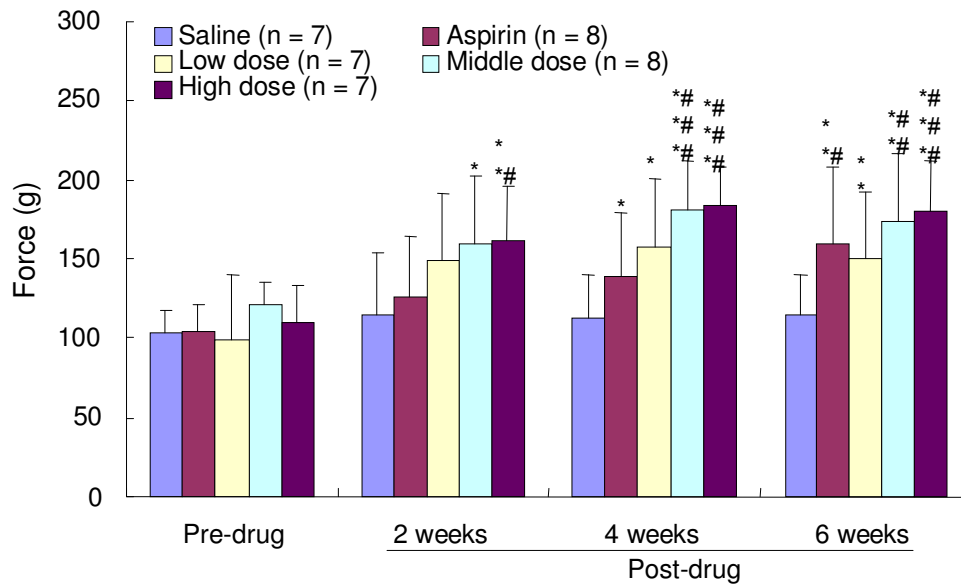
### Statistical data analysis

All the data were expressed as mean  $\pm$  SD. The difference between groups was evaluated by student's *t*-test or one-way ANOVA. In each case  $p < 0.05$  was considered statistically significant.

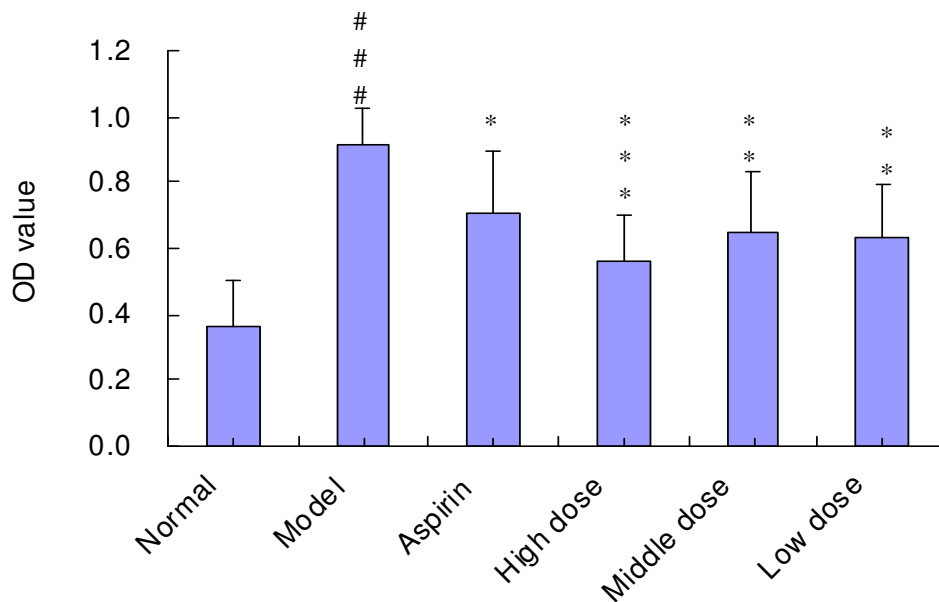
## RESULTS

### NBT increases the pain threshold of CFA-injected rats

As in the positive control group of aspirin, three doses (350, 175 and 87.5 mg/kg) of NBT could increase the pain threshold measured by mechanical pressure-paw withdrawal test during 6 week treatment. The increase was statistically significant as compared with that of control group of normal saline, as well as with that before drug treatment ( $p < 0.05$  to  $p < 0.001$ , Figure 1). As the dose increased, the antinociceptive effect also increased, but no statistical significance was observed. Among three time points (2, 4, and 6 weeks) during treatment the increase in pain threshold also had no statistical difference. Results indicated that NBT given consecutively for 6 weeks produced significant antihyperalgesic effect for monoarthritic rats, but no significant dose-dependence and time-dependence.



**Figure 1.** Increase in pain threshold (measured by mechanical pressure-paw withdrawal test) during NBT treatment. Data are mean  $\pm$  SD. \* $p < 0.05$ , \*\* $p < 0.01$ , \*\*\* $p < 0.001$  vs normal saline group; #  $p < 0.05$ , ##  $p < 0.01$ , ###  $p < 0.001$  vs before drug treatment (evaluated with student's  $t$ -test).

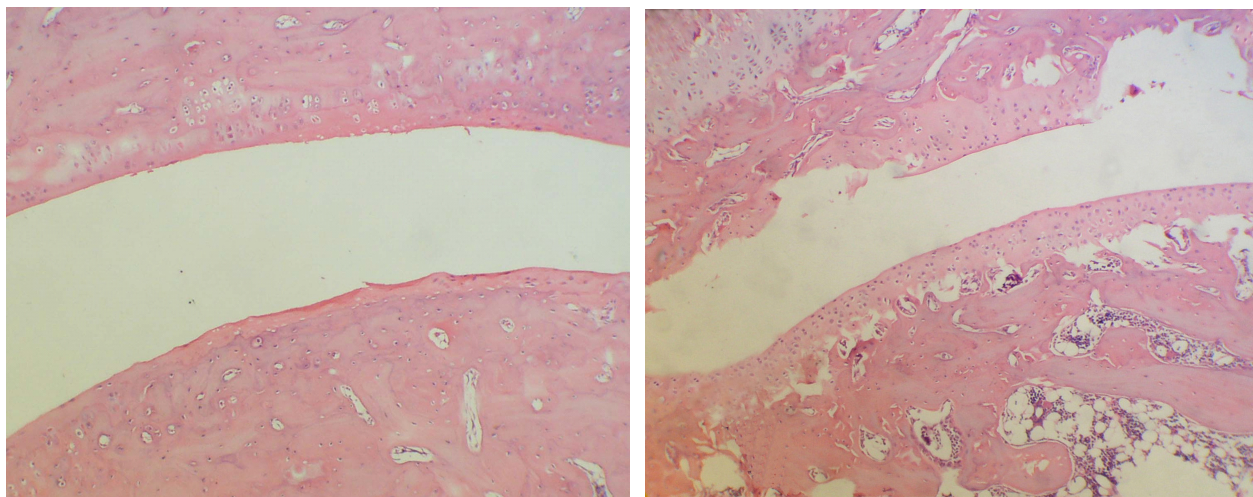


**Figure 2.** Decrease in serum IL-6 level of CFA-injected rats by three doses of NBT treatment. Data are mean  $\pm$  SD. \* $p < 0.05$ , \*\* $p < 0.01$ , \*\*\* $p < 0.001$  vs model group without treatment; ###  $p < 0.001$  vs normal group (evaluated with student's  $t$ -test).

**NBT decreases the serum IL-6 level of CFA-injected rats**

As shown in Figure 2, compared to the normal group, the

serum IL-6 level in CFA-injected (model) rats increased significantly ( $p < 0.001$ ). As in the group of aspirin, three doses (350, 175 and 87.5 mg/kg) of NBT could decrease the serum IL-6 level of inflamed rats, which was



**Figure 3.** Histo-pathological changes of ankle (tibio-tarsal) joint after CFA injection ( $\times 100$ ). A) In normal rats, the structure of joint was normal, the synovial cavities were clear and smooth, and no abnormal changes in joint tissue were observed, B) In CFA-injected rat, the normal structure of joint was damaged. Erosion of the synovial membrane, mononuclear cell infiltration, synovial congestion and hyperplasia were apparent.

significant as compared with that of model rats without treatment ( $p < 0.05$  to  $p < 0.001$ ). Results indicated that NBT given consecutively for 6 weeks could decrease the serum IL-6 level of CFA-injected rats (Figure 2).

#### **Effects of NBT on the histo-pathological changes of CFA-injected joint**

In control rats the structure of tibio-tarsal joint was normal, the synovial cavities were clear and smooth (Figure 3A), and no abnormal changes in joint tissue were observed (Table 1). Compared with the normal joint structure, the right tibio-tarsal joints of CFA-treated rats were damaged. Erosion of the synovial membrane, mononuclear cell infiltration, synovial congestion and hyperplasia were apparent (Figure 3B and Table 1). Joint samples of arthritic rats treated with three doses of NBT showed some attenuation in the inflammatory changes, which were apparent as compared with that of arthritic rats treated with normal saline (Table 1). Results showed that NBT could diminish the histo-pathological changes of CFA-injected joint.

#### **NBT ameliorates the X-ray image of CFA-injected joint**

In the X-ray image of normal joint, the joint spaces were clear. Neither soft tissue swelling nor bone proliferation was observed (Figure 4A). Five days after CFA injection the joint spaces were obscure, there were significant soft tissue swelling and marked periosteal reaction (Figure

4B). After 6 week treatment with NBT soft tissue swelling subsided, joint spaces became clear and smooth (Figure 4C), while in the control rat the joint spaces were still obscure, although the soft tissue swelling had subsided (Figure 4D). These results indicated that NBT could ameliorate the X-ray image of CFA-injected joint.

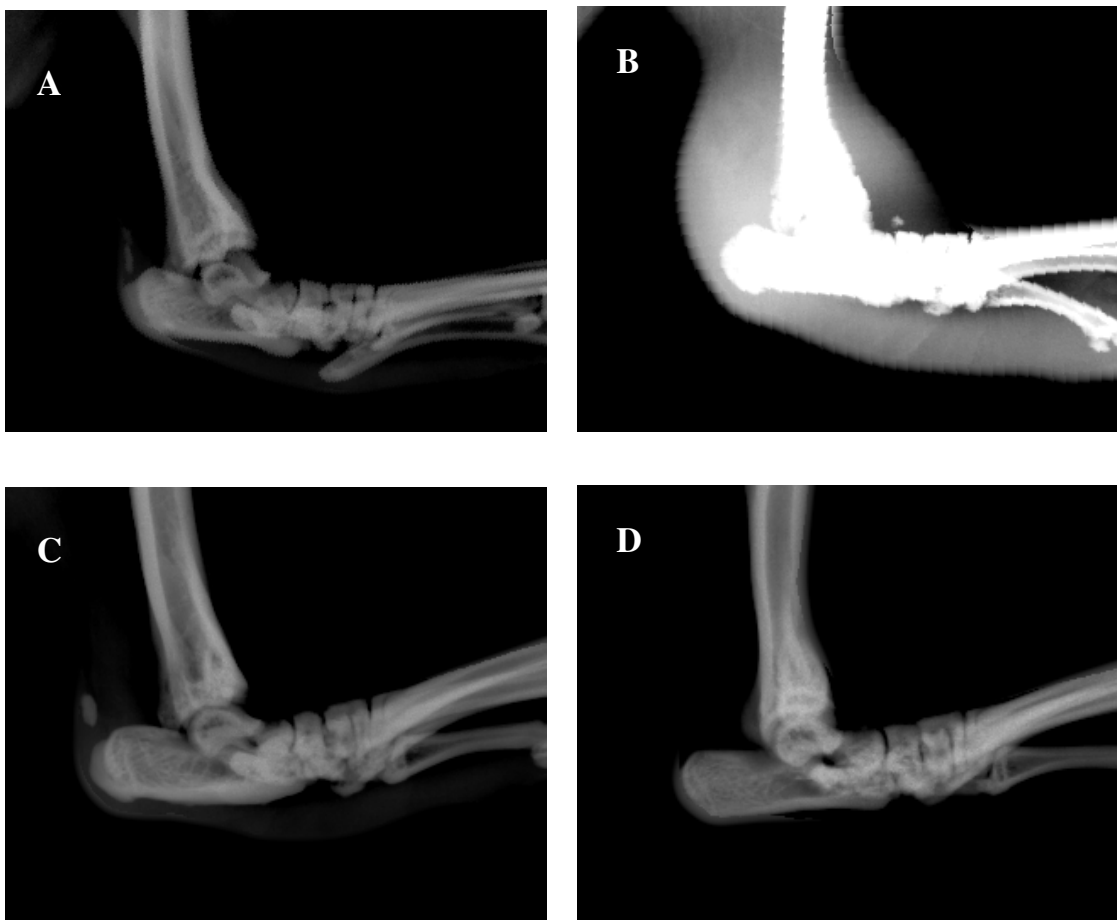#### **DISCUSSION**

The main finding of this study was that a significant antihyperalgesic effect of NBT during 6 week period of treatment was observed on CFA-induced monoarthritic model in rats. Combining with the early results that NBT could inhibit the pain behavior on hotplate test and writhing test in mice (Zhang et al., 2004), it is suggested that this Chinese medicine compound, NBT, is beneficial in the treatment not only for acute pain, but also for chronic pain, thus having a wide perspective in the treatment of pain diseases.

CFA administration to rodents produces an arthritic state that is believed to have closely resemble the human rheumatoid arthritis condition, which is characterized by inflammation of joint and surrounding tissue, hyperalgesia and elevation of the concentration of pro-inflammatory cytokines including IL-1 $\beta$ , IL-6 and tumor necrosis factor- $\alpha$  (TNF- $\alpha$ ), which are closely related with the pathological changes (Yue et al., 2004; Elenkov et al., 2005). In the present study, the serum IL-6 level was increased markedly after CFA injection as compared to that of the control group and decreased significantly after treatment with NBT. At the same time, hyperalgesia was diminished, and the patho-morphological changes

**Table 1.** The histo-pathological changes of tibio-tarsal joint in CFA-induced arthritic rats and after treatment with NBT for 6 weeks.

Duration after treatment	Mononuclear infiltration	Synovial congestion	Synovial hyperplasia
5 days after CFA injection			
CFA-injected group	++	++	++
Control group	-	-	-
6 weeks after NBT			
High dose group	±	±	-
Middle dose group	-	±	±
Low dose group	±	+	+
Normal saline	++	+	+



**Figure 4.** X-ray images of ankle (tibio-tarsal) joint. A) Normal joint, the joint spaces were clear, neither soft tissue swelling, nor bone proliferation was observed, B) five days after CFA injection, the joint spaces were obscure, there were significant soft tissue swelling and marked periosteal reaction, C) after 6 week treatment with NBT, soft tissue swelling subsided, joint spaces became clear and smooth, D) control, treated with normal saline, the joint spaces were still obscure, although the soft tissue swelling had subsided.

including histo-pathological changes and X-ray images were ameliorated. These results are similar to those reported with other herbal anti-inflammatory and

antinociceptive drugs. Kim et al. (2002) found that extract from Bang-Poong (*Radix ledebouriellae*) could diminish the joint swelling, attenuate the hyperalgesia,

decrease the serum IL-6 concentration and ameliorate the X-ray images of CFA-induced arthritis in rats. Bi et al. (2007) reported that kirenol, an extract from *Siegesbeckia orientalis* L. could decrease the serum concentration of pro-inflammatory cytokines including IL-1 $\beta$ , IL-6 and TNF- $\alpha$ , and attenuate the abnormal expression of synovial apoptotic proteins in CFA-induced arthritic rats. Therefore, it is suggested that besides antihyperalgesic effect NBT also has some anti-inflammatory effects.

Fundamentally, the antihyperalgesic and anti-inflammatory effects of NBT may be attributed to the components of this compound, because pain-killing effect of Chuan-xiong (rhizoma chuanxiong), and anti-swelling and anti-pain effect of San-qi (radix notoginseng) were already mentioned in ancient literature "Yellow Emperor's Internal Classic" (2000 years ago) and "Compendium of Materia Medica" (1590). In addition, the analgesic effects of radix notoginseng, rhizoma chuanxiong and folium ginkgo were demonstrated with modern pharmacological methods in hotplate and writhing tests in mice (Zhou et al., 2007; Huang, 1994).

In summary, NBT as a compound made from the Chinese herbal medicines, is able to inhibit the acute noxious reactions and to attenuate the chronic hyperalgesia. The serum level of pro-inflammatory cytokine IL-6 was decreased and the pathological changes of inflamed joint were ameliorated. No adverse effects were observed during 6 week period of treatment. NBT might be used as a subsidiary to the antinociceptive and anti-inflammatory therapy.

## ACKNOWLEDGEMENTS

We thank Yuan-biao Yu, Yu-jia Wan, and Jie-chen Yan from Medical College of Soochow University for their technical support. This project was supported by Winsor Health Products Ltd, Hong Kong, China.

## REFERENCES

- Bi J, Xin HL, Gao ZF, Lin WH, Qian RQ (2007). Effect of kirenol on cytokines in serum and apoptosis proteins expression in synoviocytes of adjuvant arthritis in rats. *Chin. Trad. Herb Drugs.*, 38: 1207-1210.
- Butler SH, Godefroy F, Besson JM, Weil-Fugazza J (1992). A limited arthritic model for chronic pain studies in the rat. *Pain*, 48: 73-81.
- Elenkov IJ, Iezzoni DG, Daly A, Harris AG, Chrousos GP (2005). Cytokine dysregulation, inflammation and well-being. *Neuroimmunomodulation*, 12: 255-269.
- Huang TK (1994). A handbook of the composition and pharmacology of common Chinese drugs. *China Med. Pharm. Sci. Technol. Press*, 413-421.
- Kim HW, Kwon YB, Ham TW, Roh DH, Yoon SY, Han HJ, Kang SK, Lee HJ, Mar WC, Yang IS, Beitz AJ, Lee JH (2002). The antinociceptive and anti-inflammatory effect of ethylacetate extracts from Bang-Poong (*Radix ledebouriellae*) on the Freund's adjuvant-induced arthritis in rats. *J. Vet. Sci.*, 3: 343-349.
- Liu HX, Xu W, Luo F, Wang JS, Han JS (1996). A limited arthritic model for chronic pain studies in rats. *Chin. J. Pain Med.*, 2: 223-228.
- Yue L, Wang H, Liu LH, Shen YX, Wei W (2004). The effects of recombinant human endostatin on adjuvant arthritis in rats. *Chin. Pharmacol. Bull.*, 20: 291-294.
- Zhang HL, Gu ZL, Chen BW (2004). Antinociceptive effect of Naobitong capsule. *Chin. Trad. Patent Med.*, 26: 1059-1060.
- Zhou ZM, Guo SM, He J, Dai WF, Luo WL, Li BC (2007). Progress in the studies of Chinese herbal analgesic drugs. *Yunnan J. Trad. Chin. Med. Mat. Med.*, 28: 52-53.
- Zimmermann M (1983). Ethical guidelines for investigations of experimental pain in conscious animals. *Pain*, 16: 109-110.