

*Full Length Research Paper*

## Effects of exogenous ghrelin on experimental reflux esophagitis model in male rat

Seyed Mahdi Mohamadi<sup>1</sup>, Fatemeh Nabavizadeh<sup>1\*</sup>, Mahdieh Faghihi<sup>1</sup>, Gholamreza Hasanzadeh<sup>2</sup>, Hamideh Afzali<sup>1</sup> and Hamid Sohanaki<sup>1</sup>

<sup>1</sup>Department of Physiology, School of Medicine, Tehran University of Medical Sciences, Tehran, Iran.

<sup>2</sup>Department of Anatomy, School of Medicine, Tehran University of Medical Sciences, Tehran, Iran.

Received 23 May, 2015; Accepted 23 July, 2015

Reflux esophagitis is a common gastrointestinal disorder that affects the quality of life in patients. Esophagitis is a chronic disease that leads to inflammation of the esophagus. Ghrelin is a 28-amino acid peptide that has several endocrine and metabolic effects. The aim of this study was to investigate the effect of ghrelin on the esophagitis. Eighteen wistar rats were divided into three groups of six. Midline laparotomy was performed in the control group. In the gastroesophageal reflux disease (GERD) and GERD+Ghrelin groups, esophagitis was induced by method of Omura. Rats in GERD+Ghrelin group received 4 i.p. injections of 25 ng/g body weight ghrelin. The amount of gastric acid secretion and esophageal blood flow were measured. Gastric acid in GERD+Ghrelin group increased significantly when compared to control and GERD groups. The epithelium thickness and papillae of lamina propria length in GERD group increased significantly compared to the control group. The difference in papillae of lamina propria length between GERD and GERD+Ghrelin was statistically significant. Esophageal blood flow in GERD+Ghrelin group increased significantly in comparison with GERD group. Treatment with ghrelin could reduce esophageal mucosal damage followed by chronic exposure of acid and other gastric contents.

**Key words:** Reflux esophagitis, ghrelin, blood flow, gastric acid, mucosal damage, rat.

### INTRODUCTION

Gastroesophageal reflux disease (GERD) is a common gastrointestinal disorder in the world known with specific symptoms such as heartburn and acid regurgitation (Klauser et al., 1990). It has been proven that GERD is a major etiologic factor which causes inflammatory and neoplastic disorders in the upper gastrointestinal tract (Koufman, 1991). Chronic exposure to gastric contents such as acid, pepsin, trypsin and bile acids with esophageal squamous epithelium is the main initiating

factors of this processes (Dodds et al., 1982).

In chronic reflux, gastric acid can cause several degrees of esophageal mucosal injuries like basal cell hyperplasia, mucosal thickening and lamina papillae elongation. In most patients, damaged epithelium heals through squamous cell regeneration and sometimes via a metaplastic process called Barrett's esophagus which is the major risk factor for esophageal adenocarcinoma p (Spechler, 2002). It has been reported that GERD

\*Corresponding author. E-mail: nabavizadeh@tums.ac.ir; Tel: +98(21)66419484.

Author(s) agree that this article remain permanently open access under the terms of the [Creative Commons Attribution License 4.0 International License](https://creativecommons.org/licenses/by/4.0/)

revalence in western countries ranges from 10 to 48 % (Heading, 1999). Major GERD symptoms occur at least monthly in 18.4% of the urban population in Tehran district (Nourai et al., 2007).

Ghrelin, a 28-amino acid peptide which mainly releases from the stomach is known as endogenous ligand of growth hormone secretagogue receptor (Kojima and Kangawa, 2005). Although, this hormone primarily stimulates growth hormone release, further studies revealed its several endocrine functions like anti-inflammatory characteristics (Arvat et al., 2001; Chang et al., 2003; Xia et al., 2004).

Ghrelin exerts its anti-inflammatory actions via inhibiting pro-inflammatory cytokines (Chang et al., 2003; Xia et al., 2004) in a set of gastrointestinal diseases such as inflammatory bowel disease in particular crohn's disease and pancreatitis (DeBoer, 2011; Warzecha et al., 2010). Therapeutic features of ghrelin are shown in animal models of colitis (Gonzalez-Rey et al., 2006; Konturek et al., 2009). It exerts gastro protection against stress induced damage, ischemia reperfusion injury, and ethanol induced lesions (Brzozowski et al., 2004; Brzozowski et al., 2006; Konturek et al., 2006). Golestan et al. (2011), showed ghrelin protective effects against acetaminophen-induced liver injury in rats.

Therefore, the aim of the present study was to investigate the effects of exogenous ghrelin on histopathological changes of esophageal tissue, gastric acid secretion and esophageal blood flow in the Omura model of rat esophagitis (Golestan et al., 2011).

## MATERIALS AND METHODS

*Ghrelin* powder (24159; AnaSpec) was dissolved in sterile water (1mg/ml) and stored at -20°C until the day of administration. Before use, ghrelin diluted with 0.9% saline to the final concentration (25 ng/ $\mu$ l) for intraperitoneal administration.

### Animals

Experimental protocol was approved by the institutional care and committee of Tehran university of medical sciences. Eighteen male Wistar rats weighing 180 to 250 g were housed in 3 groups of 6 rats per cage. Rats maintained in a temperature controlled room with a 12 h light/dark cycle, and allowed to access water and standard laboratory food ad libitum. Animals were adapted for at least 7 days before starting the experiments.

### GERD induction

GERD model induction was performed according to the method of Omura et al. (1999). Rats were first anesthetized with intraperitoneal (i.p.) injection of ketamine (50 mg/kg) and xylazine (10 mg/kg) mixture after 24 h of fasting. After prep, midline laparotomy was done via sub-xyphoid approach. The transitional region between the forestomach and the glandular portion was ligated using 2 to 0 silk thread to enhance gastric acid reflux into the esophagus. The duodenum near the pylorus was wrapped with a piece of 18Fr Nelaton catheter. To prevent catheter dislodgment,

edge of the catheter was sutured to the serosa layer of the pylorus using a 5 to 0 nylon thread. Rats were sacrificed 15 days post operation. Sham operated rats were used as controls. In another experiment, 6 rats with chronic reflux esophagitis received 4 i.p. injections of 25 ng/g body weight ghrelin at 5, 8, 11, and 14 days after surgery to evaluate the effects of ghrelin on inflammation development. In control group, animals received normal saline instead.

### Gastric acid measurement

After GERD induction, rats had free access to food and water for 14 days except for the last 24 h of fasting period prior to the experiment. Tracheostomy was performed under general anesthesia with sodium thiopental (50 mg/kg i.p.). To prevent gastric reflux, cervical esophagus was then ligated. Laparotomy was done and a polyethylene tube (2.5 mm O.D., 10 cm length) was placed into the stomach via duodenal transverse incision. Gastric lavage was performed several times with 1 to 2 ml of 37°C normal saline. Animals were also allowed to have 30 min recovery. Basal acid secretion was measured with a digital titrator (Basic titrino, Metrohm, 749).

### Blood flow measurement

Immediately after gastric content sampling, esophagus blood flow was measured with laser Doppler flow meter (Moor Instrument, VMS-LDF, UK). The probe was placed on the lower esophagus, and fixed with a special holder to measure esophageal blood flow as perfusion unit and reported as baseline percentage.

### Histological assessment

At day 15, after measurement of gastric acid and esophagus blood flow, lower esophagus samples were removed and fixed in 10% buffered-formaldehyde solution. Tissue sections were stained with hematoxyline-eosin dyes and studied with Optika light microscope equipped with a digital camera. Epithelium thickness and the papillae of the lamina propria elongation into the epithelial surface were measured.

### Statistical analysis

Data were expressed as mean  $\pm$  SEM. One way and two way analysis of variances with Tukeys post-hock test were used to analyze differences between groups.  $P < 0.05$  was considered statistically significant.

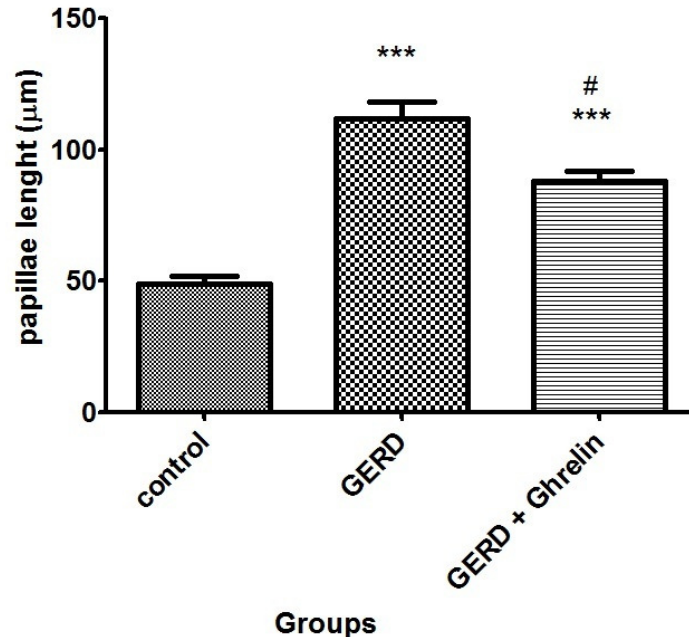
## RESULTS

### Effect of ghrelin on papillae elongation

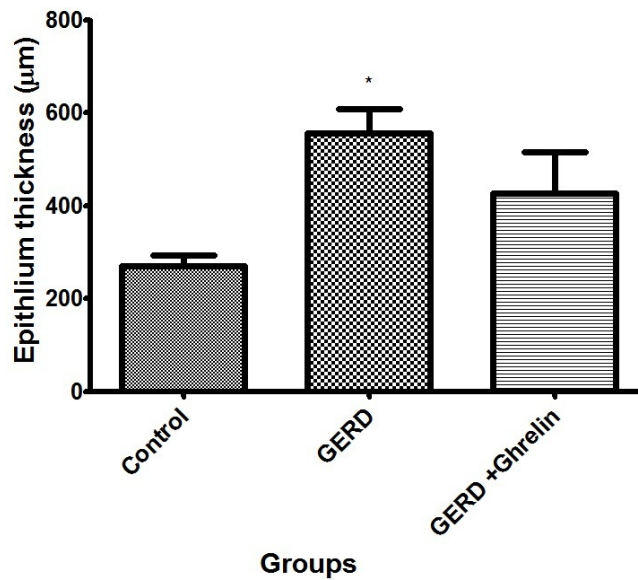
Papilla length was increased in both GERD (111.63 $\pm$ 6.58  $\mu$ m) and GERD+Ghrelin (88.07 $\pm$ 3.78  $\mu$ m) groups compared with control group (48.90 $\pm$ 3.18  $\mu$ m) ( $P < 0.05$ ). This increase however, in GERD group is statistically more than GERD+Ghrelin group ( $P < 0.05$ ) (Figure1).

### Effect of ghrelin on epithelium thickness

This study results showed that GERD induction increased



**Figure 1.** Comparison of the lamina propria papillae length between groups (n=6 in each group), Data presented as Mean±SEM. \*\*\*P<0.001 vs. control group. # p<0.01 vs. GERD group.

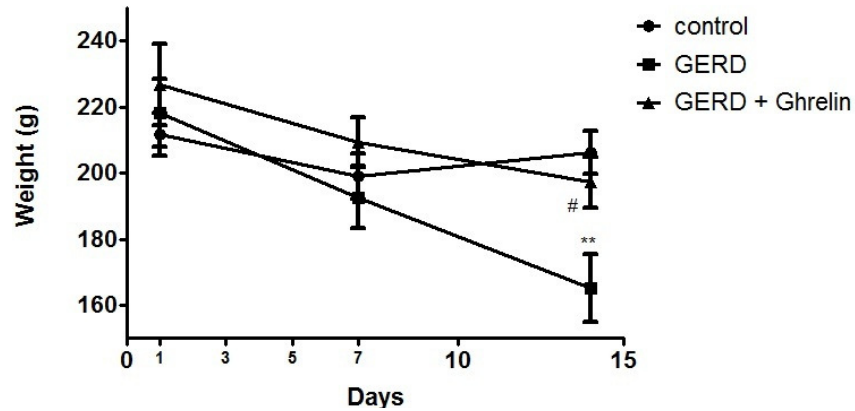


**Figure 2.** Comparison of the epithelium thickness between groups (n=6 in each group), Data presented as Mean±SEM. \*P<0.05 vs. control group. GERD: gastroesophageal reflux disease.

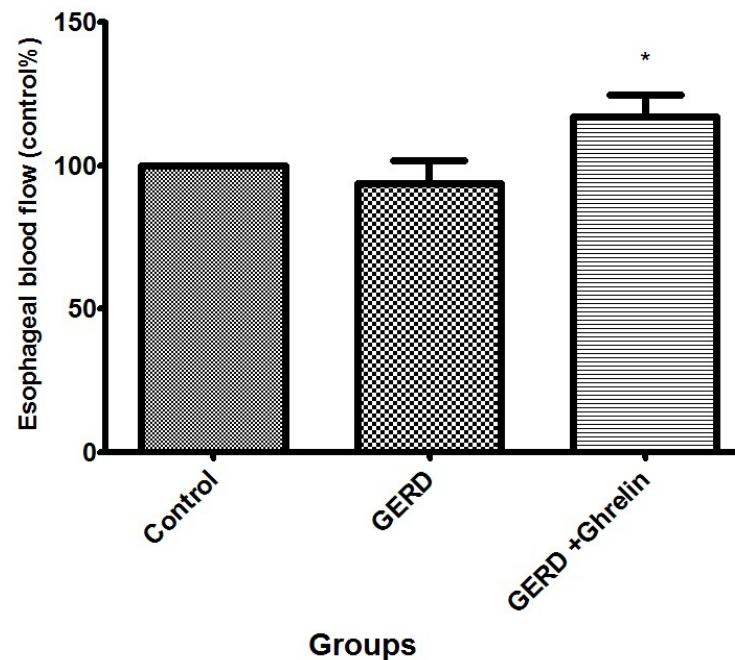
epithelium thickness in GERD group (555.73±52.55 µm) compared with control (269.69±23.88 µm) (P<0.05). Ghrelin injection could decrease epithelium thickness (476.81±89.74 µm) compared with control group (Figure 2).

#### Effects of ghrelin on animals' weight

GERD induction significantly decreased animals' body weight (165.16±10.18 g) on day 14, in comparison with control (206.16 ± 6.43 g) (p < 0.01). Treatment with



**Figure 3.** Animals' body weights on days 1, 7 and 14 after GERD induction. (n=6 in each group), Data were presented as Mean±SEM. \*\* P<0.01 vs. control group. # P<0.05 vs. GERD+Ghrelin group. GERD: gastroesophageal reflux disease.



**Figure 4.** Comparison of esophageal blood flow between groups (n=6 in each group), Data were presented as Mean±SEM \* P<0.05 vs. GERD group. GERD: gastroesophageal reflux disease.

ghrelin ( $197.16 \pm 7.6$  g) could stop GERD induced weight reduction and improved animals' weight similar to those in control group. In addition, statistical analysis showed no statistically difference between experimental groups on days 1 and day 7 (Figure 3).

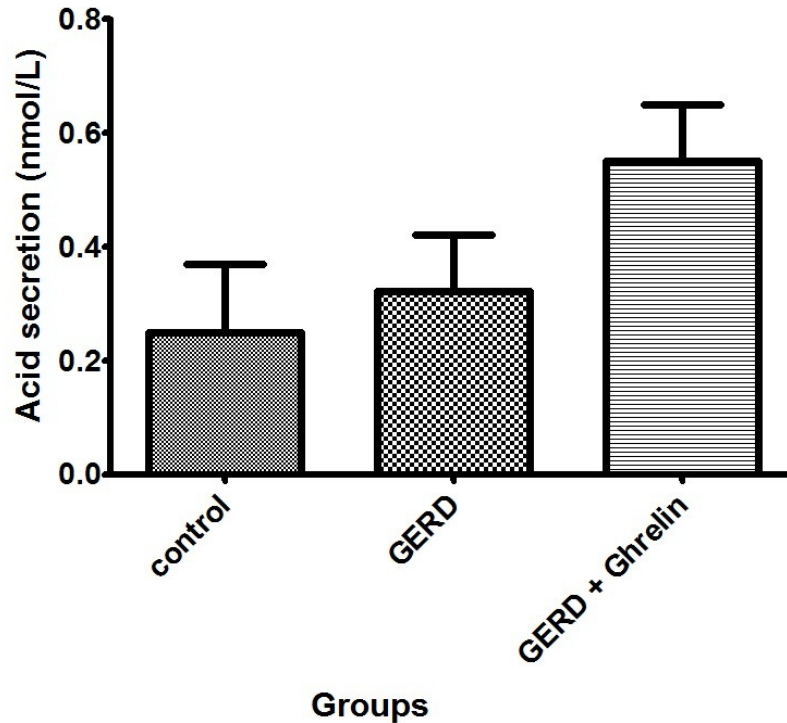
#### Effects of ghrelin on esophagus blood flow

Measurement of blood flow showed no significant

differences between control versus GERD animals. Intraperitoneal (Ip) injection of ghrelin significantly increased esophageal blood flow in comparison with GERD group (P<0.05) (Figure 4).

#### Effects of ghrelin on gastric acid secretion

The study results revealed no significant differences in gastric acid secretion between experimental groups



**Figure 5.** Comparison of gastric acid secretion between groups (n=6 in each group), Data were presented as Mean±SEM

(Figure 5).

## DISCUSSION

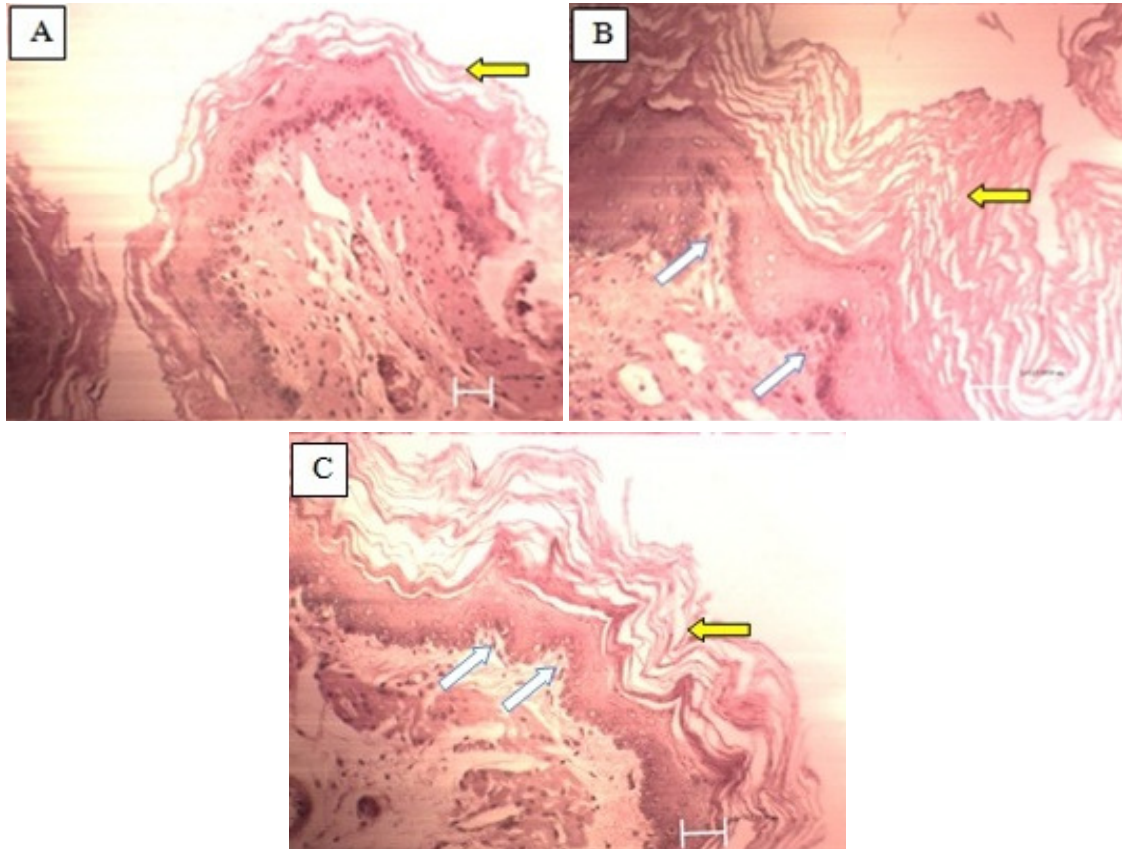
In the present study, mild ghrelin stimulatory effects on gastric acid secretion and gastric emptying compared with control animals were showed. Increased gastric emptying may be mediated through amplified gastric movements followed by decreased acid, pepsin and other gastric contents exposed to the esophagus. In rat, ghrelin has shown to increase gastric acid secretion, frequency and intensity of gastric movements in a dose dependent manner (Masuda et al., 2000). In ghrelin receptor knockout mice, ghrelin could not increase gastric emptying while in wild type animal, it could increase it dose dependently (Yang et al., 2013). Ghrelin could also increase contraction or relaxation amplitude of the smooth muscle strips in the presence of electrical field stimulation in an escalating dose model (Yang et al., 2013). Gastric emptying was also shown to be increased based on Dornonville et al. (2004) study.

Mucosal blood flow plays an important role in protecting against mucosal damage. Many experimental studies have shown that exposure of gastric mucosa to potentially noxious environment results in little or no damage if adequate blood flow exists (Sorbye and Svanes, 1994). Adequate blood flow can play its role

with supplying the mucosa with oxygen, bicarbonate and nutritious substances, and removing carbon dioxide, hydrogen ions and toxic agents diffusing from the gastric lumen (Allen et al., 1993). Mucosal hypoxia causes hydrogen ion accumulation in the mucosa followed by gastric acidification and ulcer development (Allen et al., 1993). Mucosal acidification is an important predictor of mucosal bleeding (Fiddian-Green and Baker, 1987). Bleeding can reduce blood flow and consequently increase gastric mucosal damage (Kwiecien et al., 2007). Duodenal mucosal hypoxia inhibits ulcers healing (Leung et al., 1989).

The therapeutic effect of ghrelin on gastric and duodenal ulcers is indirect and depends on the release of IGF-1 (Ceranowicz et al., 2009). Ghrelin increases GH and IGF-1 serum levels in rats with intact pituitary gland. This effect is associated with accelerated gastric and duodenal healing. According to this study, growth hormone effects can directly and indirectly mediate through IGF-1 (Ceranowicz et al., 2009). In this study, improved esophageal mucosal blood flow in ghrelin treated animals may be mediated through indirect IGF-1 stimulation. Food intake can cause weight gain, and has an important role in the regulation of gastrointestinal mucosal growth (Tabata and Johnson, 1986; Dembiński et al., 2004).

Dietary content may have direct or indirect impact on mucosal growth (Dembinski et al., 1984). On the other



**Figure 6.** Histological findings in three experimental groups (HE staining). (A) esophageal mucosa in control group. (B) Esophageal mucosa in GERD group. The epithelium was markedly thickened (yellow arrows). Also note the lamina propria papillae elongation into the epithelium (white arrows). (C) Esophageal mucosa in GERD+Ghrelin group. Changes in part B had a lower degree than in part C.

hand, starvation (Dembiński et al., 2004) or parenteral nutrition (Steiner et al., 1968), can cause atrophy of the stomach and intestinal mucosa. Ghrelin has an orixigenic effect and is capable to increase appetite and food intake. In this study, administration of ghrelin could prevent GERD induced weight loss. This effect may partially be due to an increase in food intake. Studies also showed that ghrelin can significantly increase gastric and duodenal mucosal blood flow. As mentioned earlier, this effect maybe mediated through IGF-1 (Warzecha et al., 2006). IGF-1 has been shown to have vasodilatory effects and can increase tissue blood flow (Walsh et al., 1996; Hasdai et al., 1998). Delayed gastric emptying is a risk factor for GERD and affects approximately 10 to 40% of patients (Festi et al., 2009).

Ghrelin can increase gastric emptying rate and consequently reduce gastric acid reaching to the esophagus. This phenomenon can prevent extensive damage due to gastric acid reflux. Ismail-beigi et al. (1970) reported that hyperplasia of the squamous epithelium and elongation of papillae of lamina propria are the indicative of low grade mucosal damage due to

GERD. Omura et al. (1999) reported that histological changes caused by surgically induced esophagitis in rats are thickness of squamous epithelium and elongation of the papillae of the lamina propria (Figure 6). In the present study, treatment with ghrelin reduced the thickness of the squamous epithelium and lamina propria papillae length in comparison with GERD group. These ghrelin effects may be governed through increased mucosal blood flow and esophageal mucosal protection against damaging elements. Ghrelin anti-inflammatory effects have also been shown in rat acetaminophen-induced liver injury and celiac disease model in our previous studies (Golestan et al., 2010; Nikoukar et al., 2014). Therefore, ghrelin healing outcome in GERD induced esophagitis may also be mediated through its anti-inflammation mechanism.

In all, this study has its own shortcomings which make it rather difficult to reach a clear understanding on ghrelin possible mechanisms. The study preliminary results showed ghrelin effectiveness in GERD induced esophagitis healing process. More investigations are still needed to clarify exact mechanisms and unanswered



questions.

## ACKNOWLEDGEMENT

This experiment was supported by grant from Tehran University of Medical Sciences.

## Conflict of interest

The authors have none to declare.

## REFERENCES

- Allen A, Flemstrom G, Garner A, Kivilaakso E (1993). Gastroduodenal mucosal protection. *Physiol. Rev.* 73(4):823-857.
- Arvat E, Maccario M, Di Vito L, Broglio F, Benso A, Gottero C, Papotti M, Muccioli G, Dieguez C, Casanueva FF (2001). Endocrine activities of ghrelin, a natural growth hormone secretagogue (GHS), in humans: comparison and interactions with hexarelin, a nonnatural peptidyl GHS, and GH-releasing hormone 1. *J. Clin. Endocrinol. Metab.* 86(3):1169-1174.
- Brzozowski T, Konturek P, Konturek S, Kwiecień S, Drozdowicz D, Bielanski W, Pajdo R, Ptak A, Nikiforuk A, Pawlik W (2004). Exogenous and endogenous ghrelin in gastroprotection against stress-induced gastric damage. *Regul. Pept.* 120(1):39-51.
- Brzozowski T, Konturek P, Sliwowski Z, Drozdowicz D, Kwiecień S, Pawlik M, Pajdo R, Konturek S, Pawlik W, Hahn E (2006). Neural aspects of ghrelin-induced gastroprotection against mucosal injury induced by noxious agents. *J. Physiol. Pharmacol.* 57:63-76.
- Ceranowicz P, Warzecha Z, Dembinski A, Sendur R, Cieszkowski J, Ceranowicz D, Pawlik W, Kuwahara A, Kato I, Konturek P (2009). Treatment with ghrelin accelerates the healing of acetic acid-induced gastric and duodenal ulcers in rats. *Acta. Physiol. Pol.* 60(1):87.
- Chang L, Du J-B, Gao L-R, Pang Y-Z, Tang O (2003). Effect of ghrelin on septic shock in rats. *Acta Pharmacol. Sin.* 24 (1):45-49.
- DeBoer MD (2011). Use of ghrelin as a treatment for inflammatory bowel disease: mechanistic considerations. *Int. J. Pept.* p 8.
- Dembiński A, Warzecha Z, Ceranowicz P, Pawlik M, Dembiński M, Kabat K, Konturek S, Kownacki P, Hładki W, Pawlik W (2004). Influence of central and peripheral administration. *J. Physiol. Pharmacol.* 55(1):223-237.
- Dembinski AB, Yamaguchi T, Johnson LR (1984). Stimulation of mucosal growth by a dietary amine. *Am. J. Physiol.* 247:G352-G356.
- Dodds WJ, Dent J, Hogan WJ, Helm JF, Hauser R, Patel GK, Egide MS (1982). Mechanisms of gastroesophageal reflux in patients with reflux esophagitis. *N. Engl. J. Med.* 307(25):1547-1552.
- Dornonville de la Cour C, Lindström E, Norlén P, Håkanson R (2004). Ghrelin stimulates gastric emptying but is without effect on acid secretion and gastric endocrine cells. *Regul. Pept.* 120(1):23-32.
- Festi D, Scaiola E, Baldi F, Vestito A, Pasqui F, Di Biase AR, Colecchia A (2009). Body weight, lifestyle, dietary habits and gastroesophageal reflux disease. *World journal of gastroenterology: World. J. Gastroenterol.* 15(14):1690.
- Fiddian-Green RG, Baker S (1987). Predictive value of the stomach wall pH for complications after cardiac operations: comparison with other monitoring. *Crit. Care Med.* 15(2):153-156.
- Golestan Jahromi M, Nabavizadeh F, Vahedian J, Nahrevanian H, Dehpour A-R, Zare-Mehrjardi A (2010). Protective effect of ghrelin on acetaminophen-induced liver injury in rat. *Peptides* 31(11):2114-2117.
- Gonzalez-Rey E, Chorny A, Delgado M (2006). Therapeutic action of ghrelin in a mouse model of colitis. *Gastroenterology* 130(6):1707-1720.
- Hasdai D, Rizza RA, Holmes DR, Richardson DM, Cohen P, Lerman A (1998). Insulin and insulin-like growth factor-I cause coronary vasorelaxation *in vitro*. *Hypertension* 32(2):228-234.
- Heading RC (1999). Prevalence of upper gastrointestinal symptoms in the general population: a systematic review. *Scand. J. Gastroenterol. Suppl.* 231:3-8.
- Ismail-Beigi F, Horton PF, Pope CE (1970). Histological consequences of gastroesophageal reflux in man. *Gastroenterology* 58(2):163-174.
- Klauser AG, Schindlbeck NE, Muller-Lissner SA (1990). Symptoms in gastro-oesophageal reflux disease. *Lancet* 335(8683):205-208.
- Kojima M, Kangawa K (2005). Ghrelin: structure and function. *Physiol. Rev.* 85(2):495-522.
- Konturek P, Brzozowski T, Engel M, Burnat G, Gaca P, Konturek S (2009). Ghrelin ameliorates colonic inflammation. Role of nitric oxide and sensory nerves. *J. Physiol. Pharmacol.* 60(2):41.
- Konturek PC, Brzozowski T, Walter B, Burnat G, Hess T, Hahn EG, Konturek SJ (2006). Ghrelin-induced gastroprotection against ischemia-reperfusion injury involves an activation of sensory afferent nerves and hyperemia mediated by nitric oxide. *Eur. J. Pharmacol.* 536(1):171-181.
- Koufman JA (1991). The otolaryngologic manifestations of gastroesophageal reflux disease (GERD): a clinical investigation of 225 patients using ambulatory 24-hour pH monitoring and an experimental investigation of the role of acid and pepsin in the development of laryngeal injury. *Laryngoscope* 101(4 Pt 2 Suppl 53):1-78.
- Kwieceń S, Pawlik M, Sliwowski Z, Kwieceń N, Brzozowski T, Pawlik W, Konturek S (2007). Involvement of sensory afferent fibers and lipid peroxidation in the pathogenesis of stress-induced gastric mucosa damage. *J. Physiol. Pharmacol.* 58:149.
- Leung FW, Reedy TJ, Van Deventer GM, Guth PH (1989). Reduction in index of oxygen saturation at margin of active duodenal ulcers may lead to slow healing. *Dig. Dis. Sci.* 34(3):417-423.
- Masuda Y, Tanaka T, Inomata N, Ohnuma N, Tanaka S, Itoh Z, Hosoda H, Kojima M, Kangawa K (2000). Ghrelin stimulates gastric acid secretion and motility in rats. *Biochem. Biophys. Res. Commun.* 276(3):905-908.
- Nikoukar L, Nabavizadeh F, Mohamadi S, Moslehi A, Hassanzadeh G, Nahrevanian H, Agah S (2014). Protective effect of ghrelin in a rat model of celiac disease. *Acta Physiol. Hung.* 101(4):438-447.
- Nouraei M, Razjouyan H, Assady M, Malekzadeh R, Nasseri-Moghaddam S (2007). Epidemiology of gastroesophageal reflux symptoms in Tehran, Iran: a population-based telephone survey. *Arch. Iran Med.* 10(3):289-294.
- Omura N, Kashiwagi H, Chen G, Suzuki Y, Yano F, Aoki T (1999). Establishment of surgically induced chronic acid reflux esophagitis in rats. *Scand. J. Gastroenterol.* 34(10):948-953.
- Sorbye H, Svanes K (1994). The role of blood flow in gastric mucosal defence, damage and healing. *Dig. Dis.* 12(5):305-317.
- Spechler SJ (2002). Clinical practice. Barrett's Esophagus. *N. Engl. J. Med.* 346(11):836-842.
- Steiner M, Bourges HR, Freedman LS, Gray SJ (1968). Effect of starvation on the tissue composition of the small intestine in the rat. *Am. J. Physiol.* 215(1):75-77.
- Tabata K, Johnson LR (1986). Ornithine decarboxylase and mucosal growth in response to feeding. *Am. J. Physiol.* 251(2 Pt 1):G270-G274.
- Walsh MF, Barazi M, Pete G, Muniyappa R, Dunbar JC, Sowers JR (1996). Insulin-like growth factor I diminishes *in vivo* and *in vitro* vascular contractility: role of vascular nitric oxide. *Endocrinol.* 137(5):1798-1803.
- Warzecha Z, Ceranowicz P, Dembinski A, Cieszkowski J, Kusnierz-Cabala B, Tomaszewska R, Kuwahara A, Kato I (2010). Therapeutic effect of ghrelin in the course of cerulein-induced acute pancreatitis in rats. *J. Physiol. Pharmacol.* 61(4):419.
- Warzecha Z, Dembiński A, Ceranowicz P, Dembiński M, Cieszkowski J, Bielański W, Pawlik WW, Kuwahara A, Kato I (2006). Dual age-dependent effect of ghrelin administration on serum level of insulin-like growth factor-1 and gastric growth in young rats. *Eur. J. Pharmacol.* 529(1):145-150.
- Xia Q, Pang W, Pan H, Zheng Y, Kang J-S, Zhu S-G (2004). Effects of ghrelin on the proliferation and secretion of splenic T lymphocytes in mice. *Regul. Pept.* 122(3):173-178.
- Yang CG, Wang WG, Yan J, Fei J, Wang ZG, Zheng Q (2013). Gastric motility in ghrelin receptor knockout mice. *Mol. Med. Rep.* 7(1):83-88.