

Review

Modern practice in orthognathic and reconstructive surgery – Craniofacial distraction osteogenesis

Kumar Dheeraj^{1,2}, Namrataa Rastogi³ and Meenakshi Singh⁴

¹Department of Prosthodontics, Sardar Patel Post Graduate Institute of Dental and Medical Sciences, Lucknow, India.

²102-A, Vijay Nagar, Krishna Nagar, Kanpur Road, Lucknow, India.

³Department of Orthodontics and Dentofacial Orthopaedics, Sardar Patel Post Graduate Institute of Dental and Medical Sciences, Lucknow, India.

⁴Department of Orthodontics, Sardar Patel Post Graduate Institute of Dental and Medical Sciences, Lucknow, India.

Accepted 4 March, 2011

Distraction osteogenesis (DO) techniques have been widely accepted and practiced in orthopaedics, traumatology, and craniofacial surgery. Over the last two decades, using DO methods, many previously untreatable conditions have been successfully managed with outstanding clinical outcome. Although the mechanism of DO is still not fully understood, it is generally accepted that mechanical stimulation is the key in promoting and maintaining tissues' regenerating capacities. In the management of severe maxillomandibular deformities, orthognathic surgery produces less than optimum outcome with greater chances of relapse. Inadequate bone contact, insufficient fixation, stability and partial or total relapse due to excessive muscle stretching are often observed. To overcome these disadvantages a path breaking work in the field of distraction, osteogenesis occurred. The present article aims at highlighting the advantages of this newly developed technique over previous surgical remedies.

Key words: Distraction osteogenesis, orthopaedics, craniofacial surgery, orthognathic surgery.

INTRODUCTION

Although traditional orthognathic surgery and craniofacial reconstruction has gained generalized acceptance but it has its own limitations. Many congenital deformities require a large amount of skeletal movements and when acutely stretched, the surrounding soft tissues cannot adapt to their new position, resulting in regenerative changes, relapse, compromised function and aesthetics. Hence, in light to this, new approaches have been developed amongst which the most suitable alternative approach is "distraction osteogenesis." Distraction osteogenesis has revolutionized the management of several maxillomandibular deformities. In 1905, Codivilla introduced the limb lengthening procedure that had a high complication rate. Later in 1951, Dr. Gavrio Ilizarov did a path breaking work in the field of distraction

osteogenesis for limb lengthening based on the biology of bone and surrounding tissues to regenerate under tension. Distraction osteogenesis is a surgical approach by which the development of new bone growth in an area subjected to gradual tension stress occurs by the deliberate separation of fragments by traction. Distraction forces applied to bone creates tension in the surrounding soft tissues, initiating a sequence of adaptive histological changes termed as "distraction histogenesis". In early nineties a miniaturized orthopaedic device was successfully used extraorally by McCarthy et al. (1992) in children with craniofacial anomalies.

In late nineties, Wangerin used the first intraoral titanium mandibular distraction device and later Dessner et al. (2001) demonstrated an intraoral, tooth borne distractor for lengthening the mandible. Rachmiel et al. (1993, 1996, 1999) also successfully performed the gradual advancement of midface with the use of distraction osteogenesis. Figueroa and Polly (1999) continued with the use of extraoral distraction device to

*Corresponding author. E-mail: drdheerajkumarb@gmail.com.
Tel: 9415020749, 0522-2473305.

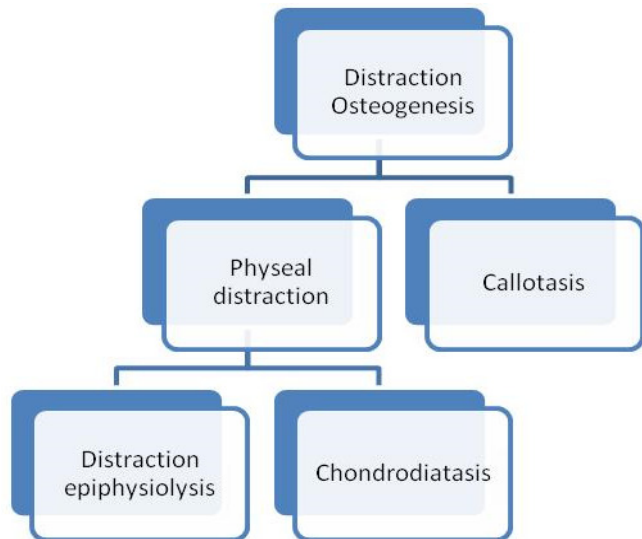


Figure 1. Classification of distraction.

distract the midface. The present article aims to highlight the clinical applications of reconstructive tissue engineering caused by distraction of bone for esthetic makeover of patients having severe dentofacial deformities.

CLASSIFICATION OF DISTRACTION OSTEOGENESIS

Depending upon the place where tensional stress was induced, the techniques are categorized in Figure 1 (De Bartiani et al., 1986).

Physeal distraction (Distraction of the bone growth plate)

Distraction epiphysiolysis

It involves the relatively rapid rate of bone segment separation, ranging from 1 to 1.5 mm/day. The increased tension between the growth plates produces fracture of the physis.

Chondrodiatasis

It utilizes a very slow rate of bone segment separation. It is generally less than 0.5 mm/day. Hence, growth plate is stretched without fracture (Sledge et al., 1978; Aldegheri et al., 1989).

The physeal distraction technique has certain disadvantages like difficulty in fixation of a very short epiphyseal segment and the physis frequently gets damaged resulting in premature cessation of growth (Peltonen et al., 1984; De Pablos et al., (1990).

Callotasis (Distraction of the fractured callus)

Callotasis is derived from two words: the Latin name callum (scar tissue between the bone segments) and the ancient Greek noun taois (tension or extension). It is the gradual stretching of the reparative callus forming around bone segments interrupted by osteotomy or fracture (Figure 5) (Ilizarov, 1989; Al-Aqs et al., 2008).

Therefore, callotasis is the preferred form for distraction osteogenesis. Clinically, callotasis consists of five sequential periods and these are: 1) osteotomy, 2) Latency, 3) Distraction, 4) Consolidation and 5) Remodelling.

1) Osteotomy is the surgical separation of a bone into two segments.

2) Latency is the period from bone division to the onset of traction and represents the time required for reparative formation between the osteotomized bone segments.

3) Distraction period is that time when a traction force is applied to bone segments and a new bone is formed within intersegmentary gap. The rate and rhythm of distraction are the two important parameters during this period. Rate represents the total amount of bone segment movement per day. Rhythm is the number of movements per day into which rate of distraction is divided.

4) Consolidation period allows mineralization and corticalization of the newly formed bone tissue prior to device removal.

5) Remodelling is the last clinical phase that takes place after removal of the distraction device. This period prolongs for approximately 1 year after completion of distraction.

HISTOLOGICAL ASPECT OF DISTRACTION OSTEOGENESIS

The clinical stages of distraction osteogenesis have a histological aspect also in Figure 6 (Ilizarov, 1989; Komuro et al., 1994; Aronson et al., 1990, 1997; Al-Aqs et al., 2008).

Osteotomy

As the bone is fractured and divided into two segments, the discontinuity triggers the process of bone repair called fracture healing. Firstly, recruitment of osteoprogenitor cells occurs, followed by cellular modulation or osteoinduction and establishment of an environmental template called osteoconduction. So, a reparative callus is formed within and around the ends of the fractured bone segments. Later the callus undergoes replacement by lamellar bone which is more mechanically resistant.

Latency period

- a) The inflammatory stage lasts for 1 to 3 days. Vascular disruption gives rise to haematoma which is converted to a clot and bony necrosis occurs at the end of the fractured segments. The clot is replaced lastly by granulation tissue consisting of inflammatory cells, fibroblasts, collagen and invading capillaries.
- b) At the end of the latency period, 5 days following osteotomy and just before commencement of distraction, only a mesh of fibrin clot containing blood cells and newly formed capillaries are observed.
- c) Soft callus stage lasts for approximately 3 weeks following the inflammatory stage. Continuation of in growth of capillaries takes place and the granulation tissue is converted to fibrous tissue by fibroblasts. Cartilage replaces the granulation tissue, more towards the periphery of the intersegmentary gap than in the central region. Cartilage provides a suitable material that is less demanding of oxygen, which temporarily bridges the gap until blood supply catches up.

Distraction period

During osteodistraction, the normal fracture healing is interrupted by the application of gradual traction to the soft callus. The growth stimulating effect of tension activates the biologic elements of the intersegmentary connective tissue. This causes the prolongation of angiogenesis with increased tissue oxygenation and increased fibroblast proliferation with intensification of biosynthetic activity. As distraction begins the fibrous tissue of the soft callus becomes longitudinally oriented along the long axis of the callus. Between third and seventh days of distraction the capillaries grow into the fibrous tissues, thereby extending the vascular network. During the second week the osteoblasts start laying down the osteoid tissue on these collagen fibres. Bone formation thus occurs along the vector of tension and is maintained by the growing apices, known as "growth zone."

Consolidation period

After 10 days of distraction (nearly 15 days post osteotomy), 3 distinct zones and two transitional areas within regenerative tissue could be observed.

- a) Histologically the first region to appear is the mid region called as central zone (CZ) in which the tissue is composed of mesenchyme-like and spindle shaped cells in which many capillaries are dispersed. So, it is called as "mesenchymal or proliferative area."
- b) On both the sides of central zone are the paracentral zones (PCZ) in which number of cells and capillaries are decreased gradually accompanied with intercellular

matrix mainly consisting of collagen fibres. So, it is called as "fibroblastic or collagenous area."

- c) Most proximally and distally are the proximal distal zones (PDZ) which are in direct continuation with old bony edges. Woven bone trabeculae are observed and hence it is called as "trabecular or mineralization area."

The tips of the trabecular area recruit pre osteoblasts from the collagen ridge distracted tissue. These are arranged concentrically around the tips of trabeculae and have high proliferation index. Then these preosteoblasts further mature into osteoblasts contributing to the trabecular growth so it is a transition period of the distraction zone. After completion of this period (nearly after 15 days of distraction) a homogenous zone is again observed and the trabeculae gradually become mineralized in the newly formed woven bone.

Remodeling period

After 6 weeks of consolidation there is no zonation as it was during active lengthening. The bony trabeculae become thicker with a mixture of lamellar and woven bone, rimmed by osteoblasts and bridging the distracted gap from edge to edge. Bone remodeling of newly formed bone by osteoclastic resorption is also identified histologically thereby completing the whole process. Thus, it takes a year or more before the structure of newly formed bone tissue matures.

CLASSIFICATION OF DISTRACTION DEVICES ACCORDING TO THE POSITION WHERE THEY ARE PLACED

Based on distraction device used

In general two types of devices have been used for craniofacial osteodistraction (Figure 2) (Samchukov et al., 1998):

Internal distractors

- i) They are placed either submucosally or extra mucosal.
- ii) They may be tooth borne, bone borne, or hybrid.
- iii) Advantage - they do not produce facial scarring.
- iv) Most commonly used intraoral titanium mandibular distraction device (Guerrero et al., 1997) (Figure 7).
- v) Modular internal distractors - used for midface advancement.
- vi) Customized tooth-borne distractors - they can be designed and fabricated by the orthodontist for maxillomandibular alveolus distraction in the transverse

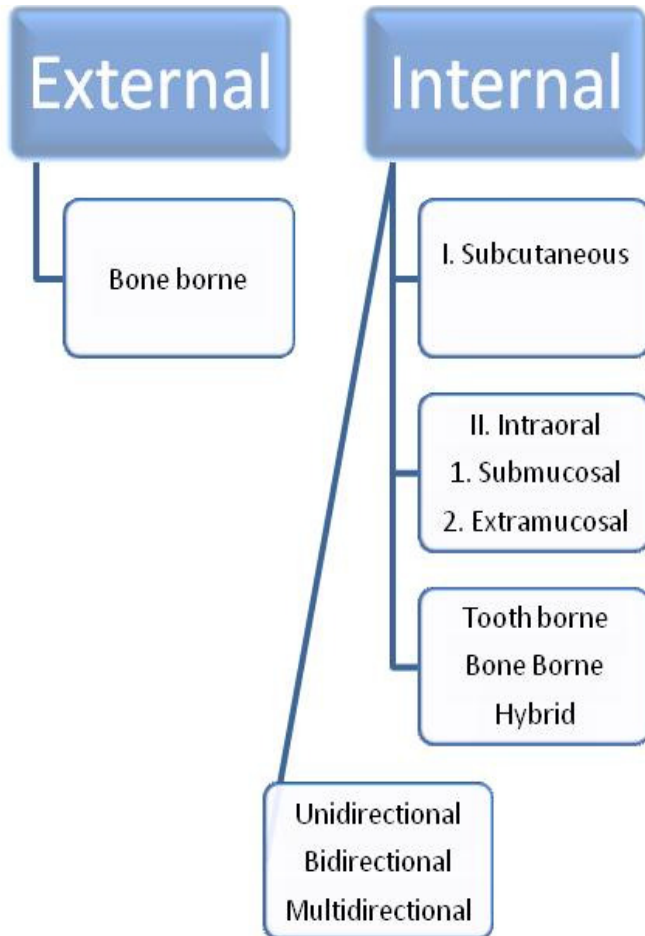


Figure 2. Classification of craniofacial distraction devices.

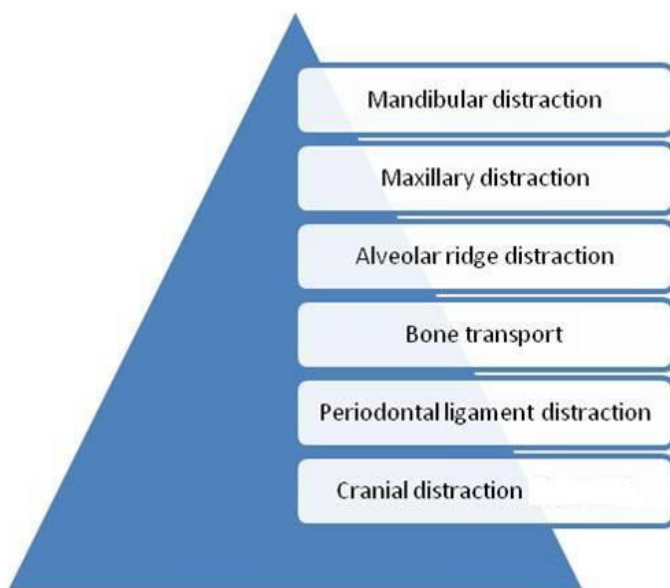


Figure 3. Classification of craniofacial distraction according to sites.

plane.

External distractors

- i) They are placed using bone pins.
- ii) Much easier to place and simpler to replace during distraction if necessary or to remove at the completion of bone lengthening.
- iii) Disadvantages - include skin scarring and poor acceptance by the patients (Figure 8) (Figuora and Polley, 1999).

Based on site at which it is placed

- 1. Mandibular distraction (Figure 3 and 9)
- 2. Midface/maxillary distraction (Figure 10)
- 3. Alveolar distraction (Figure 4).
- 4. Bone transport.
- 5. Internal distractor for craniofacial synostosis (rigid external distractor (RED) (Figure 11) (Samchukov et al., 1999).

Based on the plane in which the device works

Uniplaner and multiplaner devices

- i) Uniplaner devices accomplish the distraction in a single direction.
- ii) Multiplaner devices permit distraction in more than one plane by means of separate distraction arm.

CLINICAL IMPLICATIONS OF DISTRACTION OSTEOGENESIS

Indications

Congenital deformities

- i) Pierre-Robin syndrome. Distraction osteogenesis is required to prevent asphyxia and for correction of mandibular deficiency.
- ii) Severe retrognathic syndromes which include Treacher Collins syndrome and Goldenhar syndrome.
- iii) Severely constricted mandible in children and adults.
- iv) Congenital micrognathia-non-syndromic.
- v) Maxillary deficiency in operated cases of cleft lip and palate.
- vi) Craniofacial microsomia-unilateral/bilateral.
- vii) Midface hypoplasia.
- viii) Obstructive sleep apnoea syndrome.
- ix) Severely constricted maxilla in adults.
- x) Facial asymmetry (Dale et al., 2007).

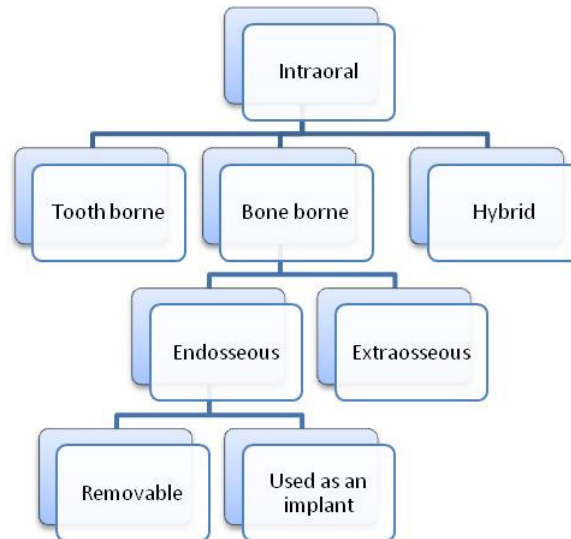


Figure 4. Alveolar ridge distraction devices.

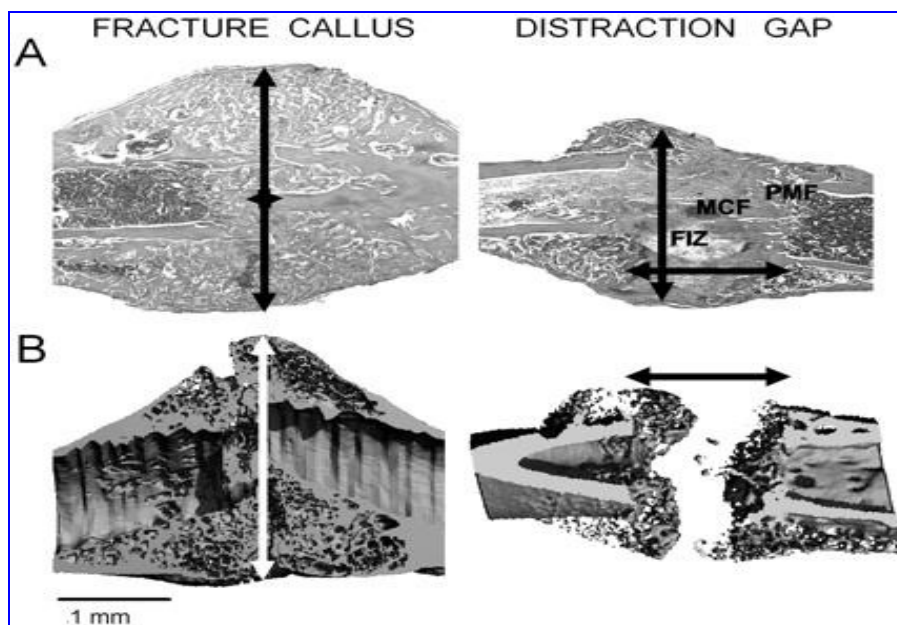


Figure 5. Comparisons of the tissue histology and mineralized tissue structure of fracture callus and distraction gap tissues. Murine femur fracture calluses and tibia distraction gap tissue were prepared from specimens obtained 21 days post-fracture or at 21 days post-surgery. (Panel A) Representative longitudinal sections of fracture and distraction osteogenesis were stained with Safranin-O/fast green. Original magnification 25x. (Panel B) Representative longitudinal microCT images at a resolution of 12 microns. Arrows indicate the extent of new bone formation. Both sets of images are presented with the distal and proximal orientations, left to right. The various zones in distraction osteogenesis are indicated. The central fibrous zone, histologically called the fibrous interzone (FIZ), is rich in chondrocyte-like cells, fibroblasts, and oval cells that are morphologically intermediate between fibroblasts and chondrocytes. The “fibrous interzone” contains differentiating osteoblasts that deposit osteoid along collagen bundles. When these collagen bundles mineralize, they form a zone called the zone of micro column formation (MCF). In between the “fibrous interzone” and the zone of micro column formation is a zone of high cell density called the primary matrix or mineralization front (PMF). Separate scale bars for both the histological and microCT images are presented below each image (1 mm).

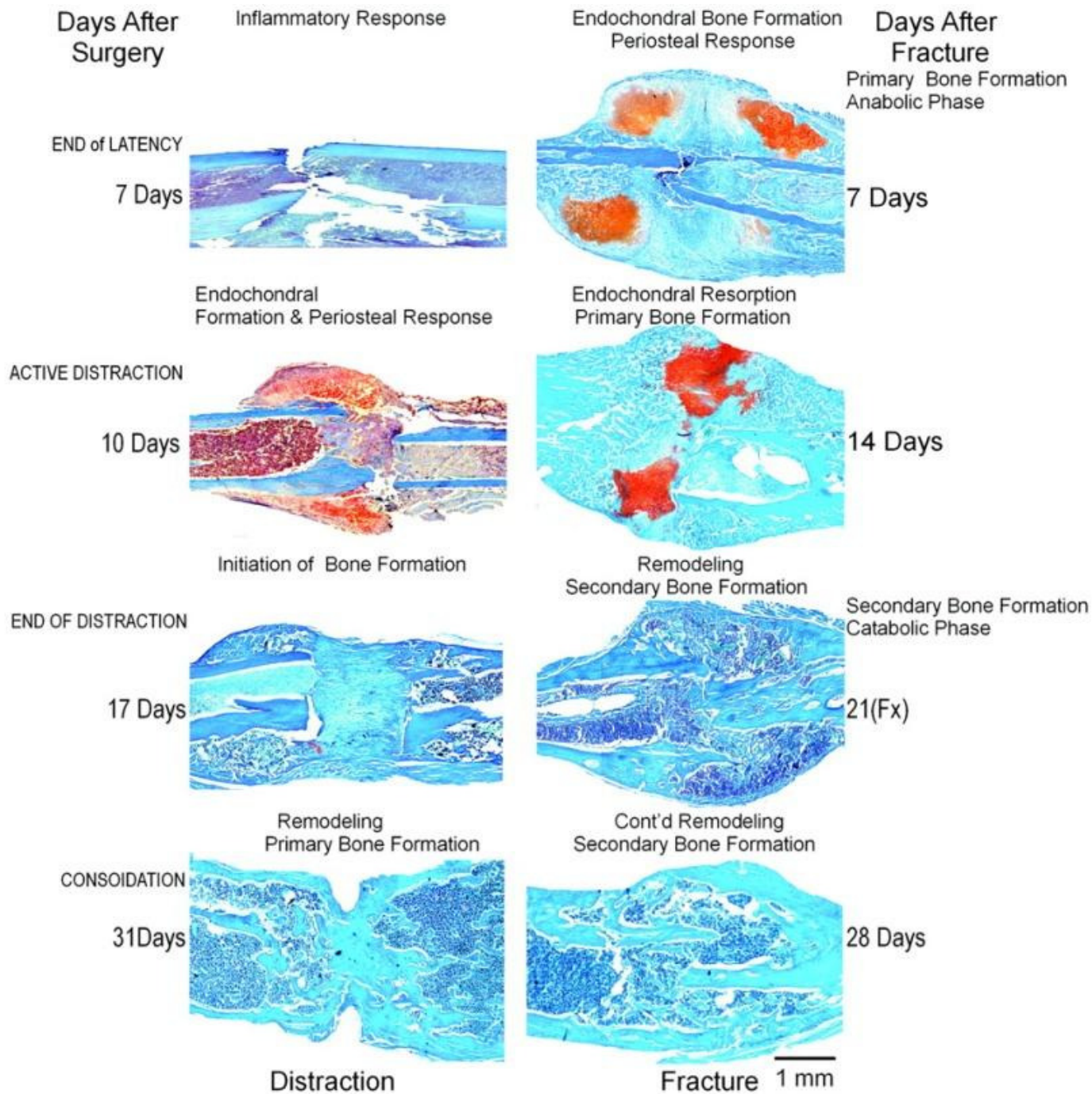


Figure 6. Histological aspect of distraction osteogenesis.

Acquired conditions

1. Post-traumatic growth disturbance of the mandible, for example mandibular hypoplasia due to TMJ ankylosis.
2. Non-union of fractures.
3. Atrophy of edentulous segments.

4. Oncologic mandibular osseous defects.

Miscellaneous

1. Rapid canine distraction.

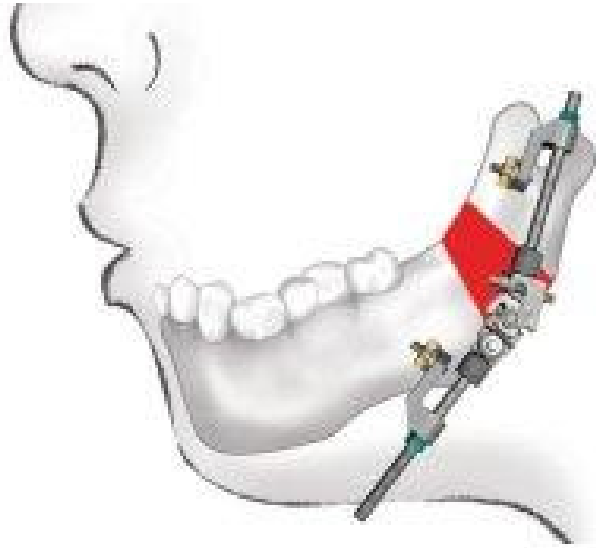


Figure 7. Intra-oral Zurich mandibular distractor (Product. Multivector distractor; <http://us.synthes>).

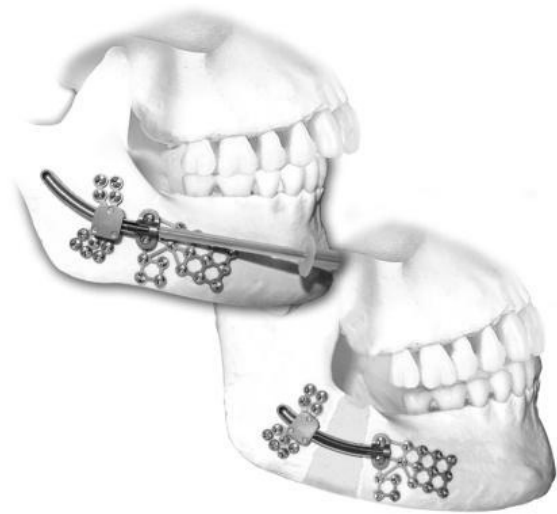

Figure 9. Mandibular distractor product. (Multivector mandibular distractor; <http://us.synthes>).



Figure 8. External midfacial distractor. (Product. External midface distractor; <http://us.synthes>).

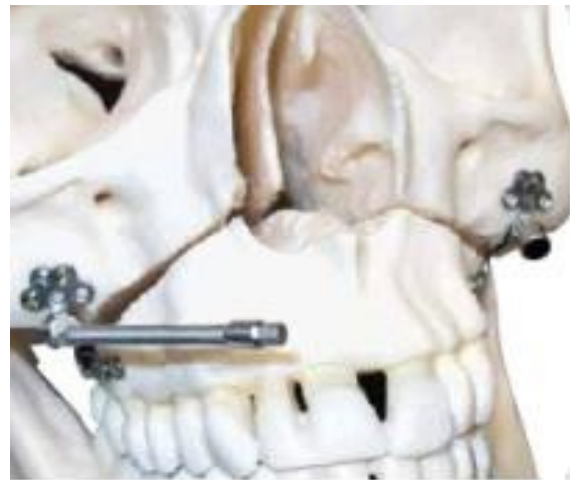

Figure 10. Midfacial distractor (multivector maxillary distractor <http://us.synthes>).

2. Distraction for ankylosed teeth.

Contraindications

Relative contraindications are:

- 1. Poor nutrition and lack of soft tissue.
- 2. Inadequate bone stock as in neonates.

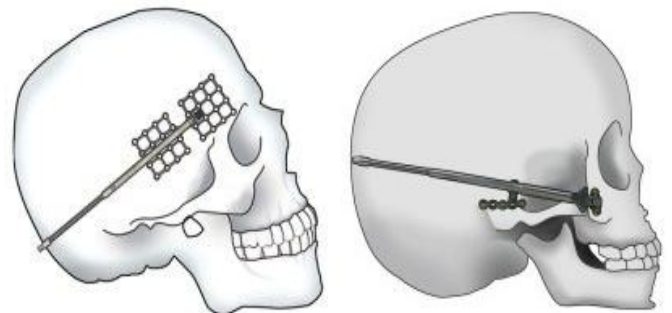


Figure 11. Modular internal distractor (cranial) (Product. Craniofacial Multivector distractor; <http://us.synthes>).

3. Geriatric patients due to increased number of mesenchymal stem cells.
4. Irradiated bone.
5. Osteoporotic bone.
6. Any systemic disease which affects bone metabolism.

Advantages of distraction osteogenesis over orthognathic surgery

1. The slow rate of bone formation allows histogenesis of the associated soft tissues and therefore less possibilities of relapse.
2. Shorter hospital stay.
3. Reduced postoperative pain and swelling.
4. Increased stability because soft tissues can adapt over longer period to the advanced maxillary /mandibular position (physiological remodeling).
5. Reduced inferior alveolar nerve dyaesthesia.
6. Reduced need for intermaxillary fixation.
7. Large maxillomandibular advancement is possible.
8. No bone graft is required unlike conventional orthognathic surgery thus eliminating donor site morbidity.
9. The new bone formed via distraction osteogenesis is more native.

Disadvantages

1. Multiple daily out patient visits may be required in some cases.
2. Poor 3D control on the segments with current distracters. The 3D distracters are being constantly modified for the desired results.
3. Manipulation of healing corticotomy daily or several times a day could give rise to pain.
4. Difficult plaque control.
5. Damage to TMJ due to incorrect vector orientation.

MANAGEMENT AND TREATMENT PLANNING PROTOCOLS

The following points should be considered while planning a case-

- i) Records- complete records (pre, mid and post).
- ii) Treatment planning sessions.
- iii) When planning mandibular advancement: nature and type of advancement must be considered:
 - a) Unilateral vs. bilateral.
 - b) Vertical vs. horizontal vs. oblique.
 - c) Site of distraction: corpus vs. ramus.
- iv) Maxillary advancement in hypoplasia: sagittal and

sagittal combined with transverse.

- v) Maxillary advancement in cleft lip and palate patients- velopharyngeal considerations/ speech considerations (AAO, 2000; Hanson et al., 1999; Hanson, 2001).

SURGICAL APPROACH

- i) Transoral approach is preferred in maxillofacial distraction.
- ii) Extraoral approach may be considered in special situations only.
- iii) Device positioning – the device is placed along the desired vector of distraction. Templates based on standardized radiographs or steriolithiographs models can be useful guide for device orientation and osteotomy.

Osteotomy

Care should be taken not to disturb underlying teeth, roots, and neurovascular bundle.

- a) For midface advancement, a high Le Fort 1 osteotomy is preferred. If transverse distraction is required a mid-palatal split is performed.
- b) Device fixation - monocortical screws are used for fixation.
- c) Initial/trail activation - the device is activated through 2 to 3 mm to verify the completion of osteotomy.
- d) Closure - a water tight closure of surgical site is required to minimize chances of salivary contamination and subsequent infection.

Distraction protocol

- i) Latency period recommended ranges from 5 to 10 days.
- ii) Distraction is generally carried out at the rate of 1.0 mm/24 h.
- iii) Surgeon and the orthodontist should monitor the patients progress clinically and radiologically.
- iv) Consolidation phase ranges from 8 to 14 weeks.

Successful management of craniofacial deformities with distraction osteogenesis involves a team approach among various specialties of dentistry.

CONCLUSION

The application of distraction osteogenesis offers a novel solution for surgical orthodontic management of developmental anomalies of the craniofacial skeleton. Osteodistraction provides a means whereby bone may be molded in to different shapes to more adequately address

the nature of skeletal deformities and asymmetries. As clinicians begin applying this new technique, they will quickly realize that there is learning curve associated with distraction osteogenesis to treat deformities of the head and neck.

REFERENCES

- Al-Aql ZS, Alagl AS, Graver DT, Gerstenfeld LC, Einhorn TA (2008). Molecular mechanisms controlling bone formation during fracture healing and distraction osteogenesis. *Dent. Res.*, 82(2): 107-118.
- Aldegheri R, Trivella G (1989). Epiphyseal distraction: Chondrodystasia. *Clin. Orthop.*, 241: 117.
- American Association of Orthodontists (2000). Distraction osteogenesis: A new frontier in correcting dentofacial deformities. In *News letter. Orthod. Dialogue*, 12(2).
- Aronson J, Good B, Stewart C (1990). Preliminary studies of mineralization during distraction osteogenesis. *Clin. Orthop.*, 250: 43-49.
- Aronson J, Shen XC, Suiner RA (1997). Rat model of distraction osteogenesis. *J. Orthop. Res.*, 5: 221-226.
- Codivilla, Alessandro (1905). On the means of lengthening in the lower limbs, the muscles, and the tissues which are shortened through deformity. *Am. J. Orthoped. Surg.*, 2: 353.
- De Bastiani G, Aldegheri R, Reuzia Brivio L, Trivilla G (1986). Limb lengthening by distraction of the epiphyseal plate: A comparison of two techniques in rabbit. *J. Bone Joint. Surg.*, 68(B): 545.
- De Pablos J Jr, Canadell J (1984). Distraction of the growth plate; Experiments in pigs and sheeps. *Acta Orthop. Scand.*, 55: 359.
- Dessner S, Radolsky Y, El-Bialy T, Evans CA (1999). Mandibular lengthening using advanced intraoral tooth-borne distraction devices. *J. Oral. Maxillofac. Surg.*, 57(11): 1318-1322.
- Dessner S, Radolsky Y, El-Bialy T (2001). Surgical and orthodontic considerations for distraction osteogenesis with ROD appliances. *Atlas Oral Maxillofac. Surg. North Am.*, 9: 111-139.
- Dale A Baur Fritz, Michael A, Sidman, James Db (2004). Distraction osteogenesis of the mandible. 12(6): 513-518.
- Figuora AA, Polley JW (1999). Management of severe cleft maxillary deficiency with distraction osteogenesis: Procedure and results. *Am. J. Orthod. Dentofac. Orthop.*, 115(1): 1-12.
- Guerrero CA, Bell WH, Contasti GI, Rodriguez AM (1997). Mandibular widening by intraoral distraction osteogenesis. *Br. J. Oral. Maxillofac. Surg.*, 35: 383-387.
- Hanson PR, Melugin MB (1999). Orthodontic management of patients undergoing mandibular distraction osteogenesis. *Semin. Orthod.*, 5(1): 25-34.
- Hanson PR (2001). Treatment planning and Orthodontic management of patients undergoing mandibular distraction osteogenesis. In Rudolph P, Dendill J, Stein D: *Craniofacial Distraction Osteogenesis* (1st edn). St. Louis, Mosby, pp. 156-167.
- Ilizarov GA (1989). The tension – Stress effect on the genesis and growth of tissues: Part II. The influence and rate of frequency of distraction. *Clin. Orthop.*, 239: 263-285.
- Kumuro Y, Taketo T, Harii K, Yonemara Y (1994). The histologic analysis of distraction osteogenesis of the mandible in rabbits. *Plast. Reconstr. Surg.*, 94: 152-159.
- McCarthy JG, Shreiber J, Karp N, Thorne CH, Grayson BH (1992). Lengthening the human mandible by gradual distraction. *Plast. Reconstr. Surg.*, 89(1): 1-8.
- Peltonen JI, Alitalo I, Karahaju EO, Helio H (1984). Distraction of the growth plate: Experiments in pigs and sheep. *Acta Orthop. Scand.*, 55: 359.
- Polley JW, Figueroa AA (1997). Management of severe maxillary deficiency in childhood and adolescence through distraction osteogenesis with an external, adjustable, rigid distraction device. *J. Craniofac. Surg.*, 8(3): 181-185.
- Product. Multivector distractor; <http://us.synthes.com/products/CMF>.
- Product. External midface distractor; <http://us.synthes.com/products/CMF>.
- Product. Craniomaxillofacial Multivector distractor; <http://us.synthes.com/products/CMF>.
- Roy CSK, Jayan B, Menon PS, Prasad BNBM, Ravishankar K (2007). Management of obstructive sleep apnoea and non-apneic snoring with maxilla-mandibular distraction osteogenesis. *Indian J. Sleep. Med.*, 2(3): 101-108.
- Rachmiel A, Jackson IT, Sugihara T, Clayman L, Topf JS, Forte RS (1993). Midface advancement by gradual distraction. *Br. J. Plast. Surg.*, 46(3): 201-207.
- Rachmiel A, Levy M, Laufer D (1995). Lengthening of the mandible by distraction osteogenesis: Report of cases. *J. Oral. Maxillofac. Surg.*, 53(7): 838-846.
- Rachmiel A, Levy M, Laufer D, Clayman L, Jackson IT (1996). Multiple segmental gradual distraction of facial skeleton: An experimental study. *Ann. Plast. Surg.*, 36(1): 52-59.
- Samchukov ML, Cope JB, Cheskashin AM (1999). Distraction osteogenesis interactive course on CD-ROM, Dallas, Texas, Global Med-Net.
- Samchukov ML, Cope JB, Cheskashin AM (1998). Distraction osteogenesis: History and biologic basis of new bone formation. In Lynch SE, Geneo RJ, Marx RE, editors: *Tissue engineering*. Quintessence Publishing. *Appl. Maxillofac. Surg. Periodontics*, Carol Stream, p. 111.
- Sledge CB, Noble J (1978). Experimental limb lengthening by epiphyseal distraction. *Clin. Orthop.*, 136: 111.
- Shah A. Distraction osteogenesis of maxilla. www.emedicine.com.
- Wangerin K (2000). Distraction in mouth, jaw and facial surgery. *Mund Keifer Gesichtschir*, 1: S226-236.