

Full Length Research Paper

Anti-ulcerogenic activity of *Typhonium flagelliforme* aqueous leaf extract against ethanol-induced gastric mucosal injury in rats

D. A. A. Bardi¹, M. A. Sarah Khan¹, S. Z. Sabri¹, F. A. Kadir^{2*}, A. A. Mahmood³, A. A. Zahra³, S. M. Suzy³, N. Al-Hanhana³ and A. Al-Magrami³

¹Institute of Biological Science, Faculty of Science, University of Malaya, Kuala Lumpur-Malaysia.

²Department of Anatomy, Faculty of Medicine, Cyberjaya University College of Medical Sciences, Selangor Daruls Ehsan, Malaysia.

³Department of Molecular Medicine, Faculty of Medicine, University of Malaya, Kuala Lumpur-Malaysia.

Accepted 30 May, 2011

Typhonium flagelliforme (Araceae) is an indigenous medicinal plant of Malaysia which is endowed with curative properties against a variety of illness including injuries, oedema, coughs, pulmonary ailments, bleeding and cancer. In this study, *T. flagelliforme* aqueous leaf extract was used to investigate its gastroprotective effect in adult Sprague Dawley rats which were divided into four groups. The rats were orally pre-treated with sterile distilled water (ulcer control groups), omeprazole 20 mg/kg (reference group), 250 and 500 mg/kg of *T. flagelliforme* (experimental groups) one hour before oral administration of absolute ethanol to generate gastric mucosal injury. After an additional hour, the rats were sacrificed and the ulcer areas of the gastric walls were determined. The ulcer control group exhibited severe mucosal injury, whereas groups pre-treated with *T. flagelliforme* extracts exhibited significant protection of gastric mucosal injury. These findings were also confirmed by histological studies. These results suggest that *T. flagelliforme* promotes ulcer protection as ascertained grossly by significant reduction of ulcer area and histology by comparatively decreases in ulcer areas, reduction or absence of edema and leucocytes infiltration of submucosal layer compared to ulcer control group.

Key words: *Typhonium flagelliforme*, rodent tuber, gastric ulcer, histology, aqueous extract.

INTRODUCTION

Gastric ulcer is an illness that affects a considerable number of people worldwide. The etiological factors of this disorder include: stress, smoking, nutritional deficiencies, infections, frequent and indiscriminate use of non-steroidal anti-inflammatory drugs (NSAIDs) (Khazaei and Salehi, 2006). The pathogenesis of gastroduodenal ulcers is influenced by various aggressive and defensive factors, such as mucus secretion, mucosal barrier, acid-pepsin secretion, blood flow, cellular regeneration and endogenous protective agents (Mizui et al., 1987). Although the introduction of proton-pump inhibitors to the classic anti-ulcer therapy had

revolutionized treatment of peptic ulcers and other gastrointestinal disorders, there is still no complete cure for this disease. It has been shown that long term use of these drugs may be associated with ineffectiveness of different drug regimens and even resistance to drugs are emerging (Al-Mofleh et al., 2007). Thus, there is an urgent need to identify more effective and safe anti-ulcer agents. A widespread search has been launched to identify new anti-ulcer therapies from natural sources. Herbs, medicinal plants, spices, vegetables and crude drug substances are considered to be a potential source to combat various diseases including gastric ulcer. In the scientific literature, a large number of medicinal plants with gastric anti-ulcer potential have been reported (Abdulla et al., 2010; Mahmood et al., 2010; Wasman et al., 2010) *Typhonium flagelliforme*, commonly known as rodent tuber (English) or keladi tikus (Malay), is a medicinal

*Corresponding author. E-mail: faalhadi@yahoo.com or farkaad@cybermed.edu.my. Tel: 03-83137159.

herb which belongs to the Araceae family. This plant is widely used in traditional medicine in Southeast Asia to treat various diseases. Being described ethnomedically as toxic, warming and phlegm resolving, this plant is used to soothe swelling, coughing and more predominantly for the treatment of cancer (Lee and Wong, 2004). Traditionally, *T. flagelliforme* is taken with fruit juice or as dry extract with other herbal medicine as an alternative therapy in Malaysia to treat various types of cancer (Lee and Wong, 2004). The flowers of *T. flagelliforme* have been used to arrest bleeding and as remedial for the treatment of injury (Perry and Metzger, 1980). *T. flagelliforme* has been used for treating internal injuries and edema. The rhizomes of the plant have traditionally been used as expectorant for coughs and as treatment for other pulmonary ailments. It is also antiasthmatic, anti-inflammatory, analgesic and sedative (Zhong et al., 2001). As a general practice, the juice of the fresh whole *T. flagelliforme* plant is prepared in honey to be consumed as a drink (Teo and Chang, 1996). There are also other practices where the leaves are wrapped in Longan flesh and taken raw (Lee and Wong, 2004). *T. flagelliforme* is used to soothe the stomach, combat nausea and vomiting, and reduce epigastric and abdominal distention. In addition, this plant relieves pain, inflammation and relaxes spasms, and is also used for lymphatic swellings and has significant antihepatotoxic activity (Sampson et al., 2000; Huang et al., 2004). Pharmacological studies conducted on rats also indicated that the juice extract was able to prevent hepatocarcinogenesis (Choon et al., 2008). *T. flagelliforme* appears to be a promising plant demonstrating antibacterial and antioxidant activity (Mohan et al., 2008). This plant has been used extensively as one of the components of traditional herb for combating breast, lung, colon and liver cancer (Teo and Chang, 1996). Thus far, there is no data available regarding gastroprotective activity from *T. flagelliforme* leaf extracts. The present study was undertaken in rats to evaluate for anti-ulcerogenic properties of aqueous leaf extract of *T. flagelliforme* in rats.

MATERIALS AND METHODS

Omeprazole

In this study, omeprazole was used as the reference anti-ulcer drug, and was obtained from the University Malaya Medical Centre (UMMC) Pharmacy. The drug was dissolved in carboxymethyl cellulose (CMC) and administered orally to the rats in concentrations of 20 mg/kg body weight (5 ml/kg) according to the recommendation of Mahmood et al., (2010).

Plant specimen and preparation of extraction

Fresh leaves of *T. flagelliforme* were obtained from Ethno Resources Sdn Bhd, Selangor Malaysia, and identified by

comparison with the Voucher specimen deposited at the Herbarium of Rimba Ilmu, Institute of Science Biology, University of Malaya, Kuala Lumpur. The dried leaves were powdered using electrical blender. Hundred grams of the fine powder were soaked in 500 ml of 95% ethanol in conical flask for 3 days. After 3 days the mixture was filtered using a fine muslin cloth followed by filter paper (Whatman No. 1) and distilled under reduced pressure in an Eyela rotary evaporator (Sigma-Aldrich, USA). The dry extract was then dissolved in sterile distilled water and administered orally to rats in concentrations of 250 and 500 mg/kg body weight (5 ml/kg body weight) according to the recommendation of (Wasman et al., 2010).

Acute toxicity studies

The acute toxic study was used to determine a safe dose for *T. flagelliforme* leaf extract. Thirty six healthy Sprague Dawley rats (18 males and 18 females) were obtained from the Experimental Animal House, Faculty of Medicine, University of Malaya, and were assigned equally into 3 groups labeled as vehicle (sterile distilled water); 2 and 5 g/kg of *T. flagelliforme* in vehicle, respectively (Abdulla et al., 2010). The animals were fasted overnight (food but not water) prior dosing. Food was withheld for a further 3 to 4 h after dosing. The animals were observed for 30 min and 2, 4, 24 and 48 h after the administration for the onset of clinical or toxicological symptoms. Mortality, if any was observed over a period of two weeks. The animals were sacrificed on the 15th day. Serum biochemical and histological (liver and kidney) parameters were determined following standard methods (Mahmood et al., 2010; Wasman et al., 2010). The study was approved by the ethics committee for animal experimentation, Faculty of Medicine, University of Malaya, Malaysia and the Ethic No. PM/07/05/2009/MMA (a) (R). Throughout the experiments, all animals received human care according to the criteria outlined in the "Guide for the Care and Use of laboratory Animals" prepared by the National Academy of Sciences and published by the national Institute of health.

Experimental animals for gastric ulcer

Sprague Dawley healthy adult male rats were obtained from the Experimental Animal House, Faculty of Medicine, University of Malaya, and Ethic No. PM/27/07/2010/MAA (R). The rats were divided randomly into 4 groups of 6 rats each. Each rat that weighed between 200 to 225 g was placed individually in a separate cage (one rat per cage) with wide-mesh wire bottoms to prevent coprophagia during the experiment. The animals were maintained on standard pellet diet and tap water. The study was approved by the Ethics Committee for Animal Experimentation, Faculty of Medicine, University of Malaya, Malaysia. Throughout the experiments, all animals received human care according to the criteria outlined in the "Guide for the Care and Use of laboratory Animals" prepared by the National Academy of Sciences and published by the national Institute of health.

Gastric ulcer-induction by ethanol

The rats fasted for 48 h before the experiment according to the recommendation of (Mahmood et al., 2010), but were allowed free access to drinking water up till 2 h before the experiment. Gastric ulcer was induced by orogastric intubation of absolute ethanol (5 ml/kg) according to the method described by Abdulla et al. (2010). Ulcer control groups were orally administered vehicle (sterile distilled water, 5 ml/kg). The reference group received oral doses

Table 1. Acute toxicity study of renal function tests.

Animals Group	Renal function tests						
	Sodium (mmol/L)	Pottasium (mmol/L)	Chloride (mmol/L)	CO ₂ (mmol/L)	Anion gap (mmol/L)	Urea (mmol/L)	Creatinine (μmol/L)
Normal control	137.68 ± 0.1	5.27 ± 0.08	102.6 ± 0.23	23.28 ± 0.16	18.74 ± 0.08	5.67 ± 0.21	50.42 ± 0.2
L. D (2 g/kg)	137.92 ± 0.06	5.16 ± 0.07	102.75 ± 0.08	22.83 ± 0.31	19.13 ± 0.61	45.7 ± 0.12	49.25 ± 0.63
H. D (5 g/kg)	137.93 ± 0.15	5.18 ± 0.14	102.65 ± 0.12	22.78 ± 0.2988	18.86 ± 0.3	5.4 ± 0.21	49.62 ± 0.15

All values expressed as mean and standards error mean. There is no significant differences between groups ($p < 0.05$).

of 20 mg/kg omeprazole in sterile distilled water (5 ml/kg) as positive control. Experimental groups were orally administered of *T. flagelliforme* aqueous leaf extract in sterile distilled water (5 ml/kg) at doses of 250 and 500 mg/kg. One hour after this pre-treatment all groups of rats were administered orally with absolute ethanol (5 ml/kg) in order to induce gastric ulcers. The rats were euthanized 60 min later (Wasman et al., 2010) under an overdose of xylazine and ketamine anesthesia and their stomachs were immediately excised.

Gross gastric lesions evaluation

Ulcers of the gastric mucosa appear as elongated bands of hemorrhagic lesions parallel to the long axis of the stomach. Gastric mucosa of each rat was thus examined for damage. The length and width of the ulcer (mm) were measured by a planimeter ($10 \times 10 \text{ mm}^2 = \text{ulcer area}$) under dissecting microscope (1.8x). The ulcerated area was measured by counting the number of small squares, $2 \text{ mm} \times 2 \text{ mm}$, covering the length and width of each ulcer band. The sum of the areas of all lesions for each stomach was applied in the calculation of the ulcer area (UA) where in the sum of small squares $\times 4 \times 1.8 = \text{UA (mm}^2\text{)}$ according to the recommendation of Mahmood et al., (2010). The inhibition percentage (1.0%) was calculated by the following formula according to the recommendation of Mahmood et al., (2010).

$$(\%) = [(UA_{\text{control}} - UA_{\text{treated}}) \div UA_{\text{control}}] \times 100\%.$$

Histological evaluation of gastric lesions

Specimens of the gastric walls of each rat were fixed in 10% buffered formalin and processed in a paraffin tissue processing machine. Sections of the stomach were made at a thickness of 5 μm and stained with Hematoxyline and eosin for histological evaluation.

Statistical analysis

All values were reported as mean ± S.E.M. The statistical significance of differences between groups was assessed using one-way ANOVA. A value of $p < 0.05$ was considered significant.

RESULTS

Acute toxicity

Acute toxicity study is a study in which the animals were treated with the *T. flagelliforme* leaf extract at a dose of 2

and 5 g/kg were kept under observation for 14 days. All the animals remained alive and did not manifest any significant visible of toxicity at these doses. Thus, clinical observations, serum biochemistry, and histopathology data did not show any significant differences between control and treated groups (Table 1 and 2). We conclude that *T. flagelliforme* leaf extract orally administered to rats was safe and that no drug-related toxicity was detected even at the highest dose investigated.

Gross evaluation of gastric lesions

The anti-ulcer activity of *T. flagelliforme* aqueous leaf extract in ethanol-induced gastric lesion model is shown in Table 3. Results showed that rats pre-treated with *T. flagelliforme* extracts before being given absolute alcohol had significantly reduced areas of gastric ulcer formation compared to rats pre-treated with only sterile distilled water (ulcer control group) (Figure 1). Absolute ethanol produced extensive visible hemorrhagic lesions of gastric mucosa. Moreover, the *T. flagelliforme* extract significantly suppressed the formation of the ulcers and it was interesting to note the flattening of gastric mucosal folds in rats pretreated with extract (500 mg/kg). It was also observed that protection of gastric mucosa was most prominent in rats pre-treated with 500 mg/kg leaf extract (Table 3). Furthermore, ethanol-induced mucosal damage was significantly reduced in the size and severity by pretreatment of the animals with *T. flagelliforme* extract. The significant inhibition of gastric ulcer in rats pretreatment with *T. flagelliforme* extract (250 mg/kg) was comparable with omeprazole which is a standard drug used for curing gastric ulcer (Table 3 and Figure 1).

Histological evaluation of gastric lesions

Histological observation of ethanol induced gastric lesions in ulcer control group pre-treated with sterile distilled water only, showed comparatively extensive damage to the gastric mucosa and necrotic lesions penetrate deeply into mucosa, and extensive oedema and leucocytes infiltration of the submucosal layer are present (Figure 2). Rats that received pre-treatment with

Table 2. Acute toxicity study for liver function tests.

Animals group	Liver Function tests								
	Total protein (g/L)	Albumin (g/L)	Globulin (g/L)	Total bilirubin ($\mu\text{mol/L}$)	Conjugated bilirubin ($\mu\text{mol/L}$)	AP (IU/L)	A (IU/L)	AST (IU/L)	G-glutamyl. transferase (IU/L)
Normal control	71.65 \pm 0.21	11.53 \pm 0.09	60.25 \pm 0.28	2.02 \pm 0.02	0.93 \pm 0.04	133.25 \pm 0.17	51.8 \pm 0.42	151.33 \pm 0.31	4.78 \pm 0.12
L.D (2 g/kg)	71.41 \pm 0.14	11.23 \pm 0.16	59.60 \pm 0.28	1.99 \pm 0.02	0.99 \pm 0.02	134.00 \pm 0.58	52.67 \pm 0.36	152.92 \pm 1.44	4.98 \pm 0.12
H D (5 g/kg)	71.27 \pm 0.23	11.18 \pm 0.09	59.53 \pm 0.18	1.98 \pm 0.01	0.97 \pm 0.02	134.58 \pm 0.33	52.25 \pm 0.21	153.42 \pm 1.21	5.08 \pm 0.14

All values expressed as mean and standards error mean. There is no significant differences between groups ($p < 0.05$).

Table 3. Observed ulcer area and inhibition percentage in rats.

Animal Group	Treatment (5 ml kg^{-1} dose)	Ulcer area (mm^2) (Mean \pm S.E.M)	Inhibition (%)
1	Distilled water Control)	865.00 \pm 2.89 ^a	-
2	Omeprazole (20)	115.50 \pm 1.48 ^b	86.65
3	<i>T. flagelliforme</i> (250)	109.17 \pm 3.00 ^b	87.38
4	<i>T. flagelliforme</i> (500)	0.00 \pm 0.00 ^c	100

All values are expressed as mean \pm standard error mean. Means with different superscripts are significantly different ($p < 0.05$ are significant).

T. flagelliforme extract had comparatively better protection of the gastric mucosa as seen by reduction or absent of ulcer area, reduced or absent of submucosal edema and leucocytes infiltration (Figure 2). The *T. flagelliforme* extract has been shown to exert the cytoprotective effects in a dose-dependent manner.

DISCUSSION

Peptic ulcers are caused when the natural balances between the aggressive factors of acid and pepsin and defensive mechanisms of mucus, bicarbonate, mucosal turnover and blood supply

(mucosal barrier) are disturbed (Piper and Stiel, 1986). Baron et al. (1980) have suggested that acid and pepsin are relatively less important as causative agents and that a defect in the defensive mechanism of gastric mucosa is the first step toward ulcer formation. Although in most cases the etiology of ulcer is unknown, it is generally accepted that it is the result of an imbalance between aggressive factors and maintenance of the mucosal integrity through the endogenous defense mechanism (Piper and Stiel, 1986). Omeprazole is a proton pump inhibitor which has been widely used as an acid inhibitor agent for the treatment of disorders related to gastric acid secretion for about 15 years (Li et al.,

2004). Omeprazole has substituted benzimidazoles; it inhibits acid secretion by acting on the hydrogen-potassium exchanger (H^+ , K^+ -ATPase) for the apical plasma membrane of the gastric mucosa (Sato et al., 1989). Omeprazole is highly selective for the proton pump and undergoes catalyzed conversion into active form within the acid forming space. The active inhibitors react with SH (thiol) group of the proton pump, resulting in inhibition of acid formation (Nagaya et al., 1991). It is known that gastric lesions produced by ethanol administration appear as multiple- hemorrhagic red bands of different sizes along the glandular stomach. Ethanol is commonly used for inducing ulcer n

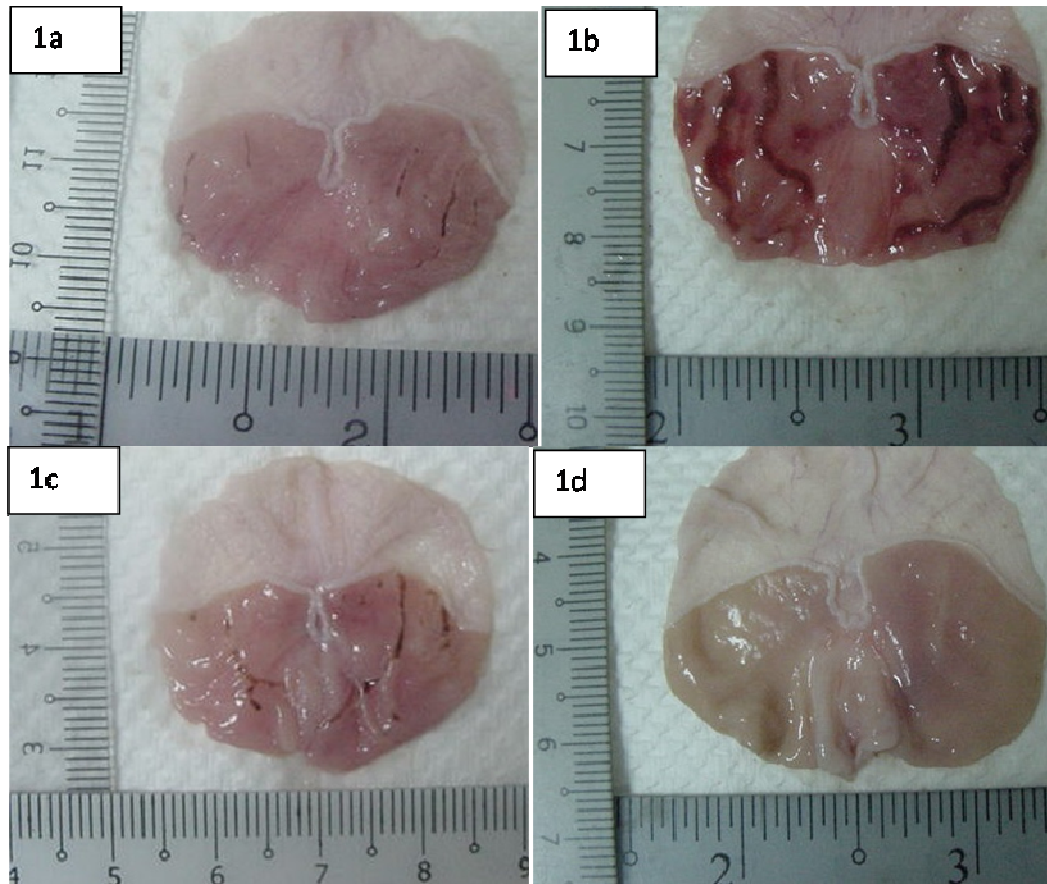


Figure 1. Gross appearance of the gastric mucosa in rats. (1a) Rats pre-treated with 5 ml/kg sterile distilled water (ulcer control). Severe injuries are seen in the gastric mucosa. Absolute ethanol produced extensive visible hemorrhagic necrosis of gastric mucosa. (1b) Rats pre-treated with omeprazole (20 mg/kg). Injuries to the gastric mucosa are very milder compared to the injuries seen in the ulcer control rats. (1c). Rat pre-treated with *T. flagelliforme* extract (250 mg/kg). Mild injuries are seen in the gastric mucosa. The extract reduces the formation of gastric lesions induced by absolute ethanol. (1d) Rats pre-treated with 500 mg/kg of *T. flagelliforme* extract. No injuries to the gastric mucosa are seen instead flattening of gastric mucosa is seen.

experimental rats, it leads to intense gastric mucosal damage. Studies suggest that the ethanol-induced damage to the gastrointestinal mucosa starts with microvascular injury, namely disruption of the vascular endothelium resulting in increased vascular permeability, edema formation and epithelial lifting (Szabo et al., 1995). Ethanol produces necrotic lesions in the gastric mucosa by its direct toxic effect, reducing the secretion of bicarbonates and production of mucus (Marhuenda et al., 1993). Exposure to ethanol increases the extension of cellular damage in a dose-dependent way (Mutoh et al., 1990). Oxidative stress plays important role in the pathogenesis of various diseases including gastric ulcer, with antioxidants being reported to play a significant role in protection of gastric mucosa against various necrotic agents (Trivedi and Rawal, 2001). Antioxidants could help to protect cells from damage caused by oxidative

stress and enhanced the body's defense systems against degenerative diseases. Administration of antioxidants inhibits ethanol-induced gastric injury in rat (Ligumsky et al., 1995) and *T. flagelliforme* extracts have been shown to contain antioxidants (Mohan et al., 2008) and it is likely that gastroprotective exerted by *T. flagelliforme* leaf extract could be attributed to its antioxidant property. In addition, *T. flagelliforme* leaf extracts are reported to contain alkaloids and flavonoids (Nobakht et al., 2010) and it could be conceivable that the anti-ulcer activity of *T. flagelliforme* leaf extract could be linked to the flavonoids since flavonoids are reported to protect the mucosa by preventing the formation of lesions by various necrotic agents (Saurez et al., 1996). The result of the present study also revealed protection of gastric mucosa and inhibition of leucocytes infiltration of gastric wall in rats pretreated with *T. flagelliforme* extract. Similarly, Abdulla

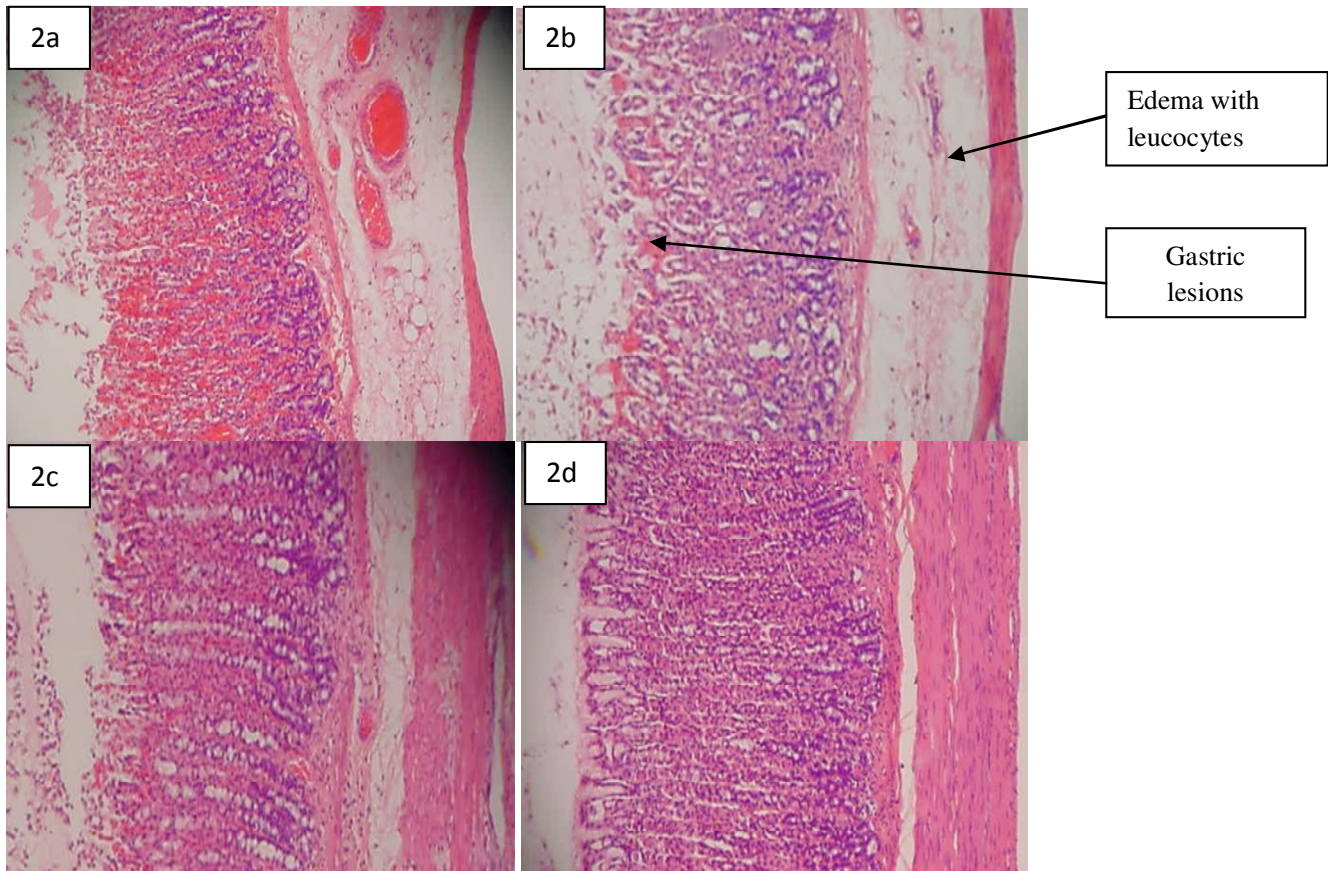


Figure 2. Histological study of the absolute ethanol-induced gastric mucosal damage in rats. (2a) Rats pre-treated with 5 ml/kg of sterile distilled water (ulcer control). There is severe disruption to the surface epithelium and necrotic lesions penetrate deeply into mucosa and extensive edema of submucosa layer and leucocyte infiltration are present. (2b) Rats pre-treated with omeprazole (20 mg/kg). Mild disruption of the surface epithelium mucosa is present but deep mucosal damage is absent. There is edema and leucocytes infiltration of the submucosal layer. (2c) Rat pre-treated with *T. flagelliforme* extract (250 mg/kg). Mild disruption of surface epithelium are present but deep mucosal damage is absent. Reduction of submucosal edema and leucocytes infiltration. (2d) Rats pre-treated with *T. flagelliforme* extract (500 mg/kg). There is no disruption to the surface epithelium with no edema and no leucocytes infiltration of the submucosal layer (H and E stain 10x).

et al. (2010) demonstrated that the reduction of neutrophil infiltration into ulcerated gastric tissue promotes the healing of gastric ulcers in rats. Wasman et al., (2010) showed that oral administration of plant extract before ethanol administration significantly decreased neutrophil infiltration of gastric mucosa and Fujita et al. (1998) observed that an increase in neutrophil infiltration into ulcerated gastric tissue delayed the healing of gastric ulcers in rats. Absolute alcohol would extensively damage the gastric mucosa leading to increased neutrophil infiltration into the gastric mucosa. Oxygen free radicals derived from infiltrated neutrophils in ulcerated gastric tissues have inhibitory effect on gastric ulcers healing in rats (Suzuki et al., 1998). Neutrophils mediate lipid peroxidation through the production of superoxide anions (Zimmerman et al., 1997). Neutrophils are a major source of inflammatory mediators and can release potent reactive oxygen species such as superoxide, hydrogen

peroxide and myeloperoxidase derived oxidants. These reactive oxygen species are highly cytotoxic and can induce tissue damage (Cheng and Koo, 2000). Furthermore, neutrophil accumulation in gastric mucosa has been shown to induce microcirculatory abnormalities (Abdulla et al., 2010; Bou-Abboud et al., 1988). Suppression of neutrophil infiltration during inflammation was found to enhance gastric ulcer healing (Tsukimi et al., 1996). *T. flagelliforme* extract have been shown to contain anti-inflammatory activity (Zhong et al., 2001) and it is speculated that the gastroprotective effect exerted by this plant extract could be attributed to its anti-inflammatory activity. This anti-inflammatory activity could also be a key factor in the prevention of gastric ulcer as reported by Swarnakar et al., (2005). In the present study, we observed flattening of the mucosal folds which suggests that gastroprotective effect of *T. flagelliforme* leaf extract might be due to a decrease in gastric motility.

It is reported that the changes in the gastric motility may play a role in the development and prevention of experimental gastric lesions (Takeuchi et al., 1987; Abdulla et al., 2010). Relaxation of circular muscles may protect the gastric mucosa through flattening of the folds. This will increase the mucosal area exposed to necrotizing agents and reduce the volume of the gastric irritants on rugal crest (Abdulla et al., 2010; Wasman et al., 2010). Ethanol produces a marked contraction of the circular muscles of rat fundic strip. Such a contraction can lead to mucosal compression at the site of the greatest mechanical stress, at the crests of mucosal folds leading to necrosis and ulceration (Mahmood et al., 2010; Mersereau and Hinchey, 1982).

Conclusion

Our study reveals that *T. flagelliforme* leaf extract could significantly protect gastric mucosa against ethanol-induced gastric mucosal injury. Such protection was shown as ascertain by reduction of ulcer area of gastric wall and reduction or inhibition of edema and leucocytes infiltration of submucosal layers, and protection was most prominent at a dose of 500 mg/kg leaf extract. The data obtained confirm the traditional indications for this herb and present a new therapeutic option for the treatment of gastric ailments. The exact mechanism (s) underlying this anti-ulcerogenic effect remain unknown, but it seems that this extract contains pharmacologically active substances with potent antioxidant and anti-inflammatory activity.

ACKNOWLEDGEMENTS

The authors express gratitude to the staff of the Faculty of Medicine Animal House for the care and supply of rats, and to the University of Malaya for the financial support UMRG (RG102/09HTM).

REFERENCES

- Abdulla MA, Ahmed KAA, Al-Bayaty FH, Masood Y (2010). Gastroprotective effect of *Phyllanthus niruri* leaf extract against ethanol-induced gastric mucosal injury in rats. *Afri. J. Pharmacy Pharmacol.*, 4(5): 226-230.
- Al-Mofleh IA, Alhaider AA, Mossa JS, Al-Soohaibani MO, Rafatullah S (2007). Aqueous suspension of anise *Pimpinella anisum* protects rats against chemically induced gastric ulcers. *World J. Gastroenterol.*, 13: 1112-1118.
- Baron TH, Langman MTS, Wastell C (1980). Stomach and duodenum. In: I.A.D/Bouchier (Ed.), *Recent Advances in Gastroenterology*, Churehill Livingstone: London, pp. 23-29.
- Bou-Abboud CF, Wayland H, Panlsen G, Guth PH (1988). Microcirculatory stasis precedes tissue necrosis in ethanol-induced gastric mucosal injury in rat. *Dig. Dis. Sci.*, 33: 872-877.
- Cheng CL, Koo MWL. (2000). Effect of *Centella asiatica* on ethanol induced gastric mucosal lesions in rats. *Life Sci.*, 67: 2647-2653.
- Choon SL, Rosemal HMH, Nair NK, Majid MIA, Mansor SM, Navaratnam V (2008). *T. flagelliforme* inhibits cancer cell growth *in vitro* and induces apoptosis: An evaluation by the bioactivity guided approach. *J. Ethnopharmacol.*, 118: 14-20.
- Fujita H, Takahashi S, Okabe S (1998). Mechanism by which indomethacin delays the healing of acetic acid-induced ulcers in rats. Role of neutrophil anti-chemotactic and chemotactic activities. *J. Physiol. Pharmacol.*, 49: 71-82.
- Huang P, Karagianis G, Waterman PG (2004). Chemical constituents from *T. flagelliforme*. *Zhongyaocai*, 27: 173-175.
- Khazaei M, Salehi H (2006). Protective effect of *Falcaria vulgaris* extract on ethanol induced gastric ulcer in rats. *Iran J. pharmacol. Ther.*, 5: 43-46.
- Lee CY, Wong YS (2004). *The Illustrated Medicinal Plants of Malaysia*, vol. II. PK Herbal Research Centre, Kuala Lumpur Malaysia, pp. 65.
- Li X, Andersson TB, Ahlstrom M, Weidolf L (2004). Comparison of inhibitory effects of proton pump inhibiting drugs omeprazole, esomeprazole, lansoprazole, pantoprazole and rabeprazole on human cytochrome P450 activities. *Drug Metab. Dispos.*, 32: 821-827.
- Ligumsky M, Sestieri M, Okon F, Ginsburg I (1995). Antioxidants inhibit ethanol-induced gastric injury in the rat. Role of manganese, glycine and carotene. *Scand. J. Gastroenterol.*, 30: 854-860.
- Mahmood AA, Mariod AA, Al-Bayaty F, Abdel-Wahab SI (2010). Anti-ulcerogenic activity of *Gynura procumbens* leaf extract against experimentally-induced gastric lesions in rats. *J. Med. Plants Res.*, 4(8): 685-691.
- Marhuenda E, Martin MJ, Alarcon de la Lastra C (1993). Antiulcerogenic activity of aescine in different experimental models. *Phytother. Res.*, 7: 13-16.
- Mersereau AW, Hinchey EJ (1982). Role of gastric mucosal folds in formation of focal ulcer in rats. *Surgery*, 91: 150-155.
- Mizui T, Sato H, Hirose F, Doteuchi M (1987). Effect of antiperoxidative drugs on gastric damage induced by ethanol in rats. *Life Sci.*, 41: 755-763.
- Mohan S, Bustamam A, Ibrahim S, Al-Zubairi AS, Elhassan MM, Yousif M (2008). Antibacterial and Antioxidant Activities of *Typhonium Flagelliforme* (Lodd.) Blume Tuber. *Am. J. Biochem. Biotechnol.*, 4(4): 402-407.
- Mutoh H, Hiraishi H, Ota S, Ivey KJ, Terano A, Sugimoto T (1990). Role of oxygen radicals in ethanol-induced damage to cultured gastric mucosal cells. *Am. J. Physiol.*, 258: G603-G609.
- Nagaya H, Inatomi N, Ohara A, Satoh H (1991). Effects of the enantiomers of lansoprazole (AG-1749) on H⁺/K⁺-ATPase activity in canine gastric microsomes and acid formation in isolated canine parietal cells. *Biochem. Pharmacol.* 42: 1875-1878.
- Nobakht GM, Kadir MA, Stanslas J (2010). Analysis of preliminary phytochemical screening of *Typhonium flagelliforme*. *Afr. J. Biotechnol.*, 9 (11): 1655-1657.
- Perry MP, Metzger J (1980). *Medicinal plants of East and Southeast Asia*. Cambridge, Massachusetts, USA: MIT Press, 24: 393-436.
- Piper DW, Stiel D (1986). Pathogenesis of chronic peptic ulcer, current thinking and clinical implications. *Medical Progress*, 2: 7-10.
- Sampson JH, Phillipson JD, Bowery NG, O'Neill MJ, Houston JG, Lewis JA (2000). Ethnomedicinally selected plants as sources of potential analgesic compounds: indication of *in vitro* biological activity in receptor binding assays. *Phytother Res.*, 14(1):24-29.
- Satoh H, Inatomi N, Nagaya H, Ianda I, Nohara A, Nakamura H (1989). Antisecretory and antiulcer activities of novel proton pump inhibitor AG-1749 in dogs and rats. *J. Pharmacol. Exp. Ther.*, 248: 806-815.
- Saurez J, Herreta MD, Marhuenda E (1996). Hesperidine and neohesperidine dihydrochalcone on different experimental models of induced gastric ulcer. *Phytother. Res.*, 10: 616-618.
- Suzuki Y, Ishihara M, Ito M (1998). Anti-ulcer effects of antioxidants, quercetin, α -tocopherol, nifedipine and tetracycline in rats. *Jap. J. Pharmacol.*, 78: 435-441.
- Swarnakar S, Ganguly K, Kundu P, Banerjee A, Maity P, Sharma AV (2005). Curcumin regulates expression and activity of matrix metalloproteinases 9 and 2 during prevention and healing of indomethacin-induced gastric ulcer. *J. Biol. Chem.*, 280: 9409-9415.
- Szabo S, Kusstatscher S, Sakoulas G, Sandor Z, Vincze A, Jadus M (1995). Growth factors: New endogeneous drug for ulcer healing. *Scand. J. Gastroenterol.*, 210: 15-18.

- Takeuchi K, Nishiwakki K, Okabe S (1987). Effect of dopamine on gastric mucosal lesion induced by ethanol in rats—possible involvement of antigastric motor activity mediated with alpha 2 adrenoreceptors. *Dig. Dis. Sci.*, 31: 1100-1107.
- Teo CKH, Chang BL (1996). *Cancer: Yet they live*. Malaysia: Eramaps Sdn.Bhd, pp. 53-70.
- Trivedi NP, Rawal UM (2001). Hepatoprotective and antioxidant property of *A. paniculata* Nees in BHC induced liver damage in mice. *Indian J. Exp. Biol.*, 39: 41-46.
- Tsukimi Y, Nozue C, Okabe S (1996). Effects of teminoprazole, omeprazole and sucralfate on indomethacin-induced delayed healing of kissing gastric ulcers in rats. *J. Gastroenterol. Hepatol.*, 11: 335-340.
- Wasman SQ, Mahmood AA, Salehuddin H, Zahra AA, Salmah I (2010). Cytoprotective activities of *Polygonum minus* aqueous leaf extract on ethanol-induced gastric ulcer in rats. *J. Med. Plants Res.*, 4(24): 2658-2665.
- Zhong Z, Zhou G, Chen X, Huang P (2001). Pharmacological study on the extracts from *T. flagelliforme*. *J. Chinese Med. Mater.*, 24: 735-738.
- Zimmerman JJ, Ciesielski W, Lewandoski J (1997). Neutrophil-mediated phospholipids peroxidation assessed by gas chromatography-mass spectroscopy. *Am. J. Physiol.*, 273: 653-661.